



ISSN (E): 2277-7695  
ISSN (P): 2349-8242  
NAAS Rating: 5.23  
TPI 2023; SP-12(7): 2355-2358  
© 2023 TPI

[www.thepharmajournal.com](http://www.thepharmajournal.com)

Received: 12-04-2023

Accepted: 15-05-2023

**Seema Kumari Bishnoi**

Ph.D. Scholar, Department of  
veterinary pathology CVAS,  
Bikaner, Rajasthan, India

**Jay K Desai**

Ph.D. Scholar, Department of  
veterinary pathology CVAS,  
Bikaner, Rajasthan, India

**Manisha Mathur**

Professor and Head, Department  
of veterinary pathology CVAS,  
Bikaner, Rajasthan, India

**S Dariya**

Ph.D. Scholar, Department of  
veterinary pathology PGIVER,  
Jaipur, Rajasthan, India

## Micromorphological study of degenerative changes in liver of goat

**Seema Kumari Bishnoi, Jay K Desai, Manisha Mathur and S Dariya**

### Abstract

The present investigation a total number of 1248 samples of liver of goat examined in Bikaner. Out of these 1248 specimens, 216 samples of liver suspected of abnormalities were further processed for histopathological examination. Out of 216 sample degenerative changes were present in 39 (18.03%) samples, cloudy swelling present in 11 (5.09%) samples, vacuolar degeneration present in 16 (7.4%) samples and fatty changes present in 12 (5.55%) samples. In cloudy swelling liver pale, friable and enlarged with round edges. hepatic cells were swollen, opaque and cytoplasm showed fine granulation and decrease sinusoidal spaces. When vacuoles are present in affected cell vacuolar degeneration of liver cell occur. In fatty liver fat accumulate mostly in centrilobular zone of hepatic tissue. Due to fatty changes in liver leads to increase size, pale appearance, and greasy texture at the time of cutting droplet of fat visible at cut side of blade. Hepatocytes were found swollen and numerous small fat vacuoles with nucleus pushed toward periphery.

**Keywords:** Degeneration, liver, occurrence, goat

### Introduction

Goat are susceptible to various infectious and non-infectious disease that lead to drop in production (Prasad, 2009) [6]. Liver is the first organ of the body to undergo pathological changes whenever an animal suffers from any disease and is the last organ to recover normally. Cell swelling occur in acute cell injury during early changes in liver cell, it may be simply disappeared during repair the cell and sometime drastic irreparable change in cell. Hypertrophy of cell organelles interferes normal homeostatic mechanism. When vacuoles are present in affected cell vacuolar degeneration occur in liver cell. Fatty liver disease worse with time early-stage liver swollen and damage tissue, due to damage tissue of liver scar formation. Extensive scar tissue replaces healthy tissue and severe damage of liver.

### Material and methods

The study was conducting time period between January 2020 to December 2020. For the proposed investigation, tissue sample of goat liver are collected from slaughter houses of Bikaner and nearby areas of Bikaner district. The tissue specimens were also collected from the carcasses of goat submitted to the department of Veterinary Pathology, CVAS, Bikaner for post mortem examination. Immediately after collection of samples all the samples were preserved in 10% formalin after cutting the affected parts.

### Processing of tissues

All the tissue samples sized at 1cm x 0.5 cm were trimmed properly and fixed for 24 hours or more. To remove the fixative, the tissues were kept in running tap water for overnight. The tissues were dehydrated in ascending grades of alcohol using 50%, 70%, 80%, 95% and in absolute alcohol. The tissues were changed at every 1-hour interval. The tissues were cleared by two changes in chloroform, one and half an hour for each. The tissues were embedded with molten paraffin wax.

### Staining of tissues

The section of 4–6-micron thickness was cut and stained with routine staining methods by Hematoxylin and eosin. Results were recorded by gross examination and microphotographs.

### Result and Discussion

In the present study, degenerative changes were noticed in 39 (18.03%) cases. out of 216 liver

**Corresponding Author:**

**Seema Kumari Bishnoi**

Ph.D. Scholar, Department of  
veterinary pathology CVAS,  
Bikaner, Rajasthan, India

lesions examined. Degenerative changes include cell swelling vacuolar degeneration and fatty degeneration in this study.

#### **Cloudy swelling**

Cloudy swelling was found in 11(5.09%) livers out of total 216 goat liver lesion examined.

#### **Grossly**

The affected liver slightly pale, friable, and enlarged with round edges. The cut surface bulged out and the cut edges of the capsule retracted during incision. A lower incidence of 0.96% of cloudy swelling was reported by Sanjeeth *et al.* (2015) [7].

#### **Microscopically**

The hepatic cells were swollen, hazy and cytoplasm showed fine granulation and the sinusoidal spaces minimize. In some cases, connective tissue proliferation found surrounding the swollen hepatic cell (Fig. 1 & 2).

#### **Vacuolar degeneration**

Vacuolar degeneration was found in 16(7.4%) out of total 216 liver lesion examined.

#### **Grossly**

Liver is swollen and cut surface appears pale and soft.

#### **Microscopically**

Cells appear clear due to water content and cytoplasm is vacuolated (Fig.18). In some cases vacuolar degeneration found with congestion and infiltration of macrophages and lymphocytes (Fig. 3).

#### **Fatty changes**

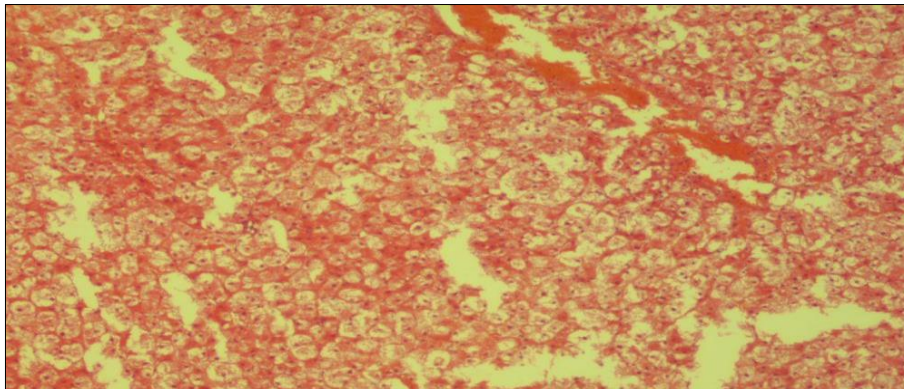
Fatty change was found in 12(5.55%) livers out of total 216 goat liver lesions examined.

#### **Grossly**

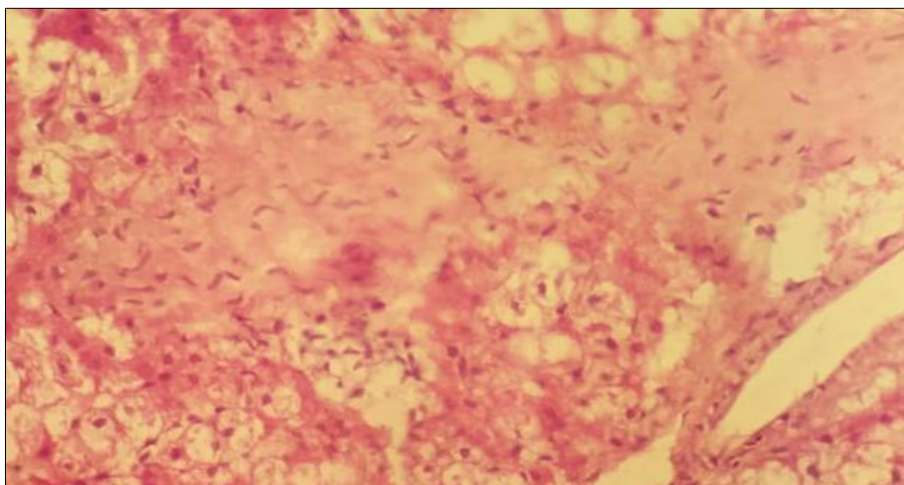
The liver was found enlarged, pale to yellowish in colour, round edges and revealed a greasy texture on cut section and droplets of fat visible on the blade of knife (Fig. 5).

#### **Microscopically**

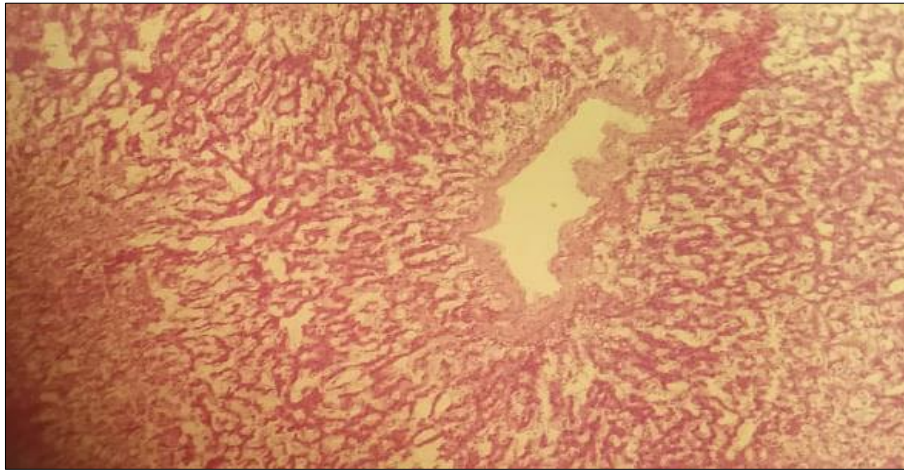
Hepatocytes were found swollen and contained numerous small clear vacuoles of varying size with nucleus pushed toward periphery. Fatty changes were mainly seen around central vein as well as around the portal triad. There was also infiltration of inflammatory cells. There was rupture of adjoining enlarged hepatocytes resulting into fatty cyst (Fig. 6). Similar incidence of 6% of fatty change was reported earlier by Kumar *et al.* (2006) [3] in goat liver.



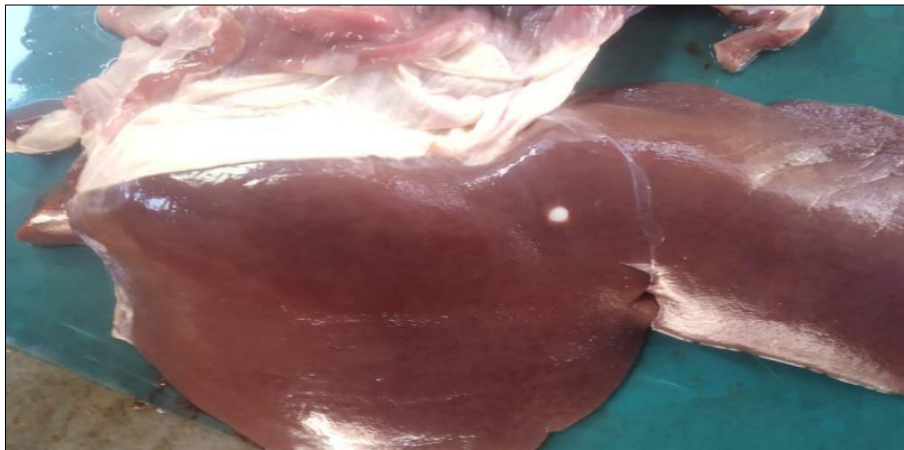
**Fig 1:** Photomicrograph of liver showing cloudy swelling. H&E 100X.



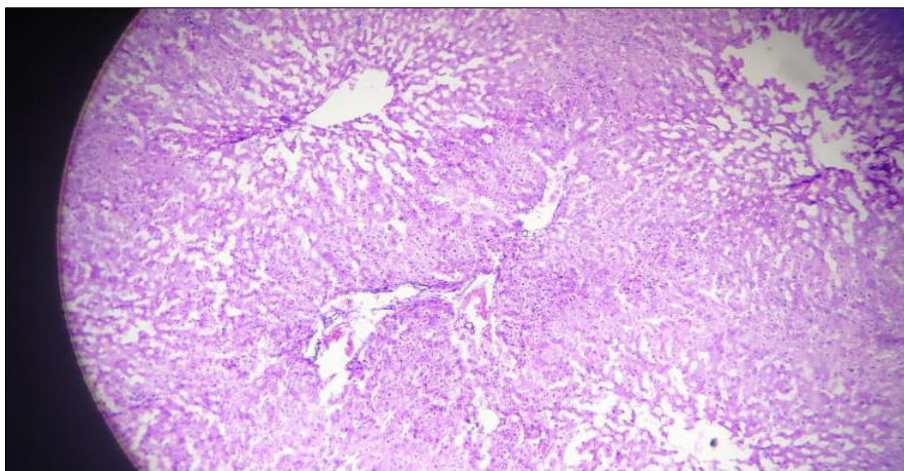
**Fig 2:** Photomicrograph of liver showing cloudy swelling with connective tissue proliferation. H&E 100X



**Fig 3:** Photomicrograph of liver showing vacuolar degeneration. H&E 100X.



**Fig 5:** Gross specimen of liver showing pale, yellowish, and friable fatty liver



**Fig 6:** Photomicrograph of liver showing fatty changes in centrilobular area. H&E 100X.

### Conclusion

In the present study, degenerative changes were recorded in 39 (18.03%) cases out of 216 liver showed different hepatic lesion. That consisted of cloudy swelling, vacuolar degeneration and fatty change were recorded in the liver. A lower incidence of 0.96% of cloudy swelling was creported by Sanjeeth *et al.* (2015) [7]. Swelling of cells is one of the earliest recognizable microscopic changes following cell injury and the cause was failure of the sodium-potassium ion pump mechanism necessary to maintain appropriate osmotic pressure inside the cells. In the present study, fatty change was recorded in 12 (5.55%) livers that were pale and revealed

a greasy texture on cut surface. Microscopically, clear, round vacuoles were noticed with in the cytoplasm of hepatocytes. Similar incidence of 6% of fatty change was reported earlier by Kumar *et al.* (2006) [3] in goat liver. The gross and microscopic findings noticed in the study were consistent with the reports of Johnson *et al.* (1999) [2], Kumar *et al.* (2006) [3], Sanjeeth *et al.* (2015) [7].

### References

1. Dutta A, Ray N, Deb P. Prevalence and Pathology of hepatic disorders of black Bengal goat (*Capra hircus bengalensis*) in West Bengal with special reference to

- liver function test. National symposium on Advances in Pathological Techniques in Diagnosis of Animal, Bird and Fish Diseases, held at Kolkata; c2004.
2. Johnson EH, Muirhead DE, Annamalai K, King JH, AL-Busaigy R, Hammed MS. Hepatic Lipidosis associated with cobalt deficiency in Omani goats. *Veterinary Research Communications*. 1999;23(4):215-221.
  3. Kumar PH, Satyanarayana ML, Suguna Rao, Narayanaswamy HD. Incidence of pathological conditions of liver in goats in around Bangalore. XXIII Annual Conference of IAVP; c2006. p. 27-29.
  4. Mellau LSB, Nonga HE, Karimuribo ED. A slaughterhouse survey of liver lesions in slaughtered cattle, sheep and goats at Arusha, Tanzania. *Research Journal of Veterinary Sciences*. 2010;3(3):179-188.
  5. Naik. Spontaneous hepatic lesions in goats: A pathomorphological study. Diss. Sri Venkateswara veterinary university tirupati-517 502. (ap) India. 2018.
  6. Prasad J. *Goat, Sheep and Pig Production and Management*. 3<sup>rd</sup> Edn. 2009.
  7. Sanjeeth BS, Goswami P, Churamani CP, Jain NK. Study on the incidence of liver lesions in goats (*Capra hircus*) at Jabalpur, Madhya Pradesh, India. *Indian Journal of Veterinary Pathology*. 2015;39(1):24-29.