The Pharma Innovation Journal 2023; 12(2): 07-09

www.ThePharmaJournal.com

The Pharma Innovation

ISSN (E): 2277-7695
ISSN (P): 2349-8242
NAAS Rating: 5.23
TPI 2023; 12(2): 07-09

www.thepharmajournal.com
Received: 07-11-2022
Accepted: 11-12-2022

Madhu D
Ph.D. Scholar, Department of Anatomy and Histology, Veterinary College, KVAFSU, Bidar, Karnataka, India

Prasad RV
Retired Professor, Department of Anatomy and Histology, Veterinary College, KVAFSU, Bidar, Karnataka, India

Jamuna KV
Retired Professor, Department of Anatomy and Histology, Veterinary College, KVAFSU, Bidar, Karnataka, India

Sathyanarayan K
President, Karnataka Veterinary Council, Veterinary College Campus, Hebbal, Bangalore

Nagaraj CS
Dean, Veterinary College, Hebbal, KVAFSU, Bidar, Karnataka, India

Shridhar NB
Professor and Head, Department of Obscure Disease and Veterinary Pharmacology, Veterinary College, KVAFSU, Bidar, Karnataka, India

Corresponding Author:
Madhu D
Ph.D. Scholar, Department of Anatomy and Histology, Veterinary College, KVAFSU, Bidar, Karnataka, India

Histology of the spleen of blackbuck (*Antilope cervicapra*)

Madhu D, Prasad RV, Jamuna KV, Sathyanarayan K, Nagaraj CS and Shridhar NB

DOI: https://doi.org/10.22271/tpi.2023.v12.i2a.18517

Abstract
The spleen is the largest secondary lymphatic organ involved in filtering the blood and initiating immune responses against antigens. The present study was carried out on the spleen of three black buck collected from Shri Chamarajendra Zoological Garden, Mysore. Histologically, the spleen was surrounded by a thick capsule composed mainly of dense collagen fibers with few smooth muscle fibers. Thick trabeculae consisting of collagen, elastic, reticular and smooth muscle fibers extended from the capsule into the parenchyma. The splenic parenchyma was composed of red pulp and white pulp. The white pulp was distributed throughout the spleen and was composed of lymphatic nodules with a central artery. Histochemically the capsule and trabeculae showed moderate to strong PAS reaction. However, no reaction was seen in the white pulp and red pulp.

Keywords: Blackbuck, spleen, red pulp, white pulp, wild animal

Introduction
The blackbuck (*Antilope cervicapra*), which is the common name for an antelope mainly located in India with few populations in Pakistan and Nepal. Blackbucks have been commonly hunted for human consumption and also in the preparation of decorative trophies, thereby it is becoming extinct due to constant poaching. It is protected under scheduled-1 animal in Wildlife Protection Act (WPA) 1972. The histology and histochemistry of the spleen in this species has not been explored. To understand the pathological changes and the death of these animals due to disease outbreak which is common to ruminants. Therefore the present study was undertaken to understand the histology and histochemistry of the spleen.

Materials and Methods
The research is carried out in the Department of Veterinary Anatomy and Histology, Veterinary College, Hebbal, Bangalore. Three samples of the spleen from the black buck were fixed in 10% NBF and were processed by routine ethanol–chloroform sequence and embedded in paraffin. 6 µm thick sections were cut for histological and histochemical study. Various staining methods like Mayer's haemalum-eosin-phloxine method (Singh and Sulochana, 1996) [9], Van Gieson's stain (Culling, 1974) [3], Verhoeff's stain (Singh and Sulochana, 1996) [9], Gomori's method (Luna, 1968) [7], Masson's trichrome (Singh and Sulochana, 1996) [9] and Periodic Acid Schiff's reaction (Culling, 1974) [3] were adopted to study the histology and histochemistry.
The permission to collect the black buck spleen was taken from The Principal Chief Conservator of Forest, Aranya Bhavana, Bangalore.

Results and Discussion
The present study is the first report on the histology of spleen in blackbuck (*Antilope cervicapra*) but studies on the spleen of other ruminants were carried out by Eurell and Frappier (2006) [4]. Histologically, the spleen of black buck was surrounded by a thick capsule composed mainly of dense collagen fibers with few elastic and smooth muscle fibers (Fig 1) which concurs with the report of Kannamani and Mariappa (1972) [5] in buffalo, Bajpai and Chandra (1995) [1] in goat, Khalel (2010) [6] in sheep. The outer fibrous layer of the capsule was covered by mesothelium. Thick trabeculae made of collagen, elastic, reticular and smooth muscle fibers extended from the capsule into the parenchyma (Fig 2 & 3), similar observation were recorded by Eurell and Frappier (2006) [4] in domestic animals.

Branches of the splenic artery entered the capsule and extended into the large trabeculae as trabecular arteries along with trabecular nerve.

The splenic parenchyma consisted of reticular fibers forming the meshwork for red pulp with extensive venous sinuses, splenic cords and RBC's (Fig 4) similar to the observations made by Onkar and Govardhan (2013) [8]. Abundant smooth muscle fibers were seen in the red pulp (Fig 2) which support the report of Eurell and Frappier (2006) [4] in domestic ruminants, who also described that in horses and dogs myofibroblasts were present in the red pulp.

White pulp was distributed throughout the spleen and was composed of oval to elliptical shaped lymphatic nodule. It was surrounded by blood sinusoids, smooth muscle fibers and reticular fibers in small amount with a nodular artery (Fig 5 & 6). Presence of smooth muscle fibers in the capsule and trabeculae indicated the capacity of spleen to expand and store large number of erythrocytes and also the ability for rapid contraction. The white pulp is composed of lymphocytes, macrophages, dendritic cells, plasma cells, arterioles and capillaries in a reticular framework similar to that found in the red pulp which correlates to the observations made by Cesta (2006) [2].

The inner surface of the capsule showed moderate to strong PAS positive reaction. The trabeculae also showed strong PAS positive reaction. The white pulp did not exhibit any PAS positive reaction however the endothelial lining of the pulp arteriole showed strong PAS positive reaction (Fig 7). The red pulp exhibited weak reaction of the connective tissue stroma.

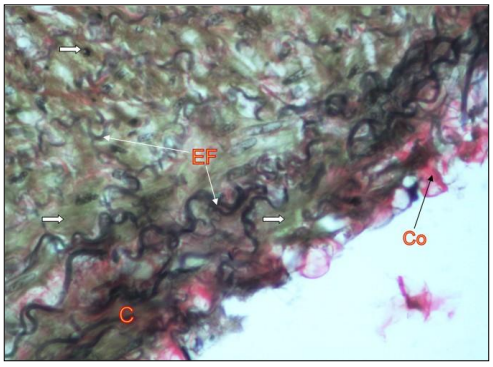

Fig 1: Photomicrograph showing interwoven network of collagen, elastic fiber and smooth muscle in the capsule of black buck spleen. EF- elastic fiber, C- capsule, Co- collagen fiber, big arrows showing smooth muscle. Verhoeffs Van Giesons X400

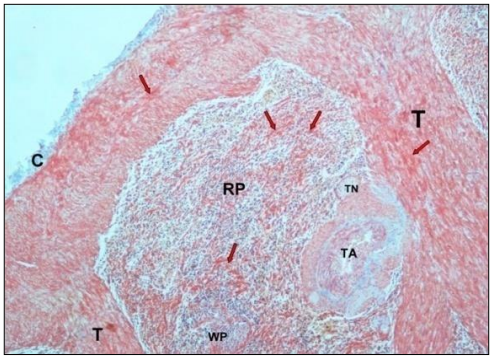

Fig 2: Photomicrograph showing red pulp, white pulp and trabeculae in black buck spleen. C- capsule, T- trabeculae, RP- red pulp, WP- white pulp, TA- trabecular artery, TN- trabecular nerve, arrows showing smooth muscle fibers. Masson's trichrome X40

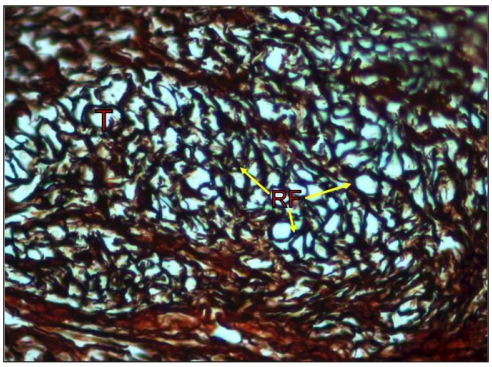

Fig 3: Photomicrograph showing reticular fibers in the trabeculae of black buck spleen. RF-reticular fiber, T- trabeculae. Gomori's method X 400

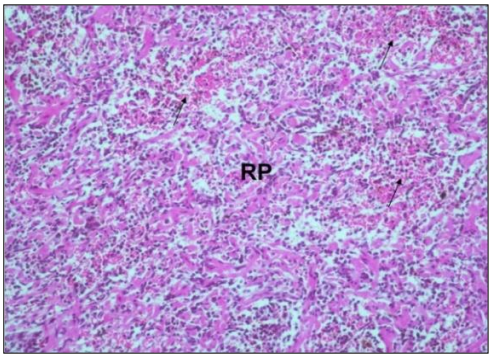

Fig 4: Photomicrograph showing RBC's in red pulp of black buck spleen. RP- red pulp, arrows indicating of RBC's. H&E X 100

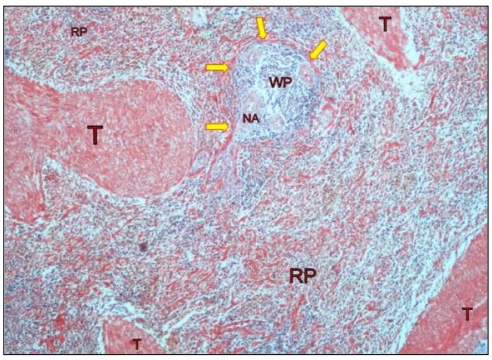

Fig 5: Photomicrograph showing demarcation between red pulp and white pulp by smooth muscle fiber in black buck spleen. T- trabeculae, RP- red pulp, WP- white pulp, NA- nodular artery, arrows showing smooth muscle. Masson's trichrome X 40

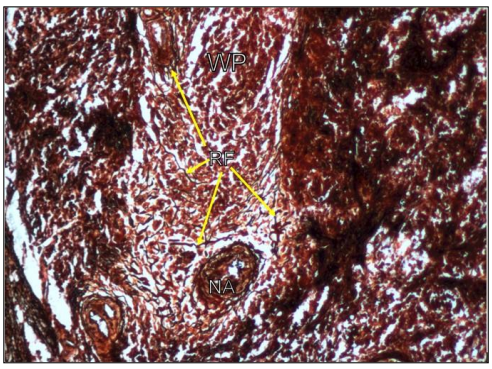

Fig 6: Photomicrograph showing demarcation around white pulp by reticular fibers and also presence of reticular fiber within the white pulp in black buck spleen. RF- reticular fiber, WP- white pulp, NA- nodular artery. Gomori's method X 100

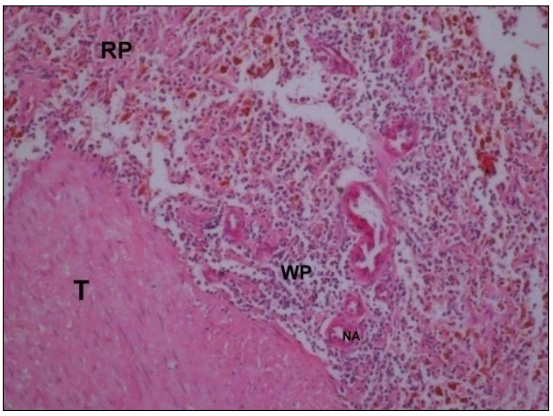

Fig 7: Photomicrograph showing strong positive reaction in the trabeculae of black buck. WP- white pulp, RP- red pulp, T- trabeculae, NA- nodular artery. PAS X 100

References

1. Bajpai UK, Chandra G. Histoarchitecture of the supportive tissue of the spleen of goat (*Capra hircus*). Indian veterinary journal. 1995;72(8):889-892.
2. Cesta MF. Normal Structure, Function, and Histology of the Spleen. Toxicologic Pathology. 2006;34(5):455-465.
3. Culling CFA. Handbook of Histopathological and Histochemical Techniques. Edn. 3rd. Butterworth and Company Limited. London; c1974, p. 219-268.
4. Eurell JA, Frappier BL. Dellmanns Text Book of Veterinary Histology., 6th edition, Black well publishing; c2006, p. 147-232.
5. Kannamani G, Mariappa D. Histology of the capsule and trabeculae in the spleen of Indian buffalo (*Bubalus bubalis*). Indian veterinary journal. 1972;49(2):253-255.
6. Khalel EM. Anatomical and histological study of the spleen in Iraqi sheep (Awasi sheep). Basrah Journal of Veterinary Research. 2010;9(2):163-171.
7. Luna LG. Manual of Histological Staining Methods, of Armed Forces Institute of Pathology. 3rd edn. McGraw Hill book Company, New York; c1968, p. 87-88.
8. Onkar DP, Govardhan SA. Comparative histology of human and dog spleen. Journal of Morphological Sciences. 2013;30(1):16-20.
9. Singh UB, Sulochana S. Hand book of Histological and Histochemical Techniques. Edn. 2nd, Premier Publishing House; c1996, p. 39-59.