



ISSN (E): 2277-7695  
ISSN (P): 2349-8242  
NAAS Rating: 5.23  
TPI 2023; 12(1): 2199-2203  
© 2023 TPI

[www.thepharmajournal.com](http://www.thepharmajournal.com)

Received: 18-10-2022

Accepted: 26-11-2022

#### S Aasritha

PG Scholar, Department of Veterinary Pathology, College of Veterinary Science, Rajendranagar, Hyderabad, Telangana, India

#### M Lakshman

Professor and Head, Department of Veterinary Pathology, College of Veterinary Science, Rajendranagar, Hyderabad, Telangana, India

#### S Soujanya

Assistant Professor, Department of Veterinary Pathology, College of Veterinary Science, Rajendranagar, Hyderabad, Telangana, India

#### M Usharani

Professor and Head, Department of Veterinary Pharmacology and Toxicology, College of Veterinary Science, Rajendranagar, Hyderabad, Telangana, India

#### M Architha

PG Scholar, Department of Veterinary Pathology, College of Veterinary Science, Rajendranagar, Hyderabad, Telangana, India

#### Y Ravikumar

Assistant Professor, Department of Veterinary Pathology, College of Veterinary Science, Rajendranagar, Hyderabad, Telangana, India

#### B Swathi

Assistant Professor, Department of Veterinary Pathology, College of Veterinary Science, Rajendranagar, Hyderabad, Telangana, India

#### Corresponding Author:

#### M Lakshman

Professor and Head, Department of Veterinary Pathology, College of Veterinary Science, Rajendranagar, Hyderabad, Telangana, India

## Alterations in biochemical parameters, antioxidative enzymes and histopathology of liver induced by imidacloprid (IMI) and Chlorpyrifos (CPF) in male *Wistar* rats

S Aasritha, M Lakshman, S Soujanya, M Usharani, M Architha, Y Ravikumar and B Swathi

#### Abstract

Present study was aimed to evaluate the individual and combined toxic effects of imidacloprid (IMI) and chlorpyrifos (CPF) on liver of male *Wistar* rats. A total of 24 adult male *Wistar* albino rats were procured and divided into 4 groups consisting of 6 rats in each. The group 1 served as control, group 2 rats treated with IMI (@ 10 mg/kg b.wt, once daily orally), group 3 rats were treated with CPF (@ 7.5 mg/kg b.wt, once daily orally) and group 4 administered with IMI (@ 10 mg/kg b.wt, once daily orally) + CPF (@ 7.5 mg/kg b.wt, once daily orally) for 28 days. Rats were sacrificed on 29<sup>th</sup> day of experiment. Biochemical parameters were estimated from serum. Tissue samples of liver were collected for histopathology and for analysis of tissue antioxidant profiles. The present study revealed significant ( $p < 0.05$ ) reduction of AST and ALT in groups 2, 3 and 4 when compared to group 1. The tissue oxidative stress parameters revealed a significant ( $p < 0.05$ ) increase of TBARS/MDA, decrease in GSH and SOD activity in groups 2, 3 and 4 compared to group 1 on 29<sup>th</sup> day of the experiment. Liver sections on 29<sup>th</sup> day in group 2 showed cloudy swelling, focal necrosis, disruption of hepatic cords and mild sinusoidal congestion. Sections from group 3 revealed congestion of central vein and portal vein, dilated sinusoids, inflammatory cell infiltration in periportal area while, group 4 rats revealed more severe lesions like centrilobular necrosis, diffuse vacuolar degeneration of hepatocytes, few pyknotic nuclei, karyorrhexis and karyolysis than in group 2 and 3 rats on 29<sup>th</sup> day of experiment.

**Keywords:** Imidacloprid, Chlorpyrifos, Liver, Histopathology, Antioxidant profiles

#### 1. Introduction

In recent years, pesticide resistance has led to the practice of rotating or combining pesticides with the Chlorpyrifos (CPF) and Imidacloprid (IMI) insecticide mixture proving efficient in managing pests (Xu *et al.*, 2020) [1]. Imidacloprid is a chlorinated analogue of nicotine and was the first representative of neonicotinoid insecticides to be registered for use as a pesticide by the United States Environmental Protection Agency (USEPA) (Koshlukova, 2006) [2]. Neonicotinoids are regarded as neurotoxicants due to their agonistic action against nAChRs in insects and mammals preventing impulse transmission between nerves, resulting in paralysis and death eventually (Thompson *et al.*, 2020) [3]. IMI is widely used in insect pest management and flea control in cats and dogs due to its highly selective toxicity in insects and low mammalian toxicity (Abou-Donia *et al.*, 2008) [4] and is highly efficient against sucking and mining pests in vegetables, fruits, sugar beet, cotton and rice (Matsuda *et al.*, 2001) [5]. However, widespread usage of IMI has led to contamination of soil, water and food products indicating several possible routes of human exposure (Thompson *et al.*, 2020) [3]. Long term exposure can cause various toxicities in human and non-target animals.

Chlorpyrifos (CPF) is classified as a moderately hazardous, class II insecticide (WHO, 2020) [6]. In the last few decades, CPF has become one of the most extensively used broad spectrum organophosphate (OP) pesticides in home and industrial applications all over the world (Perez-Fernandez *et al.*, 2020) [7]. Humans are exposed to CPF through the ingestion of contaminated food and water, as well as dermal absorption and inhalation (Peiris and Dhanushka, 2017) [8]. CPF exhibits its primary mode of action through inhibition of acetyl cholinesterase (AChE) activity at synapses, where the accumulation of acetylcholine (ACh) at the nerve endings and neuromuscular junction disrupts cholinergic transmission resulting in paralysis (Basare *et al.*, 2017) [9].

Imidacloprid acts as an agonist on the nAChRs. Whereas, CPF acts by inhibition of AChE enzyme. Both actions resulting in hyperexcitation. As both pesticides IMI and CPF are known to act by excitation of the nervous system by activating nAChRs. Therefore, the toxic pathological consequences due to their co-exposure prompted us to undertake the present study in male rats whether co-exposure to IMI and CPF could be more hazardous than exposure to the individual agents.

## 2. Materials and Methods

### 2.1 Experimental animals

Twenty four (24) adult male albino *Wistar* rats weighing between 250-300 g were procured from Jeeva Life Sciences (ISO 9001:2015 certified company), Hyderabad for this research. The experiment was carried out according to the guidelines and prior approval of Institutional Animal Ethics Committee (IAEC-No. 4/25/C.V.Sc., Hyd.IAEC-rats/02.07.2022).

### 2.2 Chemical source

- Imidacloprid (IMI) was procured from Insecticides (INDIA) limited. Hyderabad.
- Chlorpyrifos (CPF) was procured from Insecticides (INDIA) limited. Hyderabad.

### 2.3 Experimental design

**Table 1:** Experimental design with group wise treatment protocol

Group	No. of rats	Treatment
Group 1	6	Control
Group 2	6	Imidacloprid (IMI) @ 10 mg/kg b.wt, P/O daily for 28 days.
Group 3	6	Chlorpyrifos (CPF) @ 7.5 mg/kg b.wt, P/O daily for 28 days
Group 4	6	Imidacloprid (IMI) @ 10 mg/kg b.wt + Chlorpyrifos (CPF) @ 7.5 mg/kg b.wt P/O daily for 28 days.

### 2.4 Serum biochemistry

Approximately, 2 mL of blood was collected from each rat into plain serum vacutainers and allowed to clot for 3-4 h, later centrifuged (Sigma 1-13-bench top laboratory centrifuge, USA) at 10000 revolutions per minute (rpm) for 10 minutes (min), serum was separated into eppendorf tubes and stored at -20°C. The stored samples were used for serum biochemistry by using semiautomatic ELISA reader (Multiskan GO Microplate (ELISA) Spectrophotometer, Thermo scientific, USA) by using Erba mannheim biochemical kits (Transasia Biomedicals Ltd., Solan, Himachal Pradesh, India). Alanine amino transferase (ALT) and aspartate amino transferase (AST) were estimated as per modified International Federation of Clinical Chemistry (IFCC) method (Shaw *et al.*, 1983) [10].

### 2.5 Tissue antioxidant profiles

Liver was quickly removed after sacrifice, trimmed of extraneous tissue and washed with cold physiological saline solution. One gram of tissue sample with 10 mL of 0.2 M Tris HCl buffer (pH 7.2) was taken into a tissue homogenizer to get 10 per cent homogenate to carry out all the tissue antioxidant parameters. The tissue oxidation was measured by the reaction of the lipid peroxidation (LPO) end products like

malondialdehyde (MDA) with thiobarbituric acid (TBA) (Balasubramanian *et al.*, 1988) [11]. Activity of GSH (Moron *et al.*, 1979) [12] and SOD (Madesh and Balasubramanian, 1998) [13] were also measured to know the antioxidant status of the tissue.

### 2.6 Gross and histopathology

Detailed necropsy was conducted on 29<sup>th</sup> day of the experiment and gross changes were noticed, if any. Pieces of liver were collected in 10% neutral buffer formalin (NBF). Samples were processed, sectioned (5µm), stained with Hematoxylin and Eosin (H&E) as per the standard protocol (Luna, 1968) [14].

### 2.7 Statistical analysis

Data obtained were subjected to statistical analysis by applying one way Analysis of variance (ANOVA) using Graph Pad Prism 5, version 5.01 (Graph Pad Software, California, USA). Differences between the means were tested by using Tukey's test, a multiple comparison procedure and significance level was set at  $p < 0.05$  (Snedecor and Cochran, 1994) [15].

## 3. Results and Discussion

### 3.1 Effect on biochemical parameters

Significantly ( $p < 0.05$ ) higher aspartate transaminase (AST) and alanine transaminase (ALT) mean values (IU/L) were observed in rats of group 2, 3 and group 4 on 29<sup>th</sup> day respectively when compared with group 1 rats. Changes in group 2 might be due to IMI induced hepatocellular necrosis and defect in the permeability of cell membrane. These results are in agreement with the earlier reports of Badawy *et al.* (2018) and Hassan *et al.* (2019) [16-17]. While, the changes in group 3 could be attributed to excessive ROS release by CPF intermediates causing lipid peroxidation (LPO) where disruption of the membrane leads to the leakage of the aforementioned enzymes from hepatic cytosol into the bloodstream (Tang *et al.*, 2001 and Kurt *et al.*, 2022) [18-19]. The results are in accordance with the findings of Ravikumar *et al.* (2021) and Saoudi *et al.* (2021) [20-21]. However, there was a significant ( $p < 0.05$ ) increase in mean values in the rats of combined toxic dose (group 4) than the rats of individual treated groups 2 and 3 (Table 2). This might be due to structural and functional damage to liver through oxidative injury by synergistic interaction between IMI and CPF suggesting possible hepatotoxicity.

**Table 2:** Effect of IMI and CPF on biochemical parameters

Group	AST- IU/L	ALT- IU/L
G1 (control)	42.48 <sup>a</sup> ±1.69	37.55 <sup>a</sup> ±1.36
G2(IMI)	64.96 <sup>b</sup> ±1.84	57.00 <sup>b</sup> ±1.20
G3(CPF)	76.54 <sup>c</sup> ±1.41	70.38 <sup>c</sup> ±1.29
G4(IMI+ CPF)	101.8 <sup>d</sup> ±1.96	97.22 <sup>d</sup> ±1.36

Values are Mean + SE (n = 6); One way ANOVA

Means with different superscripts in a column differ significantly at  $p < 0.05$ .

### 3.2 Effect on antioxidative parameters

The mean values of Thiobarbituric acid reactive substances (TBARS) were significantly ( $p < 0.05$ ) higher and the mean values of reduced glutathione (GSH) and superoxide dismutase (SOD) were significantly ( $p < 0.05$ ) lower in groups 2, 3 and group 4 compared with group 1 rats on 29<sup>th</sup> day of

the experiment. These results in groups 2 and 3 are in agreement with Lohiya *et al.*, (2017) [22] and Albasher *et al.* (2019) [23] respectively. However, these values were significantly ( $p < 0.05$ ) differed in group 4 compared to groups 2 and 3 (Table 3). Increase in TBARS level indicate IMI and CPF induced LPO leading to cell injury there by tissue

damage. While the reduction in GSH levels might be due to excessive use of GSH to counteract the over production of free radicals as well as to detoxify the chemicals. Decrease in SOD levels may be attributed to exhaustion of SOD due to excessive production of free radicals beyond the antioxidative clearance capacity.

**Table 3:** Effect of IMI and CPF on tissue antioxidant profiles

GROUP	TBARS (n moles MDA/mg protein)	GSH ( $\mu\text{M}/\text{mg protein}$ )	SOD (U/mg protein)
G1 (control)	4.83 <sup>a</sup> ±0.31	10.48 <sup>a</sup> ±0.57	8.00 <sup>a</sup> ±0.14
G2 (IMI)	6.03 <sup>b</sup> ±0.06	8.65 <sup>b</sup> ±0.29	6.84 <sup>b</sup> ±0.18
G3 (CPF)	6.89 <sup>c</sup> ±0.12	8.42 <sup>b</sup> ±0.32	6.07 <sup>c</sup> ±0.12
G4 (IMI+CPF)	7.91 <sup>d</sup> ±0.22	6.00 <sup>c</sup> ±0.17	5.32 <sup>d</sup> ±0.11

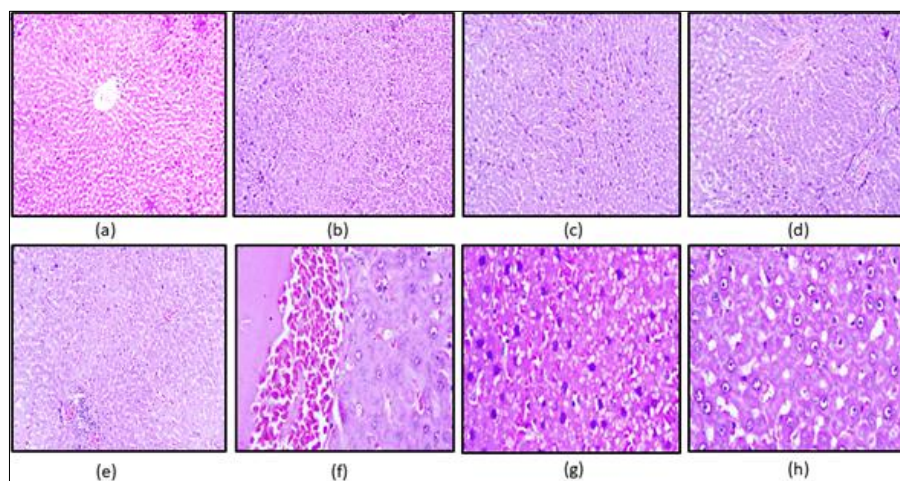
Values are Mean + SE (n = 6); One way ANOVA

Means with different superscripts in a column differ significantly at  $p < 0.05$ .

### 3.3 Gross and histopathological findings in liver

At the end of the experiment animals were sacrificed and thoroughly examined for gross changes if any. The liver showed mild to moderate congestion in rats of groups 2 and 3 and moderate to severe in group 4 on 15<sup>th</sup> and 29<sup>th</sup> day of the experiment. The liver tissue sections of group 1 rats revealed normal architecture of hepatic cords radiating from central vein (Fig. 1a). Sections of liver on 29<sup>th</sup> day in group 2 showed cellular swelling, focal necrosis and disruption of hepatic cords (Fig. 1b), mild sinusoidal congestion and hepatocytic necrosis (Fig. 1c). Cellular swelling might be attributed to ionic imbalance caused by disrupted function of Na/K/ATPase pump due to excessive ROS production (Khalaf *et al.*, 2020) [24]. These findings are in line with the results of Taha *et al.* (2021) [25] and Hassanen *et al.* (2022) [26]. Sections of liver in group 3 on 29<sup>th</sup> day revealed congestion of central vein and portal vein, dilated sinusoids (Fig. 1d), focal infiltration of inflammatory cells in periportal area (Fig. 1e).

Necrosis could be due to cellular protein degradation due to oxidative injury by CPF. Dilated sinusoids may be due to shrinkage and necrosis of hepatocytes (Wankhede *et al.*, 2017) [27]. These changes are in agreement with Ravikumar *et al.*, 2021 [2] and Saoudi *et al.* (2021) [21]. Various liver sections of group 4 rats on 29<sup>th</sup> day showed mild central vein congestion and centrilobular necrosis of hepatocytes, presence of plasma and blood cells in central vein (Fig. 1f). Complete loss of hepatic architecture with uniform eosinophilic mass like appearance and diffuse vacuolar degeneration of hepatocytes (Fig. 1g). Few sections revealed degeneration of hepatocytes with swollen nuclei, necrosis of hepatocytes, few pyknotic nuclei, karyorrhexis and karyolysis (Fig.1h).The pronounced changes in group 4 might be due to synergistic action of IMI and CPF on CYP450 system and cumulative accumulation of their reactive metabolites in liver as it is the principal target organ for detoxification mechanism.



**Fig 1:** Photomicrograph of liver showing (a) normal architecture of hepatic cords radiating from central vein G-1 H&E×100. (b) cellular swelling, focal necrosis and disruption of hepatic cords G-2 H&E×100. (c) mild sinusoidal congestion and hepatocytic necrosis G-2 H&E×100. (d) congestion of central vein and portal vein, dilated sinusoids G-3 H&E×100. (e) focal infiltration of inflammatory cells in periportal area G-3 H&E×100. (f) mild central vein congestion and centrilobular necrosis of hepatocytes, presence of plasma and blood cells in central vein G-4 H&E×400. (g) complete loss of hepatic architecture with uniform eosinophilic mass like appearance and diffuse vacuolar degeneration of hepatocytes G-4 H&E×400. (h) degeneration of hepatocytes with swollen nuclei, necrosis of hepatocytes, few pyknotic nuclei, karyorrhexis and Karyolysis G-4 H&E×400.

### 4. Conclusion

In conclusion, the adverse effects of combined IMI and CPF group (Group 4) were more severe than the individual groups (Group 2 and 3) due to synergistic action of the combined pollutants on CYP450 system.

### 5. Acknowledgement

The authors are thankful to the PV Narsimha Rao Telangana Veterinary University for providing support and necessary facilities to carry out the research work.



## 6. References

- Xu L, Luo G, Sun Y, Huang S, Xu D, Xu G, *et al.* Multipl down-regulated cytochrome P450 monooxygenase genes contributed to synergistic interaction between chlorpyrifos and imidacloprid against *Nilaparvata lugens*. *Journal of Asia-Pacific Entomology*. 2020;23(1):44-50.
- Koshlukova S. Imidacloprid: Risk characterization document: dietary and drinking water exposure. Department of Pesticide Regulation. Office of Environmental Health Hazard Assessment: California Environmental Protection Agency; c2006. p. 1-195.
- Thompson DA, Lehmler HJ, Kolpin DW, Hladik ML, Vargo JD, Schilling KE, *et al.* A critical review on the potential impacts of neonicotinoid insecticide use: Current knowledge of environmental fate, toxicity, and implications for human health. *Environmental Science: Processes and Impacts*. 2020;22(6):1315-1346.
- Abou-Donia MB, Goldstein LB, Bulman S, Tu T, Khan WA, Dechkovskaia AM, *et al.* Imidacloprid induces neurobehavioral deficits and increases expression of glial fibrillary acidic protein in the motor cortex and hippocampus in offspring rats following in utero exposure. *Journal of Toxicology and Environmental Health*. 2008;71(2):119-130
- Matsuda K, Buckingham SD, Kleier D, Rauh JJ, Grauso M, Sattelle DB. Neonicotinoids: insecticides acting on insect nicotinic acetylcholine receptors. *Trends in Pharmacological Sciences*. 2001;22(11):573-580.
- World Health Organization (WHO). WHO recommended classification of pesticides by hazard and guidelines to classification. Geneva. 2020.
- Perez-Fernandez C, Morales-Navas M, Aguilera-Saez LM, Abreu AC, Guardia-Escote L, Fernandez I, *et al.* Medium and long-term effects of low doses of Chlorpyrifos during the postnatal, preweaning developmental stage on sociability, dominance, gut microbiota and plasma metabolites. *Environmental Research*. 2020;184:1-13.
- Peiris D C and Dhanushka T. Low doses of chlorpyrifos interfere with spermatogenesis of rats through reduction of sex hormones. *Environmental Science and Pollution Research International*. 2017;24 (26):20859-20867.
- Basaure P, Peris-Sampedro F, Cabre M, Reverte I and Colomina MT. Two cholinesterase inhibitors trigger dissimilar effects on behavior and body weight in C57BL/6 mice: the case of chlorpyrifos and rivastigmine. *Behavioural Brain Research* 2017;318:1-11.
- Shaw LM, Stromme JH, London JL, Theodorsen L. International Federation of Clinical Chemistry, Scientific Committee, Analytical Section. IFCC methods for measurement of catalytic concentration of enzymes. *Journal of Clinical Chemistry and Clinical Biochemistry*. 1983;2(10):633-646.
- Balasubramanian KA, Manohar M and Mathan VI. An unidentified inhibitor of lipid peroxidation in intestinal mucosa. *Biochimica et Biophysica Acta (BBA)- Lipids and Lipid Metabolism*. 1988;962(1):51-58.
- Moron MS, Depierre J Wand Mannervik B. Levels of glutathione, glutathione reductase and glutathione S-transferase activities in rat lung and liver. *Biochimica et Biophysica Acta (BBA)-General Subjects*. 1979;582(1):67-78.
- Madesh M and Balasubramanian KA. Microtiter plate assay for superoxide dismutase using MTT reduction by superoxide. *Indian Journal of Biochemistry and Biophysics*. 1998;35(3):184-188.
- Luna G L H T. *Manual of Histological and Special Staining Techniques*. 2<sup>nd</sup> edn. The Blakiston Divison McGraw-Hill Book Company, Inc. New York, Toronto, London; c1968;1-5 and 9-34.
- Snedecor GW, Cochran G. *Statistical methods*, Edn 8, IOWA State University Press. America, USA; c1994. p. 64-67.
- Badawy M, Ahmed N, Attia A. Sub-acute oral toxicity of imidacloprid and fipronil pesticide mixture in male albino rats; biochemical and reproductive toxicity evaluation. *Journal of Materials and Environmental Sciences*. 2018;9(8):2431-2437.
- Hassan A, Abo El-Ela FI, Abdel-Aziz AM. Investigating the potential protective effects of natural product quercetin against imidacloprid-induced biochemical toxicity and DNA damage in adult's rats. *Toxicology Reports*. 2019;6:727-735.
- Tang J, Cao Y, Rose RL, Brimfield AA, Dai D, Goldstein JA *et al.* Metabolism of chlorpyrifos by human cytochrome PCYP isoforms and human, mouse, and rat liver microsomes. *Drug Metabolism and Disposition*. 2001;29(9):1201-1204.
- Kurt BO, Konukoglu D, Kalayci R, Ozdemir S. Investigation of the protective role of selenium in the changes caused by chlorpyrifos in trace elements, biochemical and hematological parameters in rats. *Biological Trace Element Research*. 2022;200(1):228-237.
- Ravikumar Y, Madhuri D, Lakshman M, Reddy AG, Kalakumar B. Changes in biochemical parameters, antioxidative enzymes and histopathology of liver induced by cadmium (Cd) and chlorpyrifos (CPF) in Wistar rat. *International Journal of Animal Research*. 2021;55(4):1-5.
- Saoudi M, Badraoui R, Rahmouni F, Jamoussi K, Feki A E. Antioxidant and protective effects of *Artemisia campestris* essential oil against chlorpyrifos-induced kidney and liver injuries in rats. *Frontiers in Physiology*. 2021;12:1-10.
- Lohiya A, Kumar V, Punia JS. Imidacloprid induced oxidative stress and histopathological changes in liver of rats. *Indian Journal of Animal Research*. 2017;51(3):531-536.
- Albasher G, Almeer R, Al-Otibi FO, Al-Kubaisi N, Mahmoud AM. Ameliorative effect of beta vulgaris root extract on chlorpyrifos-induced oxidative stress, inflammation and liver injury in rats. *Biomolecules*. 2019;9(7):261-276.
- Khalaf AA, Hassanen EI, Ibrahim MA, Tohamy AF, Aboseada MA, Hassan HM, *et al.* Rosmarinic acid attenuates chromium-induced hepatic and renal oxidative damage and DNA damage in rats. *Journal of Biochemical and Molecular Toxicology*. 2020;34(11):e22579.
- Taha MAI, Badawy MEI, Abdel-Razik RK, Younis HM, Abo-El-Saad MM. Mitochondrial dysfunction and oxidative stress in liver of male albino rats after exposing to sub-chronic intoxication of chlorpyrifos, cypermethrin, and imidacloprid. *Pesticide Biochemistry and Physiology*. 2021;178:1-13.

26. Hassanen EI, Hussien AM, Mehanna S, Ibrahim MA, Hassan NH. Comparative assessment on the probable mechanisms underlying the hepatorenal toxicity of commercial imidacloprid and hexaflumuron formulations in rats. *Environmental Science and Pollution Research International*. 2022;29(19):29091-29104.
27. Wankhede V, Hedau M, Ingole RS, Hajare SW, Wade MR. Histopathological alterations induced by subacute imidacloprid toxicity in Japanese quails and its amelioration by *Butea monosperma*. *Journal of Pharmacognosy and Phytochemistry*. 2017;6(3):252-257.