



ISSN (E): 2277-7695

ISSN (P): 2349-8242

NAAS Rating: 5.23

TPI 2023; 12(1): 772-779

© 2023 TPI

[www.thepharmajournal.com](http://www.thepharmajournal.com)

Received: 26-11-2022

Accepted: 29-12-2022

**Prashanth Anur Gopal**

Department of Veterinary  
Pathology, Veterinary College  
Hebbal, Bengaluru, Karnataka,  
India

**HD Narayanaswamy**

Department of Veterinary  
Pathology, Veterinary College  
Hebbal, Bengaluru, Karnataka,  
India

**ML Sathyanarayana**

Department of Veterinary  
Pathology, Veterinary College  
Hebbal, Bengaluru, Karnataka,  
India

**Suguna Rao**

Department of Veterinary  
Pathology, Veterinary College  
Hebbal, Bengaluru, Karnataka,  
India

**D Rathnamma**

Department of Veterinary  
Microbiology, Veterinary College  
Hebbal, Bengaluru, Karnataka,  
India

**Divakar Hemadri**

National Institute of Veterinary  
Epidemiology and Disease  
Informatics (NIVEDI),  
Ramagondanahalli, Yelahanka,  
Bengaluru, Karnataka, India

**Corresponding Author:**

**Prashanth Anur Gopal**

Department of Veterinary  
Pathology, Veterinary College  
Hebbal, Bengaluru, Karnataka,  
India

## Studies on respiratory tract pathology and molecular diagnosis of Newcastle disease in chickens in Karnataka

**Prashanth Anur Gopal, HD Narayanaswamy, ML Sathyanarayana, Suguna Rao, D Rathnamma and Divakar Hemadri**

### Abstract

The main focus of this study was on respiratory tract pathology and molecular diagnosis of Newcastle disease virus (NDV) in chickens (n=783) from 50 poultry farms in Karnataka during May 2017 to May 2018. New Castle disease (ND) was confirmed in 8 broiler farms, 4 layer farms and 12 indigenous farm birds. Main clinical signs recorded were anorexia depression greenish white diarrhoea, ruffled feathers with droopy wings along with nasal discharge and cough. Grossly, congestion of respiratory tracts with pneumonic changes in lungs, laryngitis, tracheitis, airsacculitis and mucous exudate in nasal passage were seen. Histopathology revealed nasal mucosal thickening with glandular hyperplasia, congestion/hyperemia, edema and mononuclear cell infiltration in mucosal and submucosal blood vessels along with respiratory epithelial atrophy. Phylogenetic tree construction analysis revealed 100% similarity between field and many published strains as far as 356 bp F gene segment was concerned.

**Keywords:** NDV, PCR, F gene, newcastle disease, inclusion bodies, Karnataka

### 1. Introduction

Newcastle disease or Ranikhet disease is an economically important and highly infectious viral disease of birds and a major threat to poultry industry. It is caused by virulent strains of avian paramyxovirus 1 (APMV-1), a non-segmented, single-stranded, negative-sense, enveloped RNA virus, from the genus *Orthoavulavirus* and species avian orthoavulavirus 1, infecting at least 236 species of wild birds and poultry species, affecting the respiratory, gastrointestinal, lymphoid, nervous and reproductive systems and cause up to 100% mortality in non-vaccinated chickens (Saurez *et al.*, 2020) [1].

Due to the severe nature of ND and the related consequences, NDV is included in "LISTED" agents (notifiable disease) by OIE (Boynukara *et al.*, 2013; Mariappan *et al.*, 2018) [2, 3]. The first outbreaks of Newcastle disease (ND) in poultry were reported in 1926, in Java, Indonesia (Kraneveld, 1926) [4] and in Newcastle-upon-Tyne, England (Doyle, 1927) [5]. The name "Newcastle disease" was coined by Doyle to avoid a descriptive name that might be confused with other diseases. The International Committee on Taxonomy of Viruses (ICTV) officially renamed Newcastle disease virus (NDV) to avian avulavirus 1 in 2016 (Afonso *et al.*, 2016) [6] and further renamed it in 2018 as avian orthoavulavirus.

In developing countries, outbreaks of ND caused by virulent NDV have been identified as limiting factor to the growth of the poultry industry (Akanbi *et al.*, 2020) [7]. Newcastle disease (ND) is one of the most catastrophic diseases of poultry and has potential to cause enormous economic losses in the poultry industry (Balchandran *et al.*, 2014; Abdisa and Tagesu, 2017; Mariappan *et al.*, 2018) [8, 9, 10]. Khorajiya *et al.*, (2017) [11] calculated economic losses of Rs. 37,19,223 due to ND outbreak in thirteen flocks (11 layer flocks) in Anand District of Gujarat state during the period of January 2013 to July 2014 in terms of mortality, vaccination, production loss, treatment and biosecurity measures. Since its first report in India between 1928 and 1930 at Ranikhet (Edwards 1928) [11] and Madras-Chennai (Kylasam, 1930) [12], ND still remains endemic in India and outbreaks are reported regularly inspite of a stringent vaccination policy against ND (Jakhesara *et al.*, 2016; Khorajiya *et al.*, 2015) [13, 14].

The present study was aimed to study the pathomorphology, to ascertain the usefulness of particular primers for NDV disease diagnosis in Karnataka and to know the degree of homology of the genetic material of the above viruses by sequencing and comparing with already known strains.

## 2. Materials and Methods

### 2.1 Sample collection

A total of 783 birds from 50 poultry farms with respiratory signs brought to Department of Veterinary Pathology, Veterinary College, Hebbala, Bengaluru during May 2017 to May 2018 from Karnataka and adjacent poultry belts of Hyderabad and Namakkal were studied in detail for clinical signs and gross pathology. Representative 200 birds (four birds from each farm) were considered as a source material and samples from organs such as nasal passage, larynx, trachea, lungs, air sacs and any other organ showing gross changes were collected for histopathological studies in 10 percent neutral buffered formalin. They were suitably processed by routine standard paraffin embedding technique and 5 $\mu$  thick sections were cut and stained by hematoxylin and eosin (H and E) (Luna, 1968) [15]. Pooled samples of larynx, trachea and lungs from dead birds and laryngotracheal swab contents in 50 percent glycerol-PBS from live birds were collected aseptically in 50 mL sterile polycarbonate/2 mL cryo-vials and carried on cold carrier for immediate storage at -20 °C.

### 2.2 Polymerase chain reaction and sequencing

Triturated pooled sample or swab dipped PBS was used for RNA isolation using Trizol method (GeNei™ TRIzol Reagent). The RNA samples were quantified by absorbance without prior dilution using the NanoDrop® Spectrophotometer (ND-1000). The A260/A280 ratio approximately 2.0 for RNA was considered pure. RNA was either used immediately for cDNA synthesis by standard protocol using Biorad iScript™ cDNA Synthesis Kit (catalog # 1708891) or stored at -70 °C.

PCR band for NDV was amplified using gene specific primers viz., 5'GCAGCTGCAGGGATTGTGGT3' and 5'TCTTTGAGCAGGAGGATGTTG3' with a product size of 356 bp for NDV (Nanthakumar *et al.*, 2000) [16] primers for F gene at 356 bp, which was read corresponding to 100 bp ladder. The forward primer was located at nucleotide position of 158-177 and reverse primer at a nucleotide position of 513-493. For positive control, RNA from ND Vaccine was used. For negative control, PBS was used. Primers were synthesized commercially from M/s Bio Serve Biotechnologies (India) Pvt. Ltd, Hyderabad. These primers were reconstituted in 1x TE buffer (TE) to obtain the required concentration of 200 picomol/ $\mu$ L. the PCR reaction was carried out using Amplicon Taq 2x Master mix with initial denaturation at 94 °C for 2.5 minutes followed by denaturation at 94 °C for 45 seconds, annealing at 58 °C for 45 seconds, extension at 72 °C, for 45 seconds, final extension at 72 °C for 5 minutes and finally held at 4 °C, as per the conditions in OIE manual. About 2  $\mu$ l of amplified products were subjected to agarose gel electrophoresis with 100 kb marker and DNA bands were visualized and the images were captured by Gel Doc.

The PCR product (about 50  $\mu$ l) of both vaccine and field samples of NDV were sent to Eurofins Genomics India Pvt. Ltd for sequencing. Both forward and reverse sequencing was done. Sequencing was done to identify the degree of homology between the vaccine and field strains. Analysis of sequencing was done by phylogenetic tree construction.

## 3. Results and Discussions

### 3.1 occurrence of NDV and age group involvement

NDV was confirmed by PCR assay using primers for F gene. PCR band was amplified at 356 bp, which was read

corresponding to 100 bp ladder (Fig.1). The forward primer was located at nucleotide position of 158-177 and reverse primer at a nucleotide position of 513-493. In the present study, among 200 representative samples from 50 farms (n=783) with respiratory disorder, ND was confirmed in six farms (24 birds, 12%) with a population of 132 birds. ND was confirmed in two broiler farms (4%), one layer farm (2%) and three indigenous/ backyard poultry farms (6%).

The birds in broiler farms affected with ND were of 2-3 and 3-4 weeks age, layers affected with ND were 40-50 weeks age and birds of indigenous farm affected were 20-30 weeks age. Similar age group occurrence in broilers was reported by earlier workers between 18-38 days (Rahman *et al.*, 2016) [17], 3-4 weeks (Etriwati *et al.*, 2017) [18], beyond 30 days (Das *et al.*, 2018) [19] and 28-40 days (Tran *et al.*, 2020) [20]. The reason for occurrence in broilers after second week may be due to waning of maternally derived antibodies and higher stocking density, often getting contact with local and migratory birds, not maintaining cold chain in case of vaccination of birds as reported by Das *et al.*, (2018) [19].

In layers and indigenous birds the occurrence of ND was reported in 7-41 weeks and 4-36 weeks (Rahman *et al.*, 2016) [17] and 14-33 weeks and 8-24 weeks (Etriwati *et al.*, 2017) [18] old birds which were similar to occurrence of ND in the present study. Similar age group occurrence in layers was also reported by Balachandran *et al.*, (2014), Khorajiya *et al.*, (2015) and Akanbi *et al.*, (2020) [8, 14, 7]. Occurrence of ND in layers of older age group (40-50 weeks) could be due to increased disease susceptibility in older age. However, Shankar, (2008) [21] reported that ND can affect all age groups of birds.

Despite the stringent vaccination protocol in layers, NDV outbreaks have been reported even in cases of vaccinated populations (Van Boven *et al.*, 2008; Nakamura *et al.*, 2008; Perozo *et al.*, 2012) [22, 23, 24]. As reported by Khan *et al.*, (2011) [25] and Mariappan *et al.*, (2018) [3], vaccine failure may be due to inadequate application procedures of vaccines, multi-age of birds, virus shedding of the healthy birds post-vaccination and vaccine mismatch. They also opined that it will be very appropriate to incorporate local virus strain along with genotype II (Lasota) vaccine as in India poultry population is endemic to ND.

### 3.2 Clinical signs in ND positive birds

The respiratory clinical signs observed in ND positive farm birds were nasal discharge and/ or oral discharge as a reaction to viral entry, leading to cough and respiratory rales/hurried respiration. Edema and/or cyanosis of comb and wattle with epidermal necrosis were recorded in one bird due to cytopathological changes including endothelial cell damage and intravascular agglutination and lysis of erythrocytes (Cheville and Lehmkuhl, 2009) [26]. Nasal discharge was observed in broilers and indigenous birds whereas layers showed oral mucus discharge of crop fluid related to stasis of the gastrointestinal tract and pouring of crop fluid due to compression while handling the bird. Cough and respiratory rales with hurried respiration were seen in all groups and were of milder degree. Edema of comb and wattle was more in broilers.

Other associated clinical signs recorded were anorexia, depression, ruffled feathers droopy wings, sudden death, decreased egg production, conjunctivitis, nervous signs consisting of muscle tremors with jerking of head/ head twitch and torticollis (Fig.2), digestive disorders exhibited as

greenish and/or whitish diarrhea soiling vents and huddling together. Nervous signs, sudden death and decreased egg production were seen only in layers in the present study whereas conjunctivitis and huddling together was recorded among broilers and indigenous birds. Common signs like anorexia, depression, ruffled feathers and diarrhea were recorded in all birds.

Similar gross lesions in APMV-1 infection, varying according to tropism of the virus were also reported by Susta *et al.*, (2011) [27], Boulianne, (2012) [28] and other workers (Echeonwu *et al.*, 1993, Kommers *et al.*, 2002, Wakamatsu *et al.*, 2006, Nakamura *et al.*, 2008, Brar *et al.*, 2017; Igwe *et al.*, 2018; Akanbi *et al.*, 2020; Kabiraj *et al.*, 2020, Fawzy *et al.*, 2021; Shadood and Najem, 2021) [29, 30, 31, 23, 32, 33, 7, 34, 35, 36]. They reported swelling and darkening of tissues about the eyes with sticky ocular and nasal discharge, violent diarrhoea, conjunctivitis, paralysis and death in 2-3 days in many chickens whereas lesions in some surviving birds included CNS signs like tremors, twisting of the head and neck, circling, paresis, paralysis, terminal clonic spasms with high morbidity and mortality. In mesogenic APMV-1 infection they reported mild or inapparent respiratory signs, mild depression and anorexia, less CNS signs, complete cessation of production which may or may not resume depending on stage of lay during infection, low quality of soft-shelled, roughened, or deformed eggs, with low mortality.

Akanbi *et al.*, (2020) [7] reported that pneumonia and airsacculitis seen in 24 week unvaccinated, NDV affected chickens may be due to opportunistic co-pathogens (*Escherichia coli* and *Klebsiella* spp.), isolated from the lungs and peritoneum.

Less severe form of disease and mortality recorded in the present study can be due to good vaccination practices (Cattoli *et al.*, 2011) [37].

### 3.3 Gross pathology in ND positive birds

In the present study, gross changes recorded in the ND positive birds were congestion and hemorrhages on mucosal layer of laryngo-tracheal region and lung parenchyma. Mucus exudate with mucosal thickening due to inflammation was recorded in nasal passage and trachea, which also had fibrinous exudate in lumen (Fig.3). Mucous plug was recorded on laryngeal mucosa (Fig.4). Infraorbitals were swollen. Gelatinous edema, consolidation of lung parenchyma and pus oozing from cut surface of lungs were also recorded in indigenous birds (Fig.5). Air sac membrane had congestion/ hyperemia and opacity of air sac membrane due to fibrin deposition (Fig.6).

Gross changes in other organs of ND positive birds in the present study included pinpoint hemorrhages, perihepatic fibrosis and friability of liver; swollen, mottled/congested kidneys with uric acid deposits and pale areas of necrosis; distension of ureters with urate; enlarged proventricular glands with hemorrhages at tip and necrosis of mucosa; hemorrhages at gizzard and jejunal junction; congestion, hemorrhages on serosal surface and button like ulcers of mucosa in other parts of the intestines; enlargement, congestion, hemorrhages and necrosis in ileal Peyer's patches and caecal tonsils; urate deposits on heart; congested thecal blood vessels in ovaries; congestion and enlargement of thymus; mottling, swelling and necrotic foci on spleen; conjunctivitis, pale areas and congestion of blood vessels in Harderian gland.

Similar gross changes were also recorded in respiratory tract

of chickens by Wakamatsu *et al.*, (2006) and Cattoli *et al.*, (2011) [31, 37] who also recorded necrosis and hemorrhage of the laryngeal tonsils in the cranial portion of the trachea in virulent viscerotropic NDV due to cytolytic reactions while Kabiraj *et al.*, (2020) [34] reported congestion, hemorrhages and consolidation with traces of fibrin in lungs in ND due to inflammation.

### 3.4 Histopathology of respiratory tract in ND positive birds

The histopathological changes recorded in NDV positive birds in the present study varied between farm types with less lesions in layers and occurred ununiformly which may be based on strains of virus and host factors. The overall histopathological changes in respiratory tract included congestion/ hyperemia and edema in mucosal and submucosal blood vessels of nasal passage, larynx, trachea, lung parenchyma and air sac interstitial blood vessels. Mild hemorrhages were recorded in laryngo-tracheal mucosa and submucosal region, parabronchial septa of lungs and air sac membrane. Inflammatory changes included mainly mononuclear cell infiltration (lymphocytes and plasma cells) with few heterophils and macrophages in mucosal and submucosal regions of the respiratory tract and in lung interstitium. Laryngotracheal region showed inflammatory changes with sero-mucinous exudate in lumen. Degenerative changes consisted of epithelial desquamation, epithelial atrophy and necrotic cellular debris in the laryngo-trachea lumen. Degenerative changes in lungs included surface epithelial cell necrosis and necrotic cellular debris in bronchial lumen whereas in air sacs, inflammatory changes included exudate and fibrin formation in interstitium. Hyperplastic changes recorded were mucous gland hyperplasia and mucosal thickening in nasal passage and laryngo-tracheal region. In lungs, hyperplastic changes included smooth muscle hypertrophy. Bacterial colonies were observed in luminal exudate of laryngo-tracheal region (Fig 7 to 14).

Similar changes were reported by Brown *et al.*, (2012) [38], in a detection study of presence of Avian Paramyxovirus-1 through immunohistochemistry in tracheas of experimentally and naturally infected chickens who found the lesions like degeneration, erosion and ulceration of surface epithelial cells with marked thickening of epithelium (due to hyperplasia or metaplasia of surface cells), infiltration of inflammatory cells in the propria/submucosa consisting of lymphocytes, plasma cells and scattered heterophils.

Kommers *et al.*, (2002), Wakamatsu *et al.*, (2006), Nakamura *et al.*, (2008), Susta *et al.*, (2011), Anis *et al.*, (2013), Brown *et al.*, (2012), Eze *et al.*, (2014), Brar *et al.*, (2017), Akanbi *et al.*, (2020), Ansori *et al.*, (2021) and Fawzy *et al.*, (2021) [30, 31, 23, 27, 39, 38, 40, 32, 7, 41, 34] have observed similar microscopical lesions in respiratory tract and other organs of ND affected birds.

The molecular pathogenesis of NDV was well described by Cheville *et al.*, (1972) and Merz *et al.*, (1980) [42, 43]. They reported that Paramyxoviruses contain two types of surface spikes (one with combined hemagglutinin/neuraminidase activity and the other a fusion factor) which are activated after cleaving by a host protease. According to them, Hemagglutinin is used for attachment and entry of virus and cell fusion activity helps in spreading of infection from cell to cell by fusion of adjacent plasma membranes and formation of syncytia. They also recorded that infected cell undergo cell



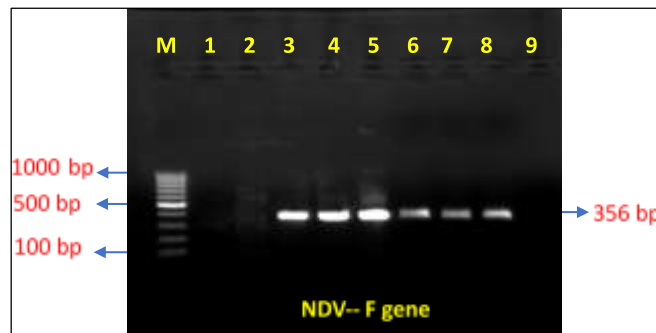
swelling and loss of cilia. They found that NDV replicates in cells of the endothelial, monocyte-macrophage and reticular systems with Neurotropic NDV replicating first in endothelial cells of capillaries of the brain and then spreading to neurons and glia. Also, they reported that NDV can infect erythrocytes resulting in intravascular agglutination and lysis of erythrocytes, leading to splenic erythrophagocytosis. In late stages of disease, they recorded marked infiltration of plasmacytes, macrophages and lymphocytes at sites of infection.

Fusion protein, which initiates infection by fusion with the host cell membrane, is synthesized as a F0 precursor, which is activated only after cleavage into F1 and F2 fragments by host cell proteases (Munir *et al.*, 2011 and Abdisa and Tagesu, 2017). A cleavage site containing multiple basic amino acids could be cleaved by a broad range of proteases in tissues, thus making the virus a velogenic one. They noted that the amino acid sequence 112-R/K-R-Q-R/K-R-F-117 is present in virulent ND viruses, whereas 112-G/E-K/RQ-G/E-R-L-117

was the general sequence of low virulent viruses at the cleavage site. In the present study, the proteases present in various tissue of chickens is responsible for widespread lesions affecting multiple organs.

### 3.5 Sequencing results of NDV PCR product

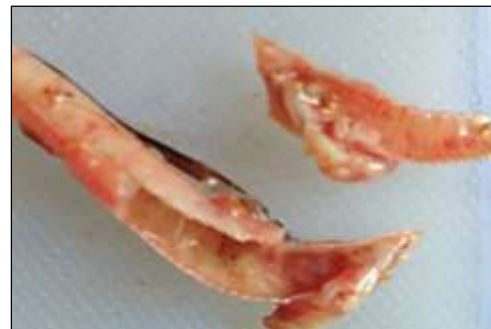Sanger sequencing was done at Eurofins Genomics India Pvt. Ltd by sending 50µl of PCR product of field sample of NDV. Analysis of the degree of homology between the field strain, vaccine strain and many published strains by phylogenetic tree construction revealed 100% similarity, as far as the 356 bp F gene segment is concerned (Fig. 15). Similar sequential analysis were done by Kant *et al.*, (1997), Nanthakumar *et al.* (2000), Gowthaman *et al.* (2017) and Ananth *et al.* (2018)<sup>146, 16, 47, 48]</sup> who concluded that the sequence analysis of this portion of the F gene would confirm pathotypes and facilitate the generation of molecular epidemiological data which is very much essential in disease control.



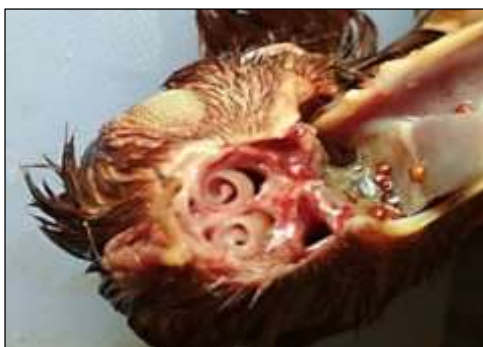**Fig 1:** Gel doc photograph of agarose gel electrophoresis; screening of tissue samples for NDV (F gene at 356 bp). Lane M: 100 bp DNA ladder; Lane 1 and 2: Negative control and NTC Positive control (ND vaccine); Lanes 3: Positive control (ND vaccine); Lanes 4-8: Positive bands from field samples



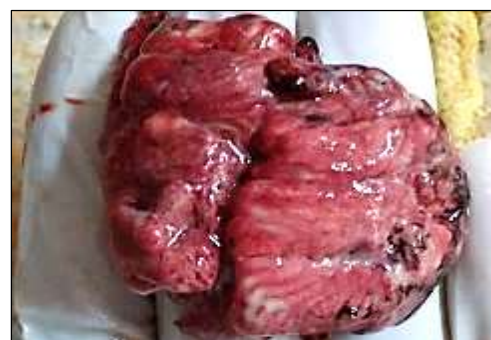**Fig 2:** NDV positive bird showing torticollis



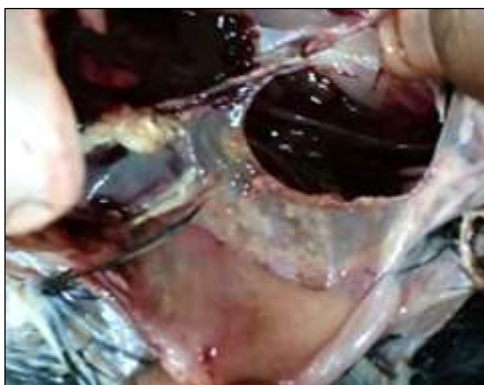
**Fig 4:** Gross: Moderate laryngeal congestion along with inflamed mucous membrane, in a NDV positive indigenous bird



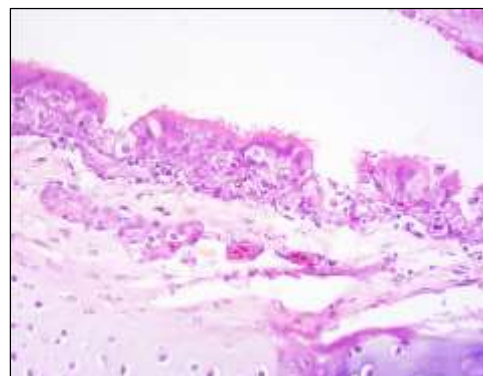
**Fig 3:** Gross: Thickened left nasal septum in a NDV positive indigenous bird



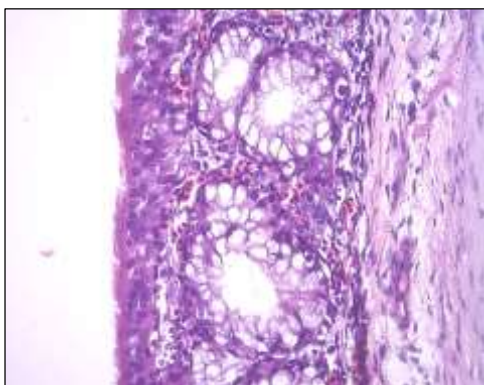
**Fig 5:** Gross: Pneumonic lungs showing suppurative pneumonia, in a NDV positive indigenous bird



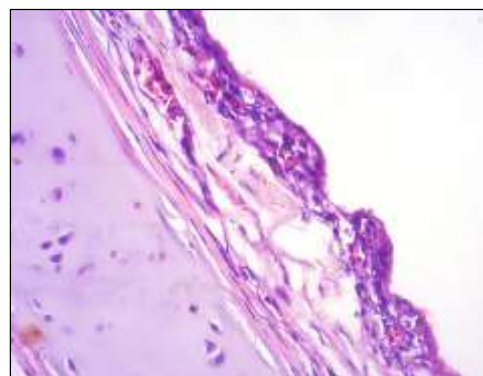
**Fig 6:** Gross: Thick, cloudy air sacs along with white plaques in a NDV positive indigenous bird



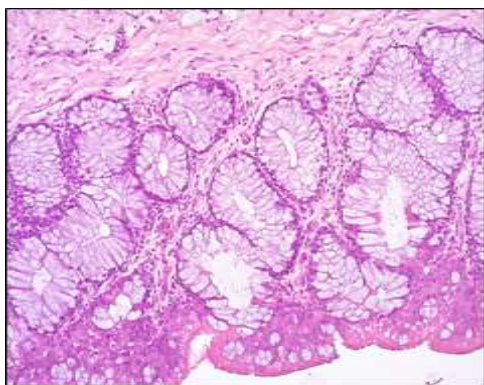
**Fig 10:** Section of laryngo-tracheal epithelium from ND positive bird showing glandular atrophy, along with loss of mucosal cilia. H&E X400



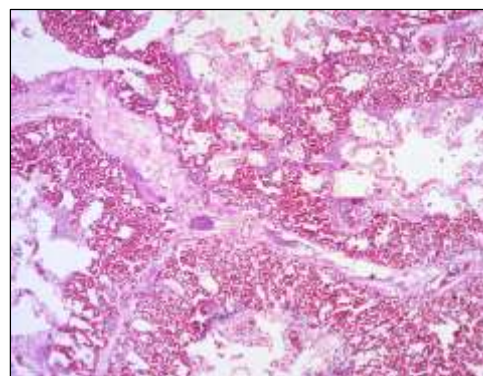
**Fig 7:** Section of nasal septum from ND positive bird showing increased mucosal goblet cell activity. H&E X400



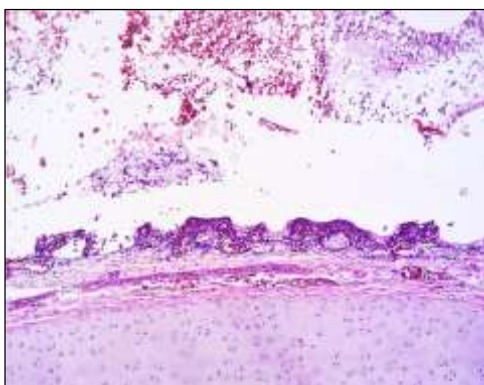
**Fig 11:** Section of trachea from ND positive bird showing atrophied mucosal layer with deciliation and inactive mucosal gland. H&E X400



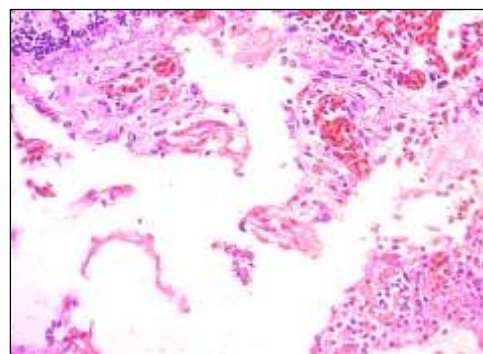
**Fig 8:** Section of nasal septum from ND positive layers showing mucosal thickening with hypertrophied mucosal glands. H&E X200



**Fig 12:** Section of lungs from ND positive bird showing severe congestion and interstitial edema along with bacterial colonies. H&E X100

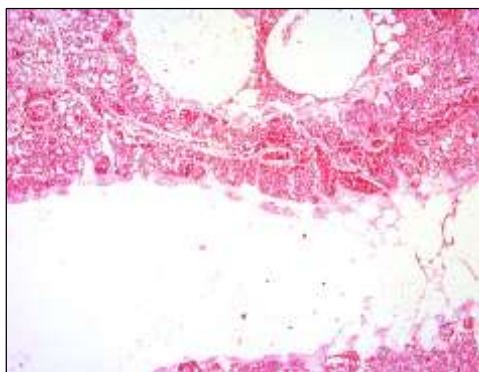


**Fig 9:** Section of larynx from ND positive bird showing atrophied mucosa and exudate in the lumen. H&E X100

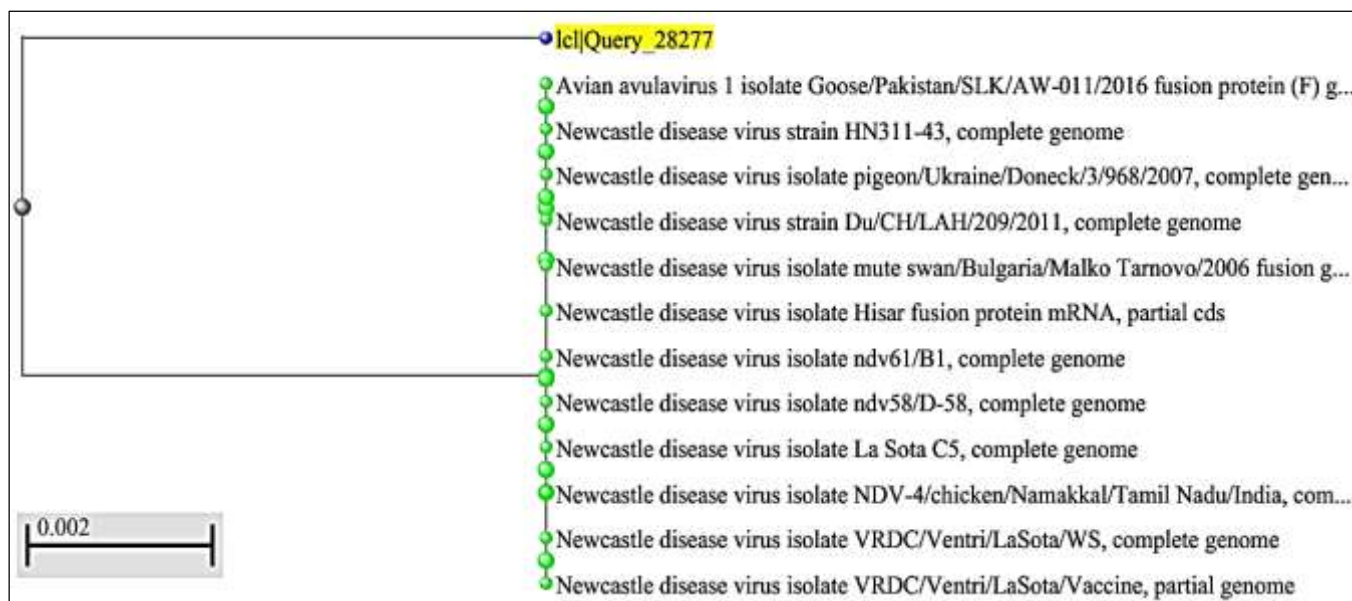


**Fig 13:** Section of lungs from ND positive bird showing severe congestion and cellular infiltration. H&E X400





**Fig 14:** Section of lungs from ND positive bird showing severely dilated parabronchial lumen with emphysematous change. H&E X50



**Fig 15:** Phylogenetic tree for NDV field sample

#### 4. Conclusions

The present study findings indicate that in spite of stringent vaccination programme in organised sector of poultry, ND is still a challenge at unorganised backyard farming which is continuous source of infection to organized farms and has to be addressed by proper awareness for small farmers, timely vaccination and proper biosecurity control measures.

#### 5. Acknowledgment

I would like to thank Dept. of Animal Husbandary and Veterinary Services, Govt. of Karnataka, for deputing me to pursue my PhD degree programme and ICAR lab, Department of Pathology, Veterinary College, Bengaluru for providing necessary infrastructure.

#### 6. References

- Suarez DL, Miller PJ, Koch G, Mundt E, Rautenschlein S. Newcastle disease, other avian paramyxoviruses, and avian meta-pneumovirus infections. *Diseases of poultry*; c2020 Jan, 109-166.
- Boynukara B, Gulhan T, Çoven F, Kizirogl UI, Durmuş A. Determination of Newcastle disease virus among wild bird populations in Lake Van basin, Turkey. *Turkish Journal of Veterinary & Animal Sciences*. 2013;37(1):86-93.
- Mariappan AK, Munusamy P, Kumar D, Latheef SK, Singh SD, Singh R, *et al*. Pathological and molecular investigation of velogenic viscerotropic Newcastle disease outbreak in a vaccinated chicken flocks. *Virusdisease*. 2018 Jun;29(2):180-191.
- Kranveld FE. A poultry disease in the Dutch East Indies. *Nederlands-Indische Bladen voor Diergeneeskunde*. 1926;(38):448-450.
- Doyle TM. A hitherto unrecognized disease of fowls due to a filter-passing virus. *Journal of Comparative Pathology and Therapeutics*. 1927;40:144-169.
- Afonso CL, Amarasinghe GK, Banyai K, Bao Y, Basler CF, Bavari S, *et al*. Taxonomy of the order Mononegavirales: update. *Archives of virology*. 2016 Aug;161(8):2351-2360.
- Akanbi OB, Shittu I, Barde IJ, Rimfa AG. Molecular and pathological investigation of a natural outbreak of Newcastle disease caused by genotype XVII in White Leghorn chickens. *Avian Pathology*. 2020 Jul;49(4):394-403.
- Balachandran P, Srinivasan P, Sivaseelan S, Balasubramaniam GA, Murthy TG. Isolation and characterization of Newcastle disease virus from vaccinated commercial layer chicken. *Veterinary World*; c2014 Jul, 7(7).
- Abdisa T, Tagesu T. Review on Newcastle disease of poultry and its public health importance. *Journal of Veterinary Science and Technology*. 2017;8(3):441.
- Khorajiya JH, Joshi BP, Mathakiya RA, Prajapati KS,

- Sipai SH. Economic impact of genotype-XIII Newcastle disease virus infection on commercial vaccinated layer farms in India. *Journal of Veterinary Science and Technology*. 2018;8(5):280-288.
11. Edwards JT. Annual report imp. Inst. Vet. Res. Mukteswar, India; c1928. p. 14-15.
  12. Kylasam A. Study on madras fowl pest. *Indian veterinary Journal*. 1930;8:346-352.
  13. Jakhesara SJ, Prasad VV, Pal JK, Jhala MK, Prajapati KS, Joshi CG. Pathotypic and sequence characterization of Newcastle disease viruses from vaccinated chickens reveals circulation of genotype II, IV and XIII and in India. *Transboundary and emerging diseases*. 2016 Oct;63(5):523-539.
  14. Khorajiya JH, Pandey S, Ghodasara PD, Joshi BP, Prajapati KS, Ghodasara DJ, *et al.* Patho-epidemiological study on Genotype-XIII Newcastle disease virus infection in commercial vaccinated layer farms. *Veterinary World*. 2015 Mar;8(3):372.
  15. Luna LG. *Manual of histologic staining methods of the Armed Forces Institute of Pathology*; c1968.
  16. Nanthakumar T, Kataria RS, Tiwari AK, Butchaiah G, Kataria JM. Pathotyping of Newcastle disease viruses by RT-PCR and restriction enzyme analysis. *Veterinary Research Communications*. 2000 May;24(4):275-86.
  17. Rahman M, Adhikary G. Poultry diseases in some selected areas in Sylhet district of Bangladesh. *J Sylhet Agril Univ.*, c2016, 3(1).
  18. Etriwati RD, Handharyani E, Setiyaningsih S. Pathology and immunohistochemistry study of Newcastle disease field case in chicken in Indonesia, *Veterinary World*, 10(9), 1066-1071.
  19. Das A, Ghosh P, Sen A, Das A, Chowdhury S. A retrospective analysis of prevalence of Newcastle disease and infectious bursal disease in poultry at Kishoreganj. Bangladesh. *Journal of Veterinary Medicine and Health*. 2018;2(2):108.
  20. Tran GT, Sultan S, Osman N, Hassan MI, Van Dong H, Dao TD, *et al.* Molecular characterization of full genome sequences of Newcastle disease viruses circulating among vaccinated chickens in Egypt during 2011-2013. *Journal of Veterinary Medical Science*; c2020. p. 19-0623.
  21. Shankar BP. Common respiratory diseases of poultry. *Veterinary World*. 2008 Jul;1(7):217.
  22. Van Boven M, Bouma A, Fabri TH, Katsma E, Hartog L, Koch G. Herd immunity to Newcastle disease virus in poultry by vaccination. *Avian pathology*. 2008 Feb;37(1):1-5.
  23. Nakamura K, Ohtsu N, Nakamura T, Yamamoto Y, Yamada M, Mase M, *et al.* Pathologic and immunohistochemical studies of Newcastle disease (ND) in broiler chickens vaccinated with ND: severe non-purulent encephalitis and necrotizing pancreatitis. *Veterinary Pathology*. 2008 Nov;45(6):928-933.
  24. Perozo F, Marcano R, Afonso CL. Biological and phylogenetic characterization of a genotype VII Newcastle disease virus from Venezuela: efficacy of field vaccination. *Journal of clinical microbiology*. 2012 Apr;50(4):1204-1208.
  25. Khan MY, Arshad M, Mahmood MS, Hussain I. Epidemiology of Newcastle Disease in Rural Poultry in Faisalabad, Pakistan. *International Journal of Agriculture and Biology*, c2011, 13(4).
  26. Cheville NF. *Ultrastructural pathology: the comparative cellular basis of disease*. 2<sup>nd</sup> edn, John Wiley & Sons; c2009 Jun. p. 364.
  27. Susta L, Miller PJ, Afonso CL, Brown CC. Clinicopathological characterization in poultry of three strains of Newcastle disease virus isolated from recent outbreaks. *Veterinary pathology*. 2011 Mar;48(2):349-360.
  28. Boulianne M. *Avian disease manual (no. V605 boua)*: edn. 7<sup>th</sup>., American association of avian pathologists; c2012. p. 62-66.
  29. Echeonwu GO, Iroegbu CU, Emeruwa AC. Recovery of velogenic Newcastle disease virus from dead and healthy free-roaming birds in Nigeria. *Avian Pathology*. 1993 Jun;22(2):383-387.
  30. Kommers GD, King DJ, Seal BS, Carmichael KP, Brown CC. Pathogenesis of six pigeon-origin isolates of Newcastle disease virus for domestic chickens. *Veterinary Pathology*. 2002 May;39(3):353-362.
  31. Wakamatsu NO, King DJ, Kapczynski DR, Seal BS, Brown CC. Experimental pathogenesis for chickens, turkeys and pigeons of exotic Newcastle disease virus from an outbreak in California during 2002-2003. *Veterinary pathology*. 2006 Nov;43(6):925-933.
  32. Brar RS, Leishangthem GD, Gadhav PD, Singh ND, Banga HS, Mahajan V, *et al.* Diagnosis of Newcastle disease in broiler by histopathology and immunohistochemistry. 2017;41(1):60-62.
  33. Igwe AO, Afonso CL, Ezema WS, Brown CC, Okoye JO. Pathology and distribution of velogenic viscerotropic Newcastle disease virus in the reproductive system of vaccinated and unvaccinated laying hens (*Gallus gallus domesticus*) by immunohistochemical labelling. *Journal of comparative pathology*. 2018 Feb;159:36-48.
  34. Kabiraj CK, Mumu TT, Chowdhury EH, Islam MR, Nooruzzaman M. Sequential pathology of a genotype XIII Newcastle disease virus from Bangladesh in chickens on experimental infection. *Pathogens*. 2020 Jul;9(7):539.
  35. Fawzy M, Afify M, Youssef YI. Pathological identification of egyptian local velogenic newcastle disease virus genotype VIII d in layer chickens. *Adv. Anim. Vet. Sci*. 2021;9(12):2054-2061.
  36. Shadood HM, Najem HA. Clinical, pathological and molecular study of Newcastle disease in layers farms in Basrah, Iraq. *Basrah Journal of Veterinary Research*; c2021. p. 20(1).
  37. Cattoli G, Susta L, Terregino C, Brown C. Newcastle disease: a review of field recognition and current methods of laboratory detection. *Journal of veterinary diagnostic investigation*. 2011 Jul;23(4):637-656.
  38. Brown CC, Sullivan L, Dufour-Zavala L, Kulkarni A, Williams S, Susta L, *et al.* Comparing presence of avian paramyxovirus-1 through immunohistochemistry in tracheas of experimentally and naturally infected chickens. *Avian diseases*. 2013 Mar;57(1):36-40.
  39. Anis Z, Morita T, Azuma K, Ito H, Ito T, Shimada A. Comparative study on the pathogenesis of the generated 9a5b Newcastle disease virus mutant isolate between chickens and waterfowl. *Veterinary pathology*. 2013 Jul;50(4):638-647.
  40. Eze CP, Okoye JO, Ogbonna IO, Ezema WS, Eze DC,

- Okwor EC, *et al.* Comparative study of the pathology and pathogenesis of a local velogenic Newcastle disease virus infection in ducks and chickens. *International Journal of Poultry Science*. 2014 Jan;13(1):52.
41. Ansori ANM, Kusala MKJ, Nidom Revianny, Indrasari Setyarina, *et al.* Pathological and molecular characterization of new castle disease virus isolated from *Gallus gallus* in Java, Indonesia. *Indian Journal of animal research*; c2021. 10.18805/ijar.b-1301: 1-6
  42. Cheville NF, Beard CW, Heminover JA. Comparative Cytopathology of Newcastle Disease Virus: Use of Ferritin-Labeled Antibody on Allantoic and Intestinal Epithelium. *Veterinary pathology*. 1972 Jan;9(1):38-52.
  43. Merz DC, Scheid AN, Choppin PW. Importance of antibodies to the fusion glycoprotein of paramyxoviruses in the prevention of spread of infection. *The Journal of experimental medicine*. 1980 Feb;151(2):275-88.
  44. Munir M, Linde AM, Zohari S, Stahl K, Baule C, Engström B, M Renstrom LH, *et al.* Whole genome sequencing and characterization of a virulent Newcastle disease virus isolated from an outbreak in Sweden. *Virus Genes*. 2011 Oct;43(2):261-71.
  45. Oldoni I, Brown CC, King DJ, Samal S, Seal BS. The use of in situ hybridization and immunohistochemistry to study the pathogenesis of various Newcastle disease virus strains and recombinants in embryonated chicken eggs. *Microbial pathogenesis*. 2005 Sep;39(3):69-75.
  46. Kant A, Koch G, Van Roozelaar DJ, Balk F, Huurne AT. Differentiation of virulent and non-virulent strains of Newcastle disease virus within 24 hours by polymerase chain reaction. *Avian pathology*. 1997 Dec;26(4):837-849.
  47. Gowthaman V, Singh SD, Dhama K, Srinivasan P, Saravanan S, Murthy TR, *et al.* Molecular survey of respiratory and immunosuppressive pathogens associated with low pathogenic avian influenza H9N2 subtype and virulent Newcastle disease viruses in commercial chicken flocks. *The Journal of Poultry Science*. 2017;54(2):179-184.
  48. Ananth R, Kirubaharan JJ, Priyadarshini ML, Albert A. Isolation of Newcastle disease viruses of high virulence in unvaccinated healthy village chickens in south India. *International Journal of Poultry Science*. 2008;7(4):368-373.