



ISSN (E): 2277-7695  
ISSN (P): 2349-8242  
NAAS Rating: 5.23  
TPI 2022; SP-11(7): 810-812  
© 2022 TPI  
[www.thepharmajournal.com](http://www.thepharmajournal.com)  
Received: 23-05-2022  
Accepted: 26-06-2022

#### Pravin Bano

Department of Veterinary Pathology, College of Veterinary and Animal Sciences, Rajasthan University of Veterinary and Animal Sciences, Bikaner, Rajasthan, India

#### H Dadhich

Department of Veterinary Pathology, College of Veterinary and Animal Sciences, Rajasthan University of Veterinary and Animal Sciences, Bikaner, Rajasthan, India

#### R Mohta

Department of Livestock Management, College of Veterinary and Animal Sciences, Rajasthan University of Veterinary and Animal Sciences, Bikaner, Rajasthan, India

#### M Mehra

Department of Veterinary Pathology, College of Veterinary and Animal Sciences, Rajasthan University of Veterinary and Animal Sciences, Bikaner, Rajasthan, India

#### Corresponding Author

#### Pravin Bano

Department of Veterinary Pathology, College of Veterinary and Animal Sciences, Rajasthan University of Veterinary and Animal Sciences, Bikaner, Rajasthan, India

## Occurrence and pathology of sarcocystosis in heart of sheep (*Ovis aries*)

Pravin Bano, H Dadhich, R Mohta and M Mehra

### Abstract

The present study was undertaken to elucidate the occurrence and pathology of sarcocystosis in sheep. A total 587 samples of cardiovascular system, irrespective of age, breed and sex were examined. Out of these, 147 specimens of heart, suspected for pathological abnormalities, were processed for histopathological examination. Sarcocystosis was recorded in 68 cases. The occurrence of this condition was recorded as 46.26 per cent. On microscopic examination presence of plenty of Sarcocysts was recorded throughout the myocytes. The cysts were of varying size and shapes. Presence of single and multiple cysts, ruptured cysts between muscle cells with necrosis was also recorded. An elongated ruptured cyst in myocardium with bradizoites was also found. On special stain of the myocardium showed red coloured Sarcocysts (Periodic Acid Schiff).

**Keywords:** Sheep, heart, sarcocystosis, histopathology

### Introduction

Sheep represent important part of world livestock industry. Sheep (*Ovis aries*) is one of the oldest animals in the world, which was domesticated by man. Sheep had originated from their ancestors *Ovis orientalis* and *Ovis vignei* (Ensminger, 1970)<sup>[2]</sup> and plays important role in livestock farming industry in the rural and urban areas of world as well as in India. The total livestock population in the country is 535.78 Million (20<sup>th</sup> livestock census). The total population of sheep in India is 74.26 Million, with an increase by 14.1 per cent over previous census (20<sup>th</sup> Livestock census). Sheep contribute to the tune of 13.87 per cent to the total livestock population of the country. According to 20<sup>th</sup> livestock census, indigenous or non-descript sheep population is 70.17 Millions (94.49%) while exotic or crossbred sheep population is 4.09 Millions (5.51%). Rajasthan with 7.9 million sheep population is the 4<sup>th</sup> largest sheep rearing state of the country (20<sup>th</sup> livestock census).

The cardiovascular system is responsible for circulation of oxygenated and deoxygenated blood (pure and impure blood). It also helps in transporting various nutrients (amino acids, electrolytes and sugar) and removing gaseous wastes from the body. Various endocrine hormones, excretory products are also transported by cardiovascular system. Therefore it becomes pertinent to study the cardiac affection in sheep. The present study was carried out for the study of occurrence and pathology of sarcocystosis in heart of sheep.

### Materials and Methods

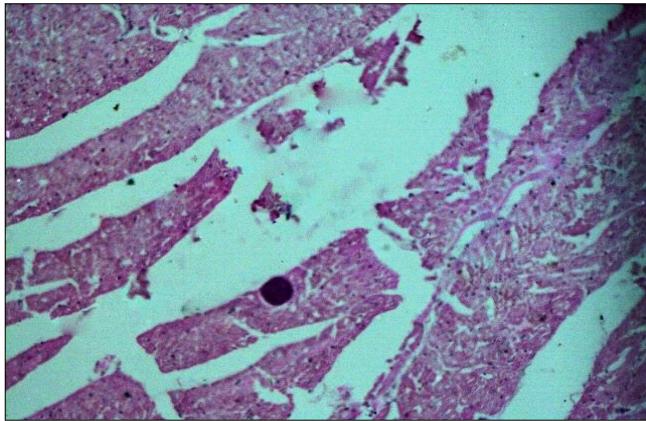
In the present study, a total of 587 samples of cardiovascular system of sheep were examined grossly for pathological conditions. Out of these, 147 samples of heart, showing gross lesions, were collected in 10 per cent formal saline and processed for histo-pathological examination. Processing of tissues was done by paraffin embedding using acetone and benzene technique (Lillie, 1965)<sup>[7]</sup>. The tissue sections of 4-6 micron thickness were cut with help of hand operated microtome and stained as per haematoxylin and eosin staining method (Luna, 1968)<sup>[9]</sup>.

### Results and Discussion

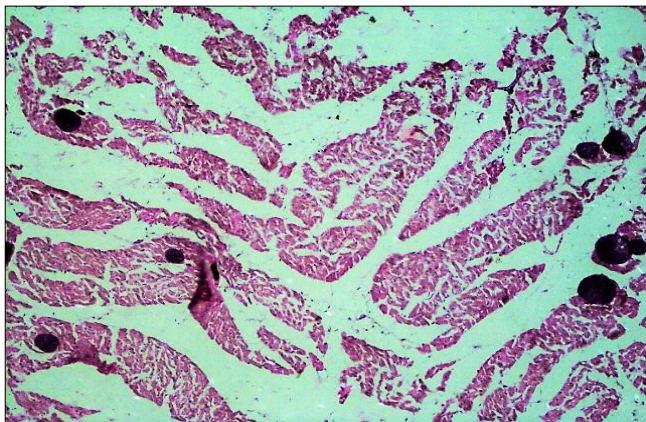
The incidence of sarcocystosis in heart of sheep in the present study was recorded as 46.26 per cent. This finding is in close approximation to incidence recorded by Latif *et al.* (2013)<sup>[6]</sup> and slight higher incidence 52.51 per cent was reported by Hui Dong *et al.* (2018)<sup>[4]</sup>. Extremely higher incidence 100 per cent was recorded by More *et al.* (2008)<sup>[10]</sup>.

Grossly, presence of Sarcocyst in heart muscles was not observed. On microscopic examination presence of plenty of Sarcocysts was recorded throughout the myocytes.

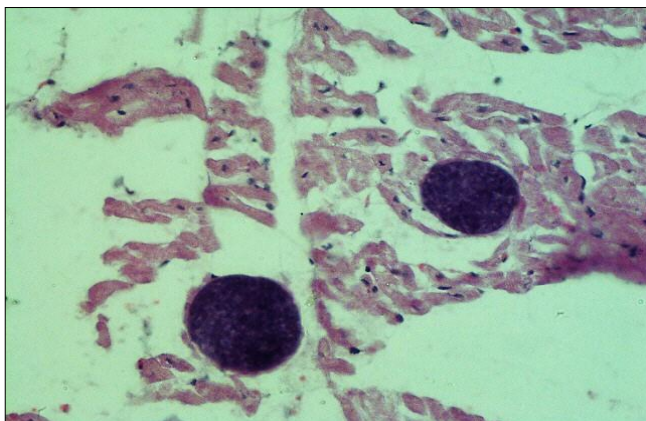
The cysts were of varying size and shapes (oval, round and elongated) (Fig.1). Presence of single and multiple cysts (Fig.2 and 3), ruptured cysts between muscle cells with necrosis (Fig.4) was recorded. The microscopic findings of sarcocystosis such as presence of cysts between the muscle bundles and fibers, different shaped and sized cysts were also observed. These findings are in close approximation with earlier reports of Jensen *et al.* (1986) [5], Silva *et al.* (2002) [11], Hong *et al.* (2015) [3], Alasonyalilar-demirer *et al.* (2016) [1], Tiwari *et al.* (2018) [13] and Sudan *et al.* (2019) [12]. An elongated ruptured cyst in myocardium with bradyzoites (Fig.5) was found. On special stain the myocardium showed red coloured Sarcocysts (Periodic Acid Schiff) (Fig.6).



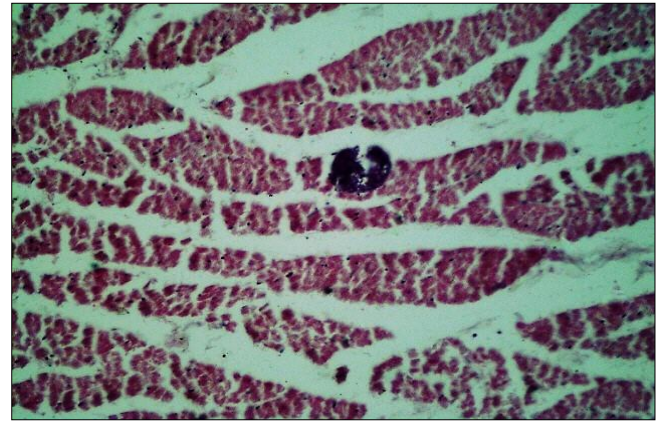
**Fig 1:** Microphotograph of heart of sheep myocardium showing an oval shaped Sarcocyst in myocardium. (H&E, 100X.)



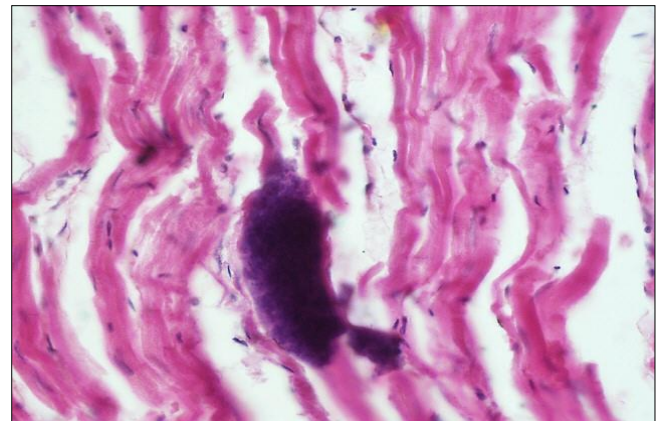
**Fig 2:** Microphotograph of myocardium of heart of sheep showing multiple Sarcocyst between the muscle cells. (H&E, 100X.)



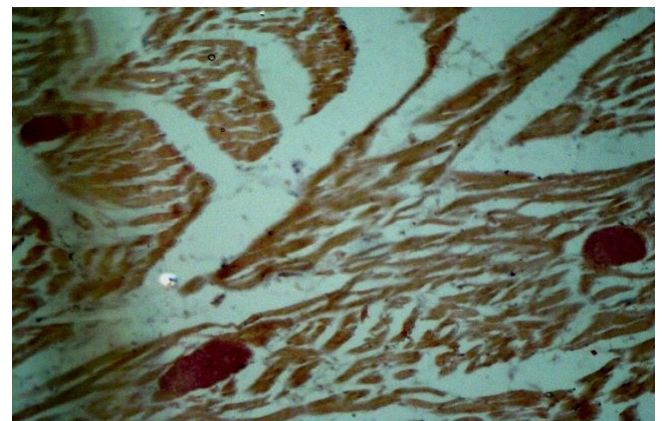
**Fig 3:** Microphotograph of heart myocardium of sheep showing oval shaped Sarcocysts with bradyzoites. (H&E, 200X.)



**Fig 4:** Microphotograph of myocardium of heart of sheep showing necrosed myocardial cells along with ruptured cyst. (H&E, 100X.)



**Fig 5:** Microphotograph of heart of sheep showing elongated ruptured Sarcocyst in myocardium. (H&E, 400X.)



**Fig 6:** Microphotograph of special stain of myocardium of heart of sheep showing red coloured Sarcocysts. (Periodic Acid Schiff, 200X.)

**Conclusion**

It is concluded that the Sarcocystosis is pathological abnormality in domestic animals resulting in weakness of animal with poor performance and leading to economic loss to the rural and urban farmer.

**Acknowledgement**

We acknowledge the support and facilities provided by faculty of the department of Veterinary Pathology and Dean, College of Veterinary and Animal Science, Bikaner for present research work.

## References

1. Alasonyalilar-Demirer A, Mufit Kahraman M, Akkoç A, Pelin Erturkuner S, Guzel EE, Kul O, *et al.* Meningoencephalitis caused by pathogenic *Sarcocystis* species in a naturally infected sheep in Turkey. *Tierärztliche Praxis Großtiere* 1/2017, 2016.
2. Ensminger ME. *Sheep and Wool Science* (4<sup>th</sup> Edn.). Danville Illinois. The Interstate Printers and publishers, 1970.
3. Hong EJ, Sim C, Chae JS, Kim HC, Park J, Choi KS, *et al.* Ultrastructural and molecular identification of *Sarcocystis tenella* (Protozoa, Apicomplexa) in naturally infected Korean native goats. *Veterinari Medicina*. 2015;61(7):374-381.
4. Hui Dong RS, Wang Y, Tong Z, Zhang L, Yang Y, Junjie H. *Sarcocystis* species in wild and domestic sheep (*Ovis ammon* and *Ovis aries*) from China. *BMC Veterinary Research*, 2018, 2-7.
5. Jensen K, Alexander AF, Dahlgren RR, Jellery W. Eosinophilic myositis and muscular *Sarcocystosis* in the carcasses of slaughtered cattle and lambs. *American Journal of Veterinary Research*. 1986;43:567-593.
6. Latif B, Vellayan S, Heo CC, Kutty K, Omar M, Abdullah E, *et al.* High prevalence of muscular *sarcocystosis* in cattle and water buffaloes from Selangor, Malaysia. *Tropical Biomedicine*. 2013;30(4):699-705.
7. Lille RO. *Histopathologic technique and practical histochemistry*. McGraw Hill Book Co. New York and London, 1965.
8. *Livestock census, 20<sup>th</sup>. Basic Animal Husbandry Statistics*. Department of Animal Husbandry, Dairying & Fisheries, Govt. of India, 2019.
9. Luna LG. *Manual of Histological Staining Methods of the Armed Forces Institute of Pathology*, 1968.
10. More G, Basso W, Bacigalupe D, Venturini MC, Venturini L. Diagnosis of *Sarcocystis cruzi*, *Neospora caninum* and *Toxoplasma gondii* infections in cattle. *Parasitology Research*. 2008;102(4):671-675.
11. Silva NSRD, Rodrigues RJD, Araujo FAPD, Beck C, Olicheski AT. Detection of bovine *Sarcocystis cruzi* cysts in cardiac muscles: a new technique of concentration for diagnostic. *Acta Scientiae Veterinariae*. 2002;30(2):127-129.
12. Sudan V, Kumar R, Shanker D, Paliwal S. First report of molecular characterization and phylogenetic analysis of *Sarcocystis tenella* from India. *Parasitology*, 2019.
13. Tiwari AN, Jakhar KK, Sharma V, Jangir BL. Pathomorphological studies in goats effected with gastrointestinal tract disorders. *The Pharma Innovation Journal*. 2018;7(3):157-160.