



ISSN (E): 2277-7695
ISSN (P): 2349-8242
NAAS Rating: 5.23
TPI 2022; SP-11(7): 785-787
© 2022 TPI
www.thepharmajournal.com
Received: 01-04-2022
Accepted: 04-05-2022

Krishna Nath MR

M.V.Sc. Scholar, Department of Veterinary Clinical Medicine, Ethics and Jurisprudence, College of Veterinary and Animal Sciences, Mannuthy, Thrissur, Kerala, India

Madhavan Unny N

Professor, Department of Veterinary Clinical Medicine, Ethics and Jurisprudence, College of Veterinary and Animal Sciences, Mannuthy, Thrissur, Kerala, India

Usha Narayana Pillai

Professor and Head, Department of Veterinary Clinical Medicine, Ethics and Jurisprudence, College of Veterinary and Animal Sciences, Mannuthy, Thrissur, Kerala, India

Corresponding Author

Krishna Nath MR

MVSc Scholar, Department of Veterinary Clinical Medicine, Ethics and Jurisprudence, College of Veterinary and Animal Sciences, Mannuthy, Thrissur, Kerala, India

Successful management of demodicosis in a doberman pup using fluralaner

Krishna Nath MR, Madhavan Unny N and Usha Narayana Pillai

Abstract

Demodicosis is a non-contagious skin disease of dogs. The diagnosis is often easy as the mites can be easily demonstrated in deep skin scrapings, but the successful outcome depends on many factors including pet immunity and owner compliance, thus making the treatment challenging. Fluralaner, an isoxazoline compound previously used as an acaricide and insecticide is now found effective for demodicosis also. In the present case, a single administration of fluralaner orally along with antibiotics and omega fatty acid supplementation was found effective in the complete remission of skin lesions associated with demodicosis.

Keywords: Demodicosis, folliculitis, fluralaner

Introduction

Demodicosis is an inflammatory skin disease caused by any of the three identified demodex mites, *Demodex canis*, *D. injai* or *D. cornei* in dogs, eventhough the former one is frequently seen in clinical practice (Zhou *et al.*, 2020) [8]. Mueller *et al.* (2020) [5] stated that demodex mites are normal inhabitants in the canine integumentary system and they proliferate when the host immunity is impaired. Koch (2017) [4] classified demodicosis into juvenile or adult form based on the time of onset and as localized or generalized form based on the nature and extend of lesions. Drugs such as amitraz, ivermectin or lime sulphur dips has been used with varying success rates but these may require prolonged duration of treatment and frequent follow ups. In the present scenario, protocols that minimize the course and side effects of therapy along with ensuring complete remission of the disease is encouraged. The case report suggests a novel therapeutic approach to demodicosis using an isoxazoline compound, fluralaner.

Case History

A three month old female Doberman pup was presented to University Veterinary Hospital, Mannuthy with severe folliculitis (Fig.1), dermatitis and exudative lesions over the face, body and limbs (Fig.2). The condition started as localized skin lesions on forehead and limbs that worsened over a period of three weeks. The lesions were suggestive of mange infection and skin scrapings were collected for laboratory examination. Microscopic examination of the deep skin scrapings revealed the presence of *Demodex canis* mites. Based on the distribution of lesions and laboratory finding, the condition was diagnosed as generalized, juvenile onset canine demodicosis.

Treatment

Taking into consideration the owner's convenience and also the risk of toxicity associated with improper usage of conventional drugs like amitraz to puppies, it was decided to initiate therapy using isoxazoline compounds. The pup was given fluralaner chewable tablet (Tab. Bravecto) @ 35 mg/kg once. Since secondary bacterial infection was evident on clinical examination, suspension cephalexin @ 15 mg/kg twice daily was added along with omega fatty acid supplementation (Syrup Furglow). More than 50 per cent clinical cure was noticed by week four (Fig.3), but deep skin scrapings examination was positive for *D. canis*. Antibiotic therapy was continued for two more weeks as folliculitis was persisting. Along with oral fatty acids, protein supplementation (B Protein powder) was added from week four. Even though skin scraping showed *D. canis* by week eight, the lesions were confined to lateral aspect of thigh, elbow joints and ventral neck (Fig.4). Consecutive two deep skin scraping examination from different sites done four weeks apart on week twelve and week sixteen showed complete parasitological cure (Fig.5).

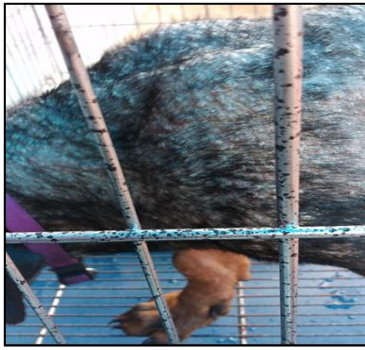

Fig 1: Day 1: Folliculitis and alopecia Tab. Bravecto (250 mg) was given



Fig 2: Day 1: Lesions suggestive of generalised demodicosis

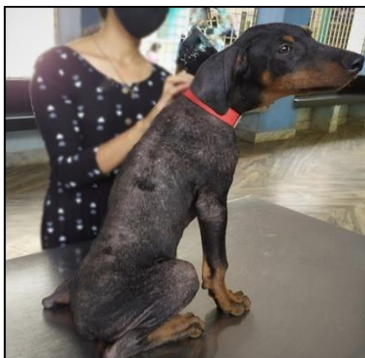

Fig 3: Week 4: Hair regrowth and reduction in intensity of lesion



Fig 4: Week 8: Lesions limited to thigh and elbow joints

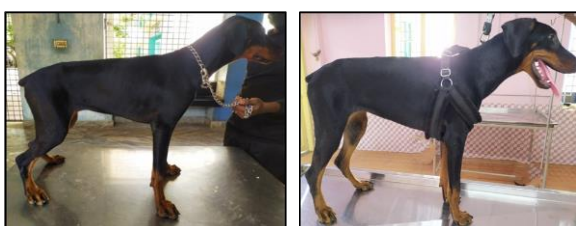


Fig 5: Week 12 & 16: Complete remission of skin lesions. Deep skin scraping examination was negative for mites.

Discussion

Demodectic mange is a severe parasitic dermatopathy often encountered in immunocompromised animals either due to genetic inheritance (juvenile onset) or due to an underlying disease (adult onset) (Koch, 2017) ^[4]. The lesions may begin as non inflammatory alopecia progressing to inflammatory dermatitis that may or may not turn into a crusty lesion. In severe conditions as in the present case, folliculitis and papules may develop along with secondary bacterial infection. There may be erythematous and ulcerative type lesions giving the characteristic 'red mange' appearance (Balima, 2020) ^[1]. Microscopical demonstration of demodex organisms in deep skin scrapings can be considered a confirmatory diagnosis. Mueller *et al.* (2020) ^[5] demonstrated that skin scrapings should be taken deep enough along with intermittent squeezing of skin until capillary bleeding is noticed so that enough mites are obtained. Examination of deep skin scraping is considered the diagnostic tool of choice because of the ease and accuracy. Other methods of diagnosis include trichograms, tape strips and histopathology of affected skin (Mueller *et al.*, 2020) ^[5]. Balima (2020) ^[1] stated that a multidrug therapeutic approach to demodicosis using macrocyclic lactones such as ivermectin, milbemycin oxime, doramectin or moxidectin along with amitraz dips were routinely followed in clinical practice since a long time. Though the outcome with regard to these drugs are satisfactory, the multiple dosing over the long treatment period and frequent veterinary consultation often makes the client impatient. In the present case oral chewable tablet, Bravecto was selected for the treatment. The active ingredient of Tab. Bravecto is fluralaner which is a long acting systemic insecticide and acaricide coming under isoxazoline group (Burgess *et al.*, 2020) ^[2]. Isoxazoline compounds were introduced to the veterinary market in 2013 and were directed at the prevention and treatment of flea and tick infestations in dogs. Recently, fluralaner was found effective for the treatment of generalised canine demodicosis (Nam *et al.*, 2021) ^[6]. A single oral dose of fluralaner was found effective for three months in dogs. Hoshino *et al.* (2021) ^[3] described that fluralaner worked by killing fleas and ticks by selective inhibition of arthropod chlorine channels gated by γ -aminobutyric acid and L-glutamic acid. With the single administration, a gradual reduction in both parasitemia and demodectic lesions were noticed in the present case. Koch (2017) ^[4] emphasized that identifying and initiating antibiotic therapy for secondary pyoderma was important for the successful treatment of demodicosis. As stated by Petersen *et al.* (2020) ^[7], the therapeutic dose range of 25- 56 mg fluralaner per kg bodyweight offered a wide margin of safety and in the present case, a 250 mg tablet was given to the dog (@35 mg/kg). Nam *et al.* (2021) ^[6] also reported absence of any adverse effects during the course of treatment suggestive of the high tolerance level of drug. In the present study, single administration of fluralaner was found to be effective in the management of canine generalized demodicosis.

References

1. Balima SN. Therapeutic management of demodicosis in a dog. *Pharma Innov.* 2020;9:479-480.
2. Burgess ER, Geden CJ, Lohmeyer KH, King BH, Machtinger ET, Scott JG. Toxicity of fluralaner, a companion animal insecticide, relative to industry-leading agricultural insecticides against resistant and susceptible strains of filth flies. *Sci. Rep.* 2020;10:11166.

3. Hoshino T, Akita T, Sugeno A, Okamura T, Machida Y, Nagata M. Long-term follow-up of a single dose of fluralaner in nine dogs with demodicosis. *Vet. Dermatol.* 2021;32:368-e102.
4. Koch SN. Updates on the management of canine demodicosis. *Today's Vet. Pract.* 2017;7:77-85.
5. Mueller RS., Rosenkrantz W, Bensignor E, Karaś-Tęcza J, Paterson T, Shipstone MA. Diagnosis and treatment of demodicosis in dogs and cats: Clinical consensus guidelines of the World Association for Veterinary Dermatology. *Vet. Dermatol.* 2020;3:5-27.
6. Nam H, Yun T, Koo Y, Chae Y, Lee D, Park J, *et al.* Oral fluralaner treatment in a dog with desperate demodicosis: a case report. *J Vet. Clin.* 2021;38:169-173.
7. Petersen I, Chiummo R, Zschiesche E, Karas-Tecza J, Rapti D, Roepke R, *et al.* European field assessment of the efficacy of fluralaner (Bravecto®) chewable and spot-on formulations for treatment of dogs with generalized demodicosis. *Parasit. Vectors.* 2020;13:304.
8. Zhou X, Hohman A, Hsu WH. Review of extralabel use of isoxazolines for treatment of demodicosis in dogs and cats. *J Am. Vet. Med. Assoc.* 2020;256:1342-1346.