The Pharma Innovation Journal 2022; SP-11(11): 52-56

www.ThePharmaJournal.com

The Pharma Innovation

ISSN (E): 2277-7695
ISSN (P): 2349-8242
NAAS Rating: 5.23
TPI 2022; SP-11(11): 52-56

www.thepharmajournal.com
Received: 25-09-2022
Accepted: 29-10-2022

Dr. Dhilleswara Rao S
Assistant Professor & Head, Department of Veterinary Anatomy, College of Veterinary Science, Sri Venkateswara Veterinary University, Andhra Pradesh, India

Dr. Jagapathi Ramayya P
Professor & Technical Officer to VC, Sri Venkateswara Veterinary University, Tirupati, Andhra Pradesh, India

Dr. Santhi Lakshmi M
Department of Veterinary Anatomy, College of Veterinary Science, Sri Venkateswara Veterinary University, Andhra Pradesh, India

Dr. Suresh Kumar RV
Department of Veterinary Surgery and Rdiology, College of Veterinary Science, Sri Venkateswara Veterinary University, Andhra Pradesh, India

Dr. Rambabu Naik B
Department of Veterinary Physiology, College of Veterinary Science, Sri Venkateswara Veterinary University, Andhra Pradesh, India

Corresponding Author:
Dr. Dhilleswara Rao S
Assistant Professor & Head, Department of Veterinary Anatomy, College of Veterinary Science, Sri Venkateswara Veterinary University, Andhra Pradesh, India

Comparative microscopic studies on exocrine portion of pancreas in domestic animals

Dr. Dhilleswara Rao S, Dr. Jagapathi Ramayya P, Dr. Santhi Lakshmi M, Dr. Suresh Kumar RV and Dr. Rambabu Naik B

Abstract
The pancreas of domestic animals was an example for exo and endocrine gland. It is a soft, encapsulated, lobulated gland and covered by a thick connective tissue capsule in buffalo and pig. The capsule was made up of predominantly dense irregular collagen fibres, few reticular and elastic fibres and blood vessels while capsule of pig consisted of adipose tissue in addition to connective tissue fibres. The average thickness of capsule was 30.05 to 98.62 µm in buffalo, 20.27 to 44.10 µm in pig, 18.20 to 25.64 µm in sheep, 20.27 to 44.10 µm in goat and 13.28 to 40.10 µm in dog.
The acini were round to oval in buffalo and sheep, but in goat, dog and pig the acini were in variable shapes i.e round, oval, irregular and few elongated in shape. The average diameter of the acini in buffalo was 20 to 60 µm, 20 to 40 µm in sheep, 20 to 40 µm in goat, 20 to 30 µm in dog and 35 to 50 µm in pigs. Each acinar cell possessed distinct basal zone and an apical zone in buffalo, sheep, goat, dog and pig. The presence of two or three centroacinar cells were noted in the lumen of the acini in sheep, goat, dog and pig but only single centroacinar cell was noted in buffalo. The distinct periacinar and periductal nerve plexus were observed in buffalo, sheep, goat, dog and pig and many neurons were also observed as isolated cells and they aggregated to form small and large ganglia (pancreatic ganglia) in buffalo, sheep and goat between the acini close to the islets in pancreas. These ganglia consisted of large multipolar neurons possessed eccentric nucleus and were surrounded by collagen and reticular fibres and the duct system of the exocrine pancreas consisted of small, medium and large ducts i.e intercalated, intralobular and interlobular ducts respectively in buffalo, sheep, goat, dog and pig.

Keywords: Pancreas, exocrine portion, zymogen granules, centro-acinar cells

Introduction
The parenchyma of pancreas is divided into distinct lobes and lobules by a connective tissue septa and each lobule is consisted of several secretory units called 'acini' and various sizes of ducts viz., intercalated, intralobular, interlobular and main pancreatic ducts in domestic animals (Dellmann and Eurell, 1998) [5]. The acini contained a small lumen and were lined by pyramidal cells with spherical nucleus at the basal region. The exocrine component was far larger in domestic animals Nickel *et al.* 1979 [16], Dellmann and Eurell, (1998) [5] and Konig and Leibich (2004) [13]. But detailed comparative information of microscopic structure on exocrine portion of pancreas of domestic animals is scarce. Hence, the present study has been undertaken.

Materials and Methods
A total of 15 adult buffalo, 19 sheep, 18 goats, 9 dogs and 17 pigs of either sex were utilised for present study. The tissue samples of pancreas were collected immediately after their slaughter at municipal slaughter house, Proddatur and Tirupati whereas pancreas of pigs were collected from AICRP on pigs, Tirupati and pancreas of dog were collected under willed animal body programme from Veterinary Clinical Complex, College of Veterinary Science, Proddatur and Tirupati. The tissue samples of pancreas were taken at different regions of pancreas i.e body, right lobe and left lobe. Then the tissue samples were fixed in 10% Neutral buffered formalin and Bouin's fluid. The fixed tissues were subjected to routine tissue processing and paraffin blocks and sections of 4-5 µm thickness and the sections were stained subjected to routine as well as special histological staining methods (Bancroft and Gamble, 2008) [4].

Results and Discussion

The pancreas of buffalo and pig was covered by a thick connective tissue capsule. It consisted of predominantly dense irregular collagen fibres and few reticular and elastic fibres and blood vessels while capsule of pig consisted of adipose tissue in addition to connective tissue fibres (Fig.1). The average thickness of capsule was 30.05 to 98.62 µm in buffalo, 20.27 to 44.10 µm in pig, 18.20 to 25.64 µm in sheep, 20.27 to 44.10 µm in goat and 13.28 to 40.10 µm in dog. According to Singh and Gupta (1995) [19] the thickness of capsule was 3.60 to 95.20 µm in buffalo and 40.41±22.67 µm in Indian donkey (Dhoolappa *et al.*, 2004) [6], whereas the capsule of sheep, goat and dog was indistinct and thin and made up of loose connective tissue with fine collagen and reticular fibres but no evidence of elastic fibres. The thin connective tissue septa extended into the parenchyma of the gland and divided it into several lobes and lobules in buffalo, sheep, goat, dog (Fig.2) and pig. It is in agreement with the observation of Nickel *et al.* (1979) [16], Dellmann and Eurell (1998) [5] and Aughey and Frye (2001) [3] in domestic animals, Hiratsuka *et al.* (1996) [10] in cattle, Rohankar *et al.* (2005) [17] in sheep, Jagapathi *et al.* (2012) [11] and Al-Saffar and Al-Zuhairy (2017) [2] in domestic cat. The connective tissue septa contained blood vessels, lymph vessels, interlobular ducts and the large number of collagen fibres were noted around the ducts, blood vessels and connective tissue septa (Fig.3).

The acini were round to oval in buffalo and sheep. It is in conformity with the findings of El-Sakhawy *et al.* (2016) [7] in buffalo and Al-Saffar and Al-Zuhairy (2017) [2] in domestic cat. But the acini were in variable shapes in goat, dog and pig i.e round, oval, irregular and few elongated in shape (Fig.4) as reported by Rohankar *et al.* (2005) [17] in sheep, (Dhoolappa *et al.* 2004) [6] in Indian donkey and Jagapathi *et al.* (2012) [11] in cat. The acini of pancreas were appeared in variable in sizes in buffalo, sheep, goat, dog and pig. connective tissue septa The average diameter of the acini in buffalo was 20 to 60 µm, 20 to 40 µm in sheep, 20 to 40 µm in goat, 20 to 30 µm in dog and 35 to 50 µm in pigs. Similarly, Rohankar *et al.* (2005) [17] noted different sizes of acini in sheep i.e small, intermediate and larger acini. The pancreatic acini were lined by single row of an irregular pyramidal epithelial cells rested on basement membrane in buffalo, sheep, goat, dog and pigs as reported by Hamza (2018) [9] in Indigenous Gazelle. Contrary to this, Aughey and Frye (2001) [3] reported tall columnar cells in domestic animals, whereas, Sreeranjini and Ashok (2016) [18] observed cuboidal to pyramidal cells in goats. The basement membrane of acini was made up of fine collagen and reticular fibres in buffalo (Fig.5), sheep, goat and dog, but in pigs it was composed of fine collagen and indistinct reticular fibres around the acini and large amount of adipose tissue was observed in the parenchyma (Fig.1).

The distinct nerve plexus was noted around the acini and ducts i.e periacinar and periductal nerve plexus respectively in buffalo, sheep, goat, dog (Fig.6) and pig. Similar findings by Ahmed *et al.* (2017) [1] in pancreas of rat. Further, many neurons were also observed as isolated cells and they aggregated to form small and large ganglia (pancreatic ganglia) in buffalo, sheep and goat between the acini close to the islets in pancreas. These ganglia consisted of large multipolar neurons possessed eccentric nucleus and were surrounded by collagen and reticular fibres**.** These results agreement with the findings of Ladukar and Pandit (1994) [14] noted large-sized parasympathetic ganglia in interlobular septa in buffalo. The large number of pacinian corpuscles were also noted in the interlobular connective tissue and they were categorized into small and large type corpuscles in buffalo, sheep, goat and dog. Whereas, the pacinian corpuscles were noted in the interlobular connective tissue and in the vicinity of wall of interlobular ducts in pigs, which were also encapsulated by fine collagen and reticular fibres (Fig.7). These results were in agreement with the findings of Dellmann and Eurell (1998) [5] in domestic animals and Jagapathi *et al.* (2012) [11] in pancreas of cat.

The acinar cells consisted of spherical to oval nucleus and located at the basal part of the cells in buffalo and pig as reported by Dellmann and Eurell (1998) [5] in animals, Meshram *et al.* (2001) [15] in goat and Rohankar *et al.* (2005) [17] in sheep. Whereas, the location of nucleus in acinar cells showed basal or parabasal position in case of sheep and goat. Similarly, Dhoolappa *et al.* (2004) [6] also observed basal or parabasal location of nucleus in acinar cells in Indian donkey. But in dog nucleus placed at different levels i.e mostly near the basal zone, but few at parabasal or central zone of the acinar cell and most acinar cells were uninucleated but occasionally some cells possessed two nuclei in buffalo, sheep, goat and dog, but pig consisted of uninucleated cells only. Each acinar cell possessed distinct a basal zone and an apical zone in buffalo, sheep, goat, dog and pig. The basal cytoplasm was intensely basophilic i.e towards the basement membrane due to presence of extensive rER, while apical zone was acidophilic i.e towards the lumen as it contained numerous zymogen granules (Fig.8). These results were in agreement with the findings of Dellmann and Eurell (1998) [5] in animals, Jagapathi *et al.* (2012) [11] in cats and El-Sakhawy *et al.* (2016) [7] in buffalo. Whereas, Dhoolappa *et al.* (2004) [6] opined that the zymogen granules density was variable and it depends on the activity of the acinar cells in Indian donkey.

In the present study, some of the ductular cells of intercalated ducts were invaginated into the lumen of the acinus and remained as centeroacniar cells in buffalo, sheep, goat, dog and pig (Fig.4). These cells were clearly demarcated from the acinar cells, being smaller than the acinar cells and they possessed few granules in sheep and goat. The centroacinar cells were usually single, but occasionally two or three cells were also present in sheep, goat, dog and pig. This finding was in agreement with the Karaca *et al.* (2014) [12] in cat while only single centroacinar cell was noted in buffalo.

The duct system of the exocrine pancreas consisted of small, medium and large ducts, i.e intercalated, intralobular and interlobular ducts respectively in buffalo, sheep, goat, dog and pig as reported by Dellmann and Eurell (1998) [5] in domestic animals. The intercalated ducts showed narrow lumen and lined by the flattened epithelial cells in buffalo, sheep, goat, dog and pig. The lamina propria was composed of fine collagen, reticular fibres and numerous smooth muscle fibres. They were continued in to intralobular ducts as reported by El-Sakhawy *et al.* (2016) [7] in buffalo. The intralobular ducts were continuation of the intercalated ducts within the lobules. The lumen of these ducts was regular and lined by single layered low columnar to simple cuboidal epithelium without goblet cells in buffalo and pig, but in sheep, goat and dog these ducts consisted of single layered cuboidal to low columnar epithelium with few goblet cells (Fig.3). Further, these ducts were surrounded by connective tissue fibres made up of collagen, reticular fibres, numerous smooth muscle fibres, few elastic fibres and fine blood capillaries. Similary, Dhoolappa *et al.* (2004) [6] in India donkeys and Al-Saffar and Al-Zuhairy (2017) [2] in cat. The large interlobular ducts were

present between the lobes within the connective tissue septa. These ducts showed large lumen and folded mucosa, which was lined by single layered tall columnar epithelium and no evidence of goblet cells in buffalo, dog and pig. Whereas, sheep and goat consisted of single layered tall columnar epithelium with numerous goblet cells. The secretory material accumulated in the apical portion of the epithelial cells along the luminal border like in buffalo and sheep. The lamina propria was thicker and composed with dense irregularly arranged collagen (Fig.3), fine reticular fibres and few elastic fibres. The small blood vessels, lymph vessels and numerous smooth muscle fibres were also observed in the vicinity of wall of larger ducts as reported by Eurell (2004) [8] in domestic animals. Finally, the large interlobular ducts from different parts of the pancreas were joined together and formed larger ducts and subsequently the main excretory duct of pancreas.

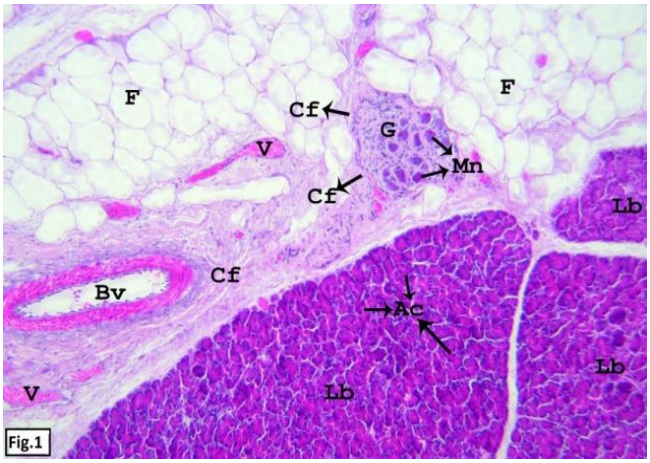

Fig 1: Photomicrograph of pancreas of pig showing large blood vessel, vein and ganglia along with adipose tissue.
H&E x 100
F- Adipose tissue, Bv- Blood vessel, V- Vein
Cf- Collagen fibers, Mn- Multipolar neuron
Ac- Acini, Lb- Lobule and G – Ganglion.

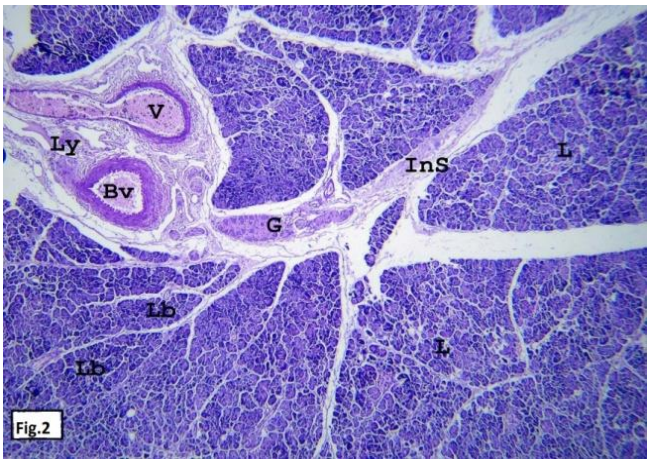

Fig 2: Photomicrograph of pancreas of dog showing large blood vessel, vein and ganglia.
H&E x 40
V- Vein, Ly- Lymphatic vessel, Bv- Blood vessel, G- Ganglion, L- Lobe, Lb- Lobule and InS- Interlobular septa

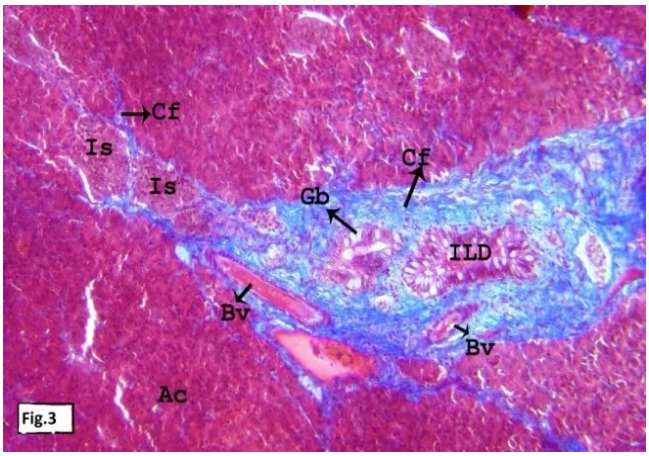

Fig 3: Photomicrograph of pancreas of sheep showing collagen fibres around the duct, blood vessels and islet of Langerhans.
Masson's Trichrome x 400
Is – Islets of Langerhans, Cf – Collagen fibres, Ac – Acini, Bv – Blood vessels, ILD – Interlobular duct and Gb – Goblet cells

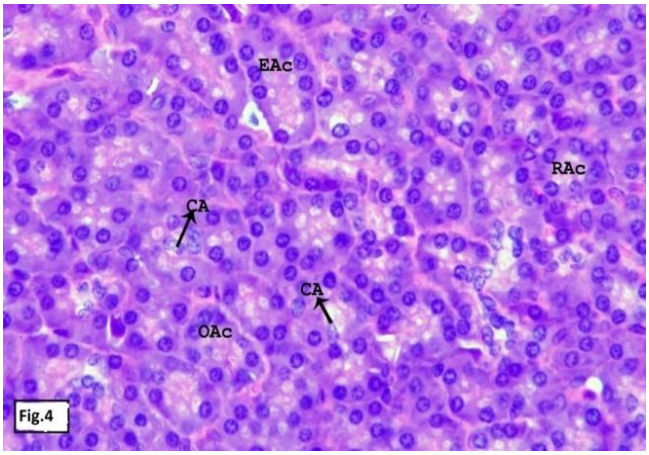

Fig 4: Photomicrograph of pancreas of goat showing different shapes of acini.
H& E x 400.
EAc – Elongated acini, OAc – Oval acini
RAc – Round acini and CA – Centroacinar cell

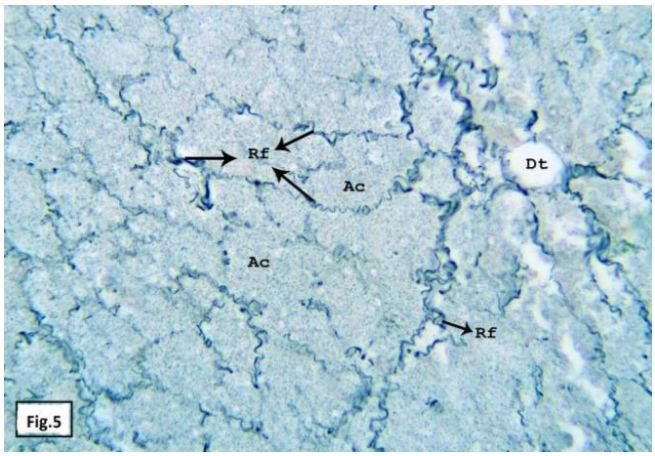

Fig 5: Photomicrograph of pancreas of buffalo showing reticular fibres around the acini and duct.
Wilder's x 400
Rf – Reticular fibres, Ac – Acini and Dt- Duct

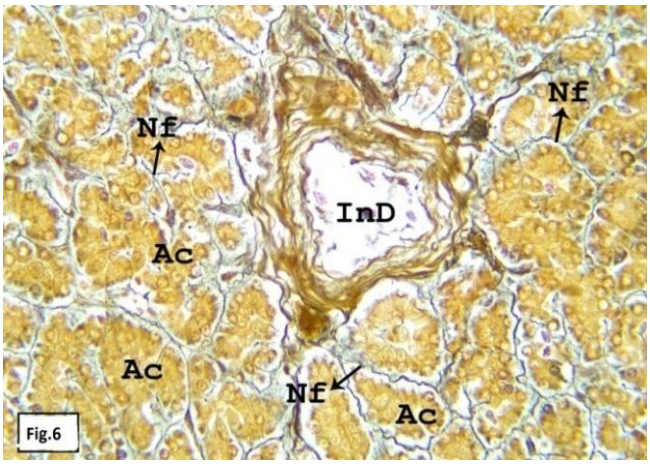

Fig 6: Photomicrograph of pancreas of dog showing nerve plexuses around the acini.
Beilschowsky x 400
Nf- Nerve fiber, Ac- Acini and InD- Large duct

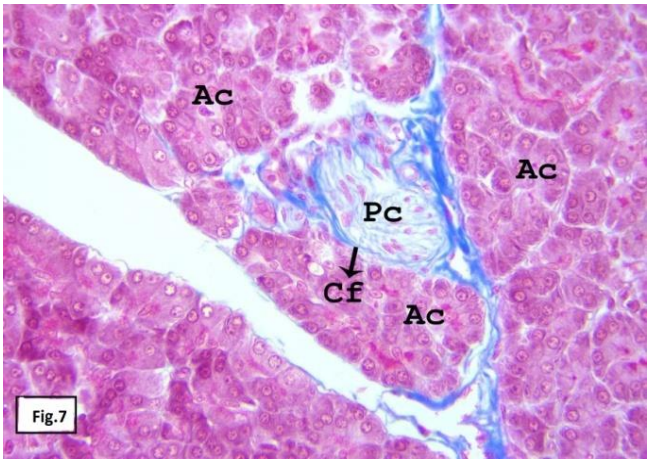

Fig 7: Photomicrograph of pancreas of dog showing Pacinian corpuscle.
Masson's Trichrome x 400
Ac- Acini, Pc- Pacinian corpuscle and
Cf- Collagen fibers

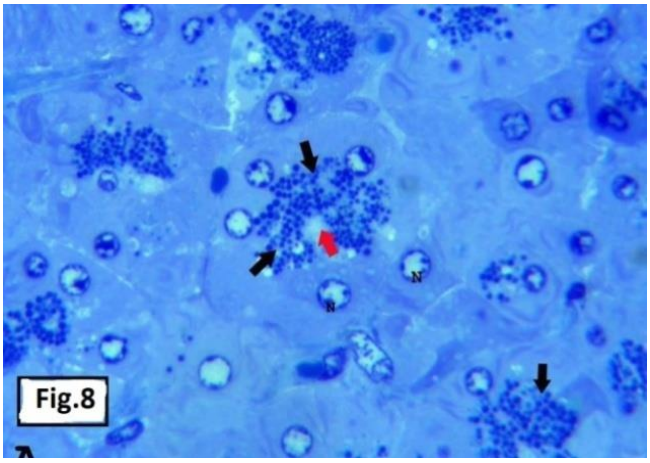

Fig 8: Photomicrograph of pancreas of buffalo showing zymogen granules in acini.
Toluidine blue x 1000.
Black arrow – Zymogen granules
Red arrow - Lumen

Conclusion

The pancreas was soft, encapsulated, lobulated and covered by a connective tissue capsule. Thickness of capsule is more in pancreas of buffalo than pig, sheep, goat and dog. The variable shapes of acini were noted in pancreas of goat and uninucleated acinar cells were observed only in pancreas of pigs.

References

1. Ahmed R, Jagapathi Ramayya P, Raju NKB, Suresh Kumar RV, Dhilleswara Rao S. Studies on intrinsic innervations and microvasculature of pancreas of albino rat, Indian Journal of Veterinary Anatomy. 2017;29(1):15-16.
2. Al-Saffar FJ, Al-Zuhairy MF. Postnatal developmental histomorphological and histochemical study of the pancreas in the domestic cat (Feliscatus), International Journal of Advanced Research. 2017;5(2):55-71.
3. Aughey E, Frye FL. Comparative Veterinary Histology. Manson Publishing. The Veterinary Press; c2001. p. 129-130.
4. Bancroft JD, Gamble M. Theory and Practice of Histological Techniques 6th edition, Churchill Livingstone Elsevier; c2008. p. 248-250.
5. Dellmann HD, Eurell JA. Textbook of Veterinary Histology. 5th edition, Philadelphia, Lippincott Williams and Wilkins; c1998. p. 199-200.
6. Dhoolappa M, Ashok P, Ramakarishna V, Gadre KM. Gross and histomorphology of pancreas in donkey, Indian Journal of Animal Science. 2004;74(9):926-929.
7. El-sakhawy MA, El-shamma M, Abdrabou M, Mekkawy AM. Some Histological studies on the exocrine pancreas of buffalo (*Bubalus bubalis*). International Journal of Biology, Pharmacy and Allied Science. 2016;5(6):1176-1184.
8. Eurell JAC. Veterinary Histology. Teton New Media Jackson, Wyoming; c2004 p. 36-37.
9. Hamza LO. Histological and histochemical characters of the pancreas in the adult indigenous Gazelle (*Gazella subgutturosa*). Indian Journal of Natural Sciences. 2018;8(48):13773-14011.
10. Hiratsuka T, Abe M, Takehana K, Iwasa K, Takeo Hiraga T, Kobayashi A. Immunohistochemical analysis of the endocrine cells in the pancreatic islets of cattle, Okajimas Folia Anatomica Japonica. 1996;72(6):285-296.
11. Jagapathi Ramayya P, Prasanth Babu A, Patki HS, Chandersekhara Rao TS. Anatomy of the pancreas of domestic cat, Indian Veterinary Journal. 2012;89(10):72-74.
12. Karaca T, Kara A, Simsek N, Uslu S, Tekiner D, Yoruk M. Immunohistochemical distribution of glucagon, insulin, somatostatin, gastrin and serotonin containing cells in the pancreas of the van cat, Turkish Journal of Veterinary and Animal Sciences. 2014;38:304-311.
13. Konig HE, Liebich HG. Veterinary anatomy of domestic mammals. Schattauer Newyork, 3rd edition; c2004. p. 340-342.
14. Ladukar ON, Pandit RV. Studies on neural ganglia and nerve cells in pancreas of buffalo, Indian Journal of Veterinary Anatomy. 1994;6(1):22-26.
15. Meshram BN, Dalvi RS, Bhamburkar SB, Banubakode, Nandeshwar NC. Histomorphological studies on caprine pancreas with reference to ageing, Indian Journal of Veterinary Anatomy. 2001;13(2):130-133.
16. Nickel R, Schummer A, Seiferle E. The viscera of the domestic mammals. 2nd Edition, Translation and Revision by W O Sack Verlag Paul Parey: Berlin and Hamburg;

c1979. P. 119-122, 136, 146, 179-180.
17. Rohankar BNS, Mamde CS, Ahar VD, Gangaram GR. Histological study of the pancreas in sheep (Ovis aries) M.V.Sc Thesis submitted to MAFS university, Nagapur; c2005.
18. Sreeranjini AR, Ashok N. Prenatal development of exocrine pancreas in cross bred goats: A histological study, International Journal of Anatomy Research. 2016;4(2) 2365-2371.
19. Woo SC, Ohara M, Torrie E, Singh JP, Gupta A. The SPLASH-2 programs: Characterization and methodological considerations. ACM SIGARCH computer architecture news. 1995 May 1;23(2):24-36.