



ISSN (E): 2277- 7695
ISSN (P): 2349-8242
NAAS Rating: 5.23
TPI 2021; SP-10(8): 218-222
© 2021 TPI

www.thepharmajournal.com

Received: 10-06-2021

Accepted: 12-07-2021

Poornima Gumasta

Department of Veterinary
Pathology, College of Veterinary
Science & A.H., Anjora, Durg,
Chhattisgarh, India

RC Ghosh

Department of Veterinary
Pathology, College of Veterinary
Science & A.H., Anjora, Durg,
Chhattisgarh, India

Shubhangi Argade

Department of Veterinary
Pathology, College of Veterinary
Science & A.H., Anjora, Durg,
Chhattisgarh, India

Sumit Satpaty

Department of Veterinary
Pathology, College of Veterinary
Science & A.H., Anjora, Durg,
Chhattisgarh, India

DK Jolhe

Department of Veterinary
Pathology, College of Veterinary
Science & A.H., Anjora, Durg,
Chhattisgarh, India

Padamveer Singh

Assistant Professor, Apex College
of VLDD, Haryana, India

Hemant Sahu

Department of Veterinary
Pathology, College of Veterinary
Science & A.H., Anjora, Durg,
Chhattisgarh, India

Charlee Porte

Department of Veterinary
Pathology, College of Veterinary
Science & A.H., Anjora, Durg,
Chhattisgarh, India

Corresponding Author

Poornima Gumasta

Department of Veterinary
Pathology, College of Veterinary
Science & A.H., Anjora, Durg,
Chhattisgarh, India

Occurrence of various disease conditions and their pathology in Kadaknath chickens

Poornima Gumasta, RC Ghosh, Shubhangi Argade, Sumit Satpaty, DK Jolhe, Padamveer Singh, Hemant Sahu and Charlee Porte

DOI: <https://doi.org/10.22271/tpi.2021.v10.i8Sd.7213>

Abstract

Kadaknath rearing is a profitable business because of its high-quality, nutritiously enriched meat. Diseases undeniably has influence to convert profits into losses. To manage the condition, it is vital to study the disease pattern of certain area along with their pathological aspect altogether. It helps to make an effective plan for prevention and control of diseases. Present paper targets the same point. This is the eleven months postmortem study in which we performed necropsy of total 421 Kadaknath chickens. Disease diagnosis has been made based on gross, microscopic lesions, cultural characteristics of the isolated microorganisms and by microscopic examination of intestine scraping. Pathological conditions that we recorded during the study period are as follows. Coccidiosis, enteritis, tapeworm infection, pneumonia and some cases with the indicative lesions of Newcastle disease.

Keywords: disease occurrence, gross pathology, histopathology, Kadaknath chickens

Introduction

In the last few decades, we have noticed a paradigm shift in the Indian poultry industry based on its structural and functional aspect. India ranks 7th in chicken meat, and 3rd in egg production in world. Data indicates the status of poultry farming in today's India; it is growing tremendously well. Kadaknath is a well-known, very much Indian (Desi) breed which is native of Madhya Pradesh. It is famous because of its nutritional rich and delicious meat quality. Similar criteria make this bird high in demand and high in cost which is a favourable business idea for farmers (Shahraki *et al.*, 2018; Singh, 2019) ^[1, 2].

Although Kadaknath is a desi breed proven to have more resistance and survivability than other commercial birds in the Indian conditions, pathological aspects in poultry farming cannot be ignored. This enormous progress can be very easily hampered by overlooking the various environmental factors, mismanagement practices and occurrence of various infectious diseases. Above conditions can lead to farmers in heavy economic loss by direct and indirect means (Parmar, 2003; Chakravarti *et al.*, 2018) ^[3, 4].

The increased demand of poultry meat and egg worldwide has led to intensive farming which has in turn, led to increased potential of disease occurrence. Severity of diseases differs organism to organism. Some creates high morbidity and other causes heavy mortality. Both are hazardous to poultry farmers and capable to cause heavy debt. Infections and mismanagement complete each other and creates destruction (Vijayalingam *et al.*, 2019) ^[5].

Some infections do not cause severe mortality but good enough to create long time illness in the poultry flock. Parasitic infections and avian mycoplasma infection are one of them. Some other are so much pathogenic that they are capable to kill whole flock in a period of sudden (e.g., avian influenza or bird plague). Poultry house mismanagement like, providing contaminated food and water, overcrowding, inappropriate temperature in poultry shed i.e., too hot &/too cold, deteriorate the condition (Hooda *et al.*, 2011; Chakravarti *et al.*, 2018; Dipti *et al.*, 2012; Vijayalingam *et al.*, 2019) ^[4, 5, 6, 7]. Present paper deliberating the presence of certain pathological conditions in the Kadaknath chickens of Chhattisgarh area and their pathology in detail.

Materials and Methods

Present work is a postmortem study that took around eleven months. Total of 421 dead Kadaknath chickens presented at the Department of Vety. Pathology, for necropsy from the different areas of Chhattisgarh.

Dead birds were subjected for detailed postmortem examination, to know the possible cause of death. All the gross changes recorded carefully during postmortem examination.

Tissue samples from the suspected cases has been collected and stored into 10% buffered formalin in order to study pathology in detail. Swabs also been taken from the cases of enteritis, which further streaked in Nutrient, McConkey and EMB agar for isolation of the suspected microorganism.

Tissue Samples preserved with formalin processed for histopathology by following protocol mentioned by Slaoui and Fiette (2011) [8]. Dehydration and clearing have been done by using acetone and benzene respectively. Afterwards, wax impregnation, blocking and section cutting at the thickness of 4micron carried out. Finally, Routine haematoxylin and eosin staining has been performed. For bacteriological Examination, collected swabs were incubated in nutrient broth overnight at 37^c. Next day, streaking performed in the MacConkey (Himedia, SM081), EMB (Himedia) and nutrient agar (Himedia M085) plates. Streaked plates were further incubated at 37^c for 24 hrs. Finally, colonies were stained by Gram stain (Himedia, K001) to know the morphology of organism (Cheesbrough, 2006) [9].

Results and Discussion

Various disease conditions that we have encounter in our study are as follows in the Table 1

Table 1: Occurrence of various disease conditions in Kadaknath chickens

S. No.	Pathological conditions	Number of dead birds (N/421)	Occurrence (%)
1	Coccidiosis	91	21.6%
2	Enteritis	72	17.1%
3	Worm infection	58	13.8%
4	Pneumonia	51	12.1%
5	Newcastle disease	11	2.6%

As showing in the table 1 coccidiosis recorded with highest occurrence (20.6%) and lesions indicative of newcastle disease were found only in 2.6% of the birds with lowest rate. Second highest pathological condition which we documented was enteritis with the occurrence rate of 17.1%. Moderate to severe worm infections we noted in our study in 13.8% cases. Likewise, pneumonia distinguished in 12.1% cases.

Our findings were in corroboration with Hooda *et al.* (2011) [6]. They reported diseases of digestive system with highest incidence rate as coccidiosis majorly affects the digestive system. Yadav, (2011) [10] described 31.66% mortality due to coccidiosis in Kadaknath Chickens. 5.52% and 4.59% incidence of *Escherichia coli* and coccidiosis respectively recorded by Abbas *et al.* (2015) [11]. Chakravarti *et al.* (2018) [4] found coccidiosis with highest incidence rate in their study entitled Incidence of various disease conditions in Kadaknath birds and their correlation with mortality rate.

Now we will discuss all the pathological conditions found in present study individually and in detail.

Coccidiosis: it is one of the deadliest protozoal disease that has its occurrence worldwide. In poultry it creates havoc and causes mortality and morbidity in high degree. In our study, grossly we observed thickening and ballooning of intestine along with moderate to severe haemorrhages on mucosa. Birds revealed pale mucous membrane in external examination. Caeca of few Kadaknath birds were also

distended due to filling of blood mixed cellular debris in the lumen of caeca. This further gets putrefied and produces gas which ultimately causes ballooning of the caeca and intestine. Cellular debris is nothing but damaged and decomposed intestinal mucosa that sloughed out and drops in the lumen, due to pathology created by *coccidial spp.* During its life cycle. We performed a rapid inspection by microscopic examination of intestinal scrapping. Positive samples of intestine (coccidial oocysts) were subjected for histopathology (Figure 1).

Microscopically, we noted deposition of various developmental stages of coccidia in the lamina propria of intestine. These oocysts were arranged as clusters form in abundance (Figure 2), showing a severe loss of absorptive surface of intestine. Other significant lesions were clubbing and attenuation of intestinal microvilli which eventually decreases the surface area for nutrient absorption. This causes malnutrition in chicken which is an undesirable trait to Kadaknath consumers. Few cases with severe infection revealed complete destruction of intestinal epithelium leaving submucosa exposed. Moderate haemorrhages and infiltration of heterophils and mononuclear cells in the intestine also appeared microscopically as important lesion.

Our results showed similarities with various researchers. Kaboudi *et al.* (2016) [12] observed dehydrated and pale carcasses along with ballooning and haemorrhages in intestinal mucosa in the coccidia positive cases of chickens. Adamu *et al.* (2013) [13], Sharma *et al.* (2015) [14] and Olabode *et al.* (2020) [15] discussed the microscopic changes in detail. They detected loss of epithelial tissues of the intestine, necrosis of submucosa, congestion of blood vessels, loss of villi, presence of clusters of oocysts in the lamina propria, disruption of mucosa, marked haemorrhage and necrosis of caecal mucosa. Massive deposition of inflammatory cells also been reported by them.

Enteritis: grossly we observed various forms of the enteritis in our study. We noticed hemorrhagic enteritis in the suspected cases of new castle disease (Figure 3). Other one was catarrhal enteritis with mild to moderate congestion. Major organism which we isolated from this type of enteritis was *E. coli*. We made this diagnosis based on cultural and staining characteristics of the isolated bacteria. It gave pink color colonies in McConkey agar plate (Figure 4) and metallic sheen in EMB agar. Furthermore, it took pink color (gram negative) in Gram's staining. Organisms appeared as clear rods in high power (1000X). In significant amount, we encounter with chronic catarrhal enteritis. These cases had severe parasitic infection (Figure 5). This type of enteritis we found in the cases of worm infections and coccidiosis.

Histopathological changes show resemblances with gross changes in terms of severity and type of enteritis. Cases with catarrhal enteritis showed increase goblet cell and mucous production. There were moderate inflammatory and necrotic changes observed in the intestinal lumen. Viral enteritis had severe deteriorating changes. In these cases, intestine revealed severe degenerative and necrotic changes along with marked hemorrhages and significant infiltration of mononuclear cells. Parasitic enteritis revealed moderate to complete sloughing of the absorptive surface of intestine. There was visible hemorrhages and infiltration seen noticed.

Our results showed significant similarities with Reid (1962) [16]; Chakravarti *et al.*, (2011) [17]; Khorrajyia *et al.*, (2015) [18] and Kaboudi *et al.* (2016) [12].

Tapeworm infection: this type of pathology is a clear indicative of mismanagement practices at flock. Unclean utensils, feed and water spoiled with infective excreta of the birds contains eggs of the parasite in enormous amount. Chickens gets food borne infection by taking eggs of the parasites. Grossly we recorded that intestine of the chickens were absolutely clogged and distended by large stout tape worm. Worms were around 15cm to 25cm long and covered (blocked) a large portion or the small intestine (Figure 5). The infected birds were in extremely emaciated condition and their keel bone were profoundly prominent (Figure 6). High grade mucosal thickening along with multiple petechial hemorrhages noticed in few cases (Figure 7). This might happen due to continuous irritation and destruction created by the parasite not only in the epithelial layer, but also in the submucosa of the intestine. All and all, it was a combine case of hemorrhagic and chronic catarrhal enteritis.

Microscopically, there was complete disruption of the epithelial lining observed along with severe hemorrhages. Debris made up of epithelial cells, fragment of etiological agent (parasite), blood and pus cells (neutrophils) deposits in the lumen of the intestine and made it distended. Further, they petrify and produces gases which causes ballooning of the intestine. In extreme cases it can rupture the intestine and causes death of the chicken due to toxemia. Heavy parasitic load also causes heavy economic losses to the farmers.

Our results showing relations with Jha (2019) [19]. They reported lesions like severe emaciation of the breast muscles with protrusion of the keel bone. Intestinal lumen (duodenum and jejunum) was severely filled with whitish large tape worms. Their anterior ends were firmly attached to the intestinal mucosa and dark red exudates (digested blood) was seen at the site of attachment. The duodenal mucosa was thickened and hyperemic showing chronic catarrhal enteritis and hemorrhagic enteritis. Bhowmik *et al.* (1982) [20], Saxena *et al.* (1998) [21] and Dipti *et al.* (2012) [7] also showed the similar findings.

Pneumonia: it is an inflammatory condition of lungs that targets the air sects of the single or both lungs. In our study we reported varying degree of pneumonic changes. Grossly, lungs of the Kadaknath chickens were red and brown to gray in color. Lungs were edematous and, in some cases, had deep marks of ribs on their surface due to inflammatory, edematous swelling (Figure 8). Trachea of the affected lungs showed moderate congestion to mild hemorrhages. In Some cases, mucoid exudate was found filled in the tracheal lumen. Microscopically, there was focally intrusion of inflammatory cells reported in lungs (Figure 9). There was moderate to severe congestion noticed in the blood vessels of inter and intraparabronchial tissues. Oedema were also noticed as an important finding in the lungs (Figure 9). Necrosis too seen on few areas. Occurrence of interstitial pneumonia were more than any other type. Moreover, in some cases parabronchi of the lungs found to be filled with the inflammatory exudate and damaged alveolar cells. Trachea showed degenerative and inflammatory changes mostly in the epithelium.

Our explanation of pneumonia showed corroboration with Igbokwe *et al.* (2012) [22]. They explained that at necropsy of the pneumonic birds were cyanotic all over the body. The tracheal mucosa was reddened and the lungs were dark red, congested, firm and consolidated grossly. They also found that the breast muscles had a few petechial and ecchymotic haemorrhages. Microscopically, they reported severe

congestion of blood vessels in the interparabronchial and intraparabronchial tissues along with multifocal areas of infiltration of heterophils into the air capillaries, infundibulae, atria and interparabronchial septa. They also noticed necrosis of pulmonary tissue with deposition of fibrin in the vicinity of an apparent basophilic bacterial colony. Linares and Linares and Wagle (2001) [23] and Kashida *et al.* (2014) [24] also described pneumonia grossly and microscopically in detail.

Newcastle disease (ND): We suspected 2.6% birds for ND based on gross lesions. Grossly we observed some classical lesions that are of indicative ND are as follows. Tip of the proventricular glands had diffuse to multifocal hemorrhages (Figure 10). We found hemorrhagic and necrotic ulcers throughout the intestine and more specifically at cecal tonsils. Spleen of the poultry has multiple pin point hemorrhages. Trachea and lungs of the birds were severely congested. In some cases, we observed pneumonic changes in lungs. Kidneys were swollen. Perihepatitis and pericarditis also observed in the ND suspected cases.

Our findings have similarities with Khorrajiya *et al.*, (2015) [18]. They described gross and histopathological changes in various organs that appeared due to ND in detail. Tracheitis, pneumonia, pericarditis, myocarditis, catarrhal proventriculitis, catarrhal enteritis, typhlitis, perihepatitis, pancreatitis, nephritis interstitial, splenitis, atrophy of Bursa Fabricius, and encephalitis grossly as well as microscopically observed by Etriwati *et al.*, (2017) [25]. They discussed lesions very well as they did a study on Newcastle disease virus to know viral distribution and pathology.

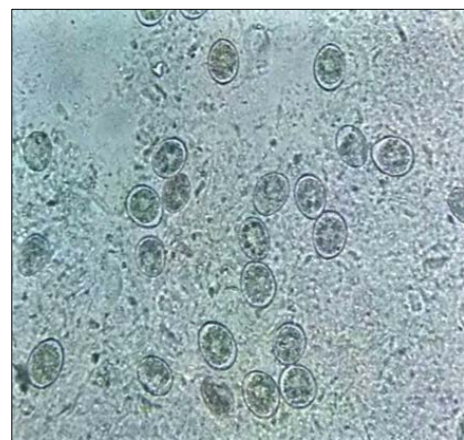


Fig 1: Showing coccidial oocysts in intestinal scrapings. 400X

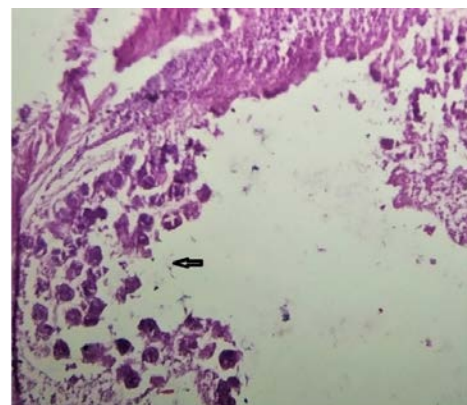


Fig 2: Microscopic image of intestine showing deposition of numerous coccidial oocysts (arrow) in the lamina propria of the intestine leaving submucosa exposed (H&E X 400)

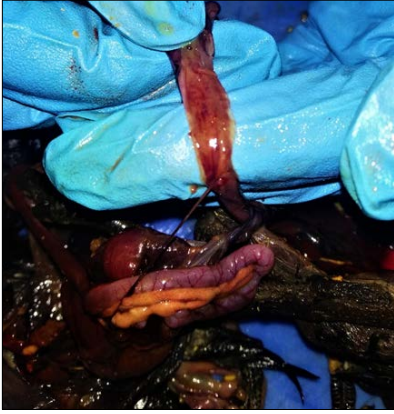

Fig 3: Gross image of intestine showing hemorrhagic enteritis

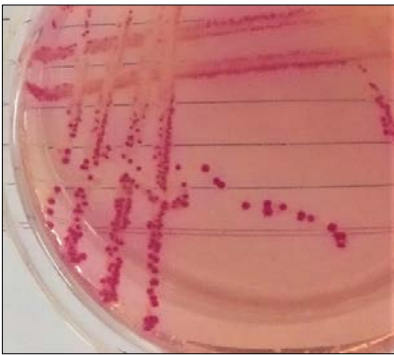


Fig 4: Showing pink color colonies in McConkey agar plate, Indicative of *E. coli*

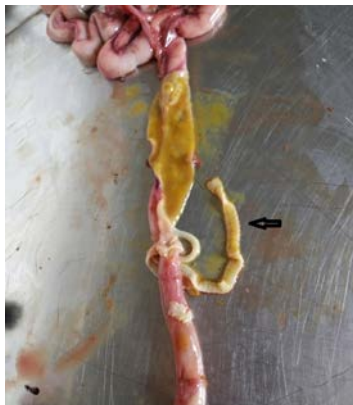

Fig 5: Image of parasitic enteritis where intestinal lumen is severely clogged by tape worms (arrow)

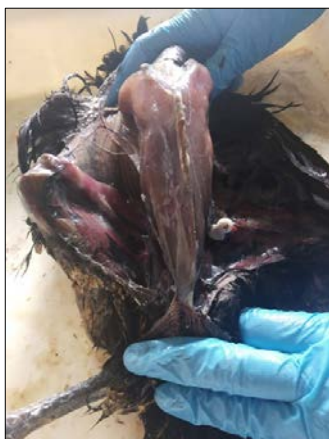

Fig 6: Image showing Kadaknath chicken with exposed keel bone, indicative of emaciation

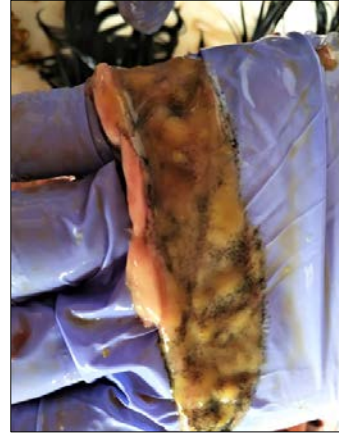

Fig 7: Image showing thickened intestinal mucosa along with severe haemorrhages

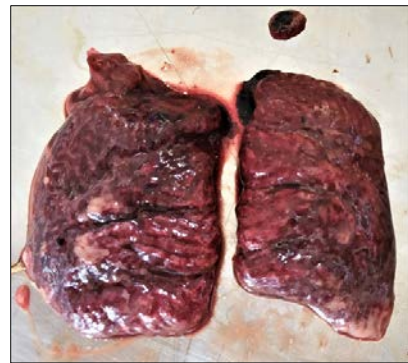

Fig 8: Image of Kadaknath showing pneumonic changes

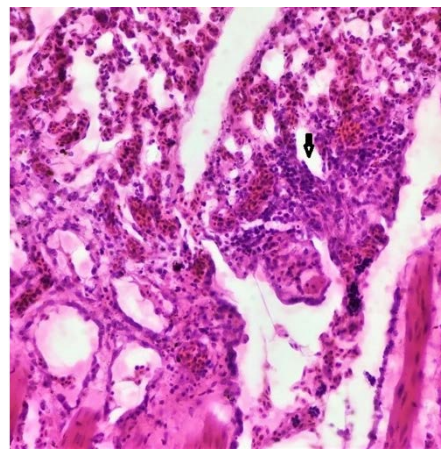


Fig 9: Microscopic image of pneumonia suspected lung showing mononuclear cell infiltration (arrow) along with moderate hemorrhages and mild oedema (dashed arrow)

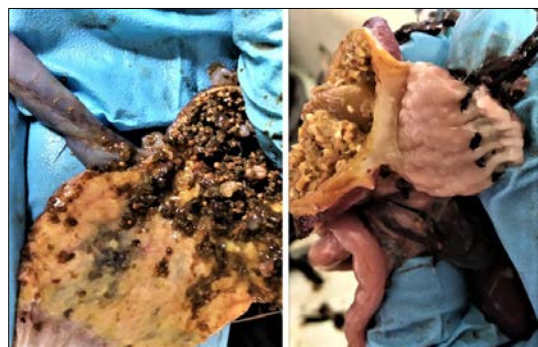

Fig 10: Image of proventriculus of the Kadaknath chickens, showing hemorrhages at the mucosa. This might be because of Newcastle disease

Conclusion

The diseases occurrence in a specific zone rest on various factors like management practices, geo-climatic condition of certain area, immunization status of chickens, social mindfulness etc. For establishment of profitable poultry farm, we must know the disease pattern so that a constructive and helpful prevention and control program can be calculated.

References

- Shahraki F, Shariati-Sharifi F, Nabavi R, Jamshidian A *et al.* Coccidiosis in Sistan: the prevalence of *Eimeria* species in native chicken and its histopathological changes. *Comparative Clinical Pathology* 2018;27(6):1537-1543.
- Singh R. Status of poultry production in India. Pashudhan Prahari 2019. <https://www.pashudhanpraharee.com/status-of-poultry-production-in-india/>
- Parmar SNS. Characterization of Kadaknath breed of poultry. *Jawaharlal Nehru Krishi Vishwa vidyalaya~ 522 ~ The Pharma Innovation Journal Jabalpur (M.P.) Technical Bulletin* 2003;1(2):1-21.
- Chakravarti S, Shukla S, Shrivastava N, Chhabra D, Chauhan L, Gumasta P *et al.* Incidence of various disease conditions in Kadaknath birds and their correlation with mortality rate. *The Pharma Innovation* 2018;7(10):519-522.
- Vijayalingam TA, Rajesh NV, Ilavarasan S, Venkataramanan R *et al.* Analysis of poultry disease pattern using post-mortem examination data in Ramanathapuram district: A retrospective study. *Journal of Entomology and Zoology Studies* 2019;7(5):1110-1114.
- Hooda A, Mishra SK, Nehra V, Lather *et al.* Patho-Anatomical studies on poultry mortality with special reference to gastro-intestinal tract disorders. *Haryana Veterinary* 2011;50:80-84.
- Dipti RP, Anita RD, Farhana B, Nurjahan B, Motahar HM *et al.* Epidemiology and pathology of intestinal helminthiasis in fowls. *Eurasian Journal of Veterinary Science* 2012;28:31-37.
- Slaoui M, Fiette L. Histopathology procedures: from tissue sampling to histopathological evaluation. *Methods of Molecular Biology* 2011;691:69-82.
- Cheesbrough M. *District laboratory practice in tropical countries*, 2nd edn, Part 2. Cambridge University Press, Cambridge 2006.
- Yadav V. Clinicopathological studies on spontaneous parasitic infections on Kadaknath birds with special reference to coccidiosis. M.V. Sc. & A.H. thesis (Veterinary Pathology), Nanaji Deshmukh Veterinary Science University, Jabalpur 2011.
- Abbas G, Khan SH, Hassan M, Mahmood S, Naz S, Surriya S *et al.* Incidence of poultry diseases in different seasons in Khushab district. *Pakistan Journal Advance Veterinary Animal Research* 2015;2(2):141-145.
- Kaboudi K, Umar S, Muni MT *et al.* Prevalence of coccidiosis in free-range chicken in Sidi Thabet, Tunisia. *Scientifica* 2016.
- Adamu M, Boonkaewwan C, Gongruttananun N, Vongpakorn M *et al.* Hematological, biochemical and histopathological changes caused by coccidiosis in chickens. *Agriculture and Natural Resources* 2013;47(2):238-246.
- Sharma S, Azmi S, Iqbal A, Nasirudullah N, Mushtaq I *et al.* Pathomorphological alterations associated with chicken coccidiosis in Jammu division of India. *Journal of Parasitic diseases* 2015;39(2):147-151.
- Olabode VB, Gunya DY, Alesa UM, Choji TPP, Barde IJ *et al.* Histopathological lesions of coccidiosis natural infestation in chickens. *Asian Journal of Research in Animal and Veterinary Sciences* 2020;5(2):41-45.
- Reid WM. *Chicken and turkey tapeworms*. Handbook. University of Georgia Poultry Department: Athens, GA 1962.
- Chakravarti A, Mishra SK, Nehra V, Lather D *et al.* Patho Anatomical studies on poultry mortality with special reference to gastro-intestinal tract disorders. *Haryana Veterinary* 2011;50:80-84.
- Khorrajiya JH, Pandey S, Ghodasara PD, Joshi BP, Prajapati KS, Hodasara DJ *et al.* Patho-epidemiological study on genotype-XIII Newcastle disease virus infection in commercial vaccinated layer farms. *Veterinary World* 2015;8(3):372-381.
- Jha AK. Histopathological studies of tapeworm *Raillietina tetragona* (Molin, 1858) from the gastro-intestine of indigenous chicken (*Gallus domesticus* L.) farming in Kirtipur, Nepal. *International Journal of Veterinary Sciences and Animal Husbandry* 2019;4(4):01-06.
- Bhowmik MK, Sinha PK, Chakraborty AK *et al.* Studies on the pathobiology of Howmik MK, Sinha PK, Chakraborty AK. Studies on the pathobiology of chicks experimentally infected with chicks experimentally infected with *Raillietina cesticillus*, *Raillietina cesticillus* (cestode). *Indian Journal of Poultry Science*. (cestode). *Indian Journal of Poultry Science* 1982;17:207-213.
- Saxena CB, Rai P, Shrivastava VP *et al.* *Veterinary postmortem examination, a laboratory manual*. 1st edition, Delhi Vikas publishing house 1998;12:557-561.
- Igbokwe IO, Adawaren EO, Abba Y *et al.* Concurrent outbreak of staphylococcal pneumonia with infectious bursal disease in broiler chickens. *Comparative Clinical Pathology* 2012;21:1571-1575.
- Linares JA, Wigle WL. *Staphylococcus aureus* pneumonia in turkey poults with gross lesions resembling aspergillosis. *Avian Diseases* 2001;45:1068-1072.
- Kashida N, Sakoda Y, Eto M, Sanuga Y, Kida H *et al.* Co-infection of *Staphylococcus aureus* or *Haemophilus paragallinarium* exacerbates H9N2 influenza A virus infection in chickens. *Archives in Virology* 2004;149:2095-2104.
- Etriwati Ratih D, Handharyani E, Setiyaningsih S *et al.* Pathology and immunohistochemistry study of Newcastle disease field case in chicken in Indonesia. *Veterinary World* 2017;10(9):1066-1071.