



ISSN (E): 2277- 7695
ISSN (P): 2349-8242
NAAS Rating: 5.23
TPI 2021; SP-10(5): 653-659
© 2021 TPI
www.thepharmajournal.com
Received: 04-03-2021
Accepted: 06-04-2021

MJ Raja

Assistant Professor,
Department of Veterinary
Pharmacology and Toxicology,
Veterinary College and Research
Institute, Namakkal,
Tamil Nadu, India

A Jagadeeswaran

Department of Veterinary
Pharmacology and Toxicology,
Veterinary College and Research
Institute, Namakkal,
Tamil Nadu, India

Exploration of *Mukia maderaspatana* as promising topical herbal preparation for cutaneous warts in cattle

MJ Raja and A Jagadeeswaran

Abstract

Bovine cutaneous papillomatosis (warts) is a contagious disease caused by Bovine Papilloma Virus (BPV) with proliferative and benign neoplasms on the skin in cattle. Generally, warts reduce the aesthetic value of the skin and also occurrence on teats and udder with infection leads to development of mastitis. Surgical and medicinal treatments including homeopathy remedies are available for the treatment of warts in cattle, but with limited cure. In recent days, awareness of using herbal drugs is increasing because of their promising results. Many medicinal herbs have been known for their anti-wart effects, but their effectiveness in livestock is not yet explored much with proper validation and screening. Hence, the present study was undertaken to explore the anti-wart effect of *Mukia maderaspatana* in cattle.

Collection and identification of herb, preparation of leaves and whole plant extracts, phytochemical analysis and selection of appropriate base for the preparation of ointment was done. A dose fixation trial with 1%, 2%, 5% and 10% of herbal ointment was conducted in clinical cases of warts in bovines. Based on the results, 10% of herbal ointment was selected as the dose for the treatment of warts in clinical cases of cattle. The results of the study showed enriched phytochemicals in whole plant powder than leaves crude powder. White soft paraffin was selected as base for the ointment preparation based on the scores on physical properties and practical utility.

The clinical study results revealed significant anti-wart effect at 10% of this herbal ointment. Animals treated with 10% *Mukia maderaspatana* ointment showed results as complete, moderate and no cure as 60%, 20% and 20% respectively. Enriched phytochemicals like tannins, potential therapeutic properties like antiviral, antibacterial, anti-haemorrhoidal, vasoconstrictor activities, and other properties like inhibition of lipid peroxidation and coagulation of proteins could be the reasons for the anti-wart effect of this herb and the same can be compared with other existing treatment procedures and explored further in detail.

Keywords: warts, bovine papilloma virus, *Mukia maderaspatana*, herbal ointment, anti-wart effect

Introduction

Cutaneous Papillomatosis (Warts) is an infectious and proliferative, benign neoplasm in cattle, caused by Bovine Papilloma Virus (BPV) belongs to Papovaviridae family (Jelinek and Tachezy, 2005) [12]. These are a diverse group of small, non-enveloped, circular, double-stranded DNA viruses infecting humans as well as many domestic and wild animal species, including birds, causing benign hyper proliferative lesions of both mucosal and cutaneous epithelia. Infection of this virus causes warts on the skin (papillomas and fibropapillomas) and in alimentary tract, and rarely cancers of the urinary bladder and alimentary tract (Borzacchiello and Roperto, 2008) [5].

Bovine Papilloma Virus (BPV) has 12 characterized serotypes and classified into three broad subgroups as Deltapapilloma viruses or fibropapillomas viruses (BPV-1 and BPV-2), Xipapilloma virus or epitheliotropic BPVs (BPV-3, BPV-4, BPV-6, BPV-9, BPV-10, BPV-11 and BPV-12) and Epsilon papilloma virus (BPV-5 and BPV-8). Also, an unassigned PV genus (BPV-7) is yet to be characterised (Freitas *et al.*, 2011) [9].

In farm animals, teat papillomatosis occurs as common benign condition of cutaneous form, which severely disturbs the milking process (Radostitis *et al.*, 2007) [28]. Warts normally spread by direct contact with infected animals and enters through cutaneous aberrations. This disease causes severe impact on the economic importance of animals especially by interfering with their values (Campo *et al.*, 1994) [6]. Generally cutaneous warts appeared as single or multiple, pedunculated, circumscribed, brown or black outgrowth with spherical, smooth or horny surfaces (Singh *et al.*, 2009) [32]. The most common sites of appearance of these warts are on the skin of udder, teats, neck, eyelids, shoulder, inner ear, and lower line of the abdomen (Ranjan *et al.*, 2013) [29]. Warts in teats and udder with inflammation may cause

Corresponding Author:

MJ Raja

Assistant Professor,
Department of Veterinary
Pharmacology and Toxicology,
Veterinary College and Research
Institute, Namakkal,
Tamil Nadu, India

difficulty in milking leads to development of thelitis and further mastitis in milking animals and in turn produce significant economic loss to livestock owners (Singh and Somvanshi, 2010) [33]. Since this is contagious, the transmission of warts from one animal to another cause a long-term problem of extensive persistent papillomatosis infection and great economic loss to the country.

Surgical and cryosurgical approaches (Venugopalan, 2000 [37]; and Cihan *et al.*, 2004 [7]), medicinal treatments with drugs (Vijayarathi *et al.*, 2018) [38], immunostimulation (Pattanayak 2004) [22], topical application of caustics and ointments like salicylic acid, dimethyl sulfoxide (O'Connor, 2001) [20] are the protocols available for the treatment of warts in cattle. Also, a homeopathic drug regimen with Thuja® drops as oral and Thuja® ointment as topical is also widely used for the treatment (Mathi *et al.*, 2016) [17].

The existing common treatment protocol available for the treatment of warts is either alone or combinations of any of the above mentioned therapy. Difficulties like unsatisfactory results, possibilities of recurrence of warts, high cost of drugs and long duration of therapy and belief on herbs as they are safe, more effective, cheaper has resulted in increased usage of medicinal herbs in recent years. The awareness and general acceptability of using herbal drugs is increasing in recent days due to their promising results on healing.

Mukia maderaspatana (L.) M. Roem. is an important traditional medicinal plant of Cucurbitaceae family and widely practiced in western districts of Tamil Nadu. This species is mainly distributed in tropical regions of India, especially in the lower hills of the Western Ghats (Petrus, 2013) [23]. Leaf-extract is consumed internally to cure piles (Anbarashan *et al.*, 2011 [11] and Lather *et al.*, 2011 [14]) and consumed orally to get relief from cold and cough (Petrus, 2013) [23]. The plant is also validated for the treatment of dyspepsia, flatulence, colic, constipation, ulcers, cough, asthma and vertigo in humans (Sowndhararajan *et al.*, 2010) [34]. Further it is reported to have anti-diabetic (Srilatha and Ananda, 2014) [35], vasoprotective (Petrus, 2012a) [25], antioxidant (Petrus, 2012b) [24], antibacterial (Prabakar *et al.*, 2015) [26], free radical scavenging (Vishnupriya and Ahmed, 2017) [39], hepatoprotective, immunomodulatory, antihyperglycaemic, antihyperlipidemic, *in-vitro* antiplatelet aggregation, anxiolytic, mosquito ovicidal, larvicidal and repellent potentials and local anaesthetic activities (Petrus, 2013) [23]. In livestock health and diseases, *M. maderaspatana* is widely used for the treatment of hygroma in cattle (Reddy and Sudarsanam, 1987) [30] and to increase body immunity and controlling digestive disorders (Anonymous, NIF, 2010) [2]. The squeezed plant is also applied to treat scabies of animals (Mallikadevi *et al.*, 2012) [16].

Many medicinal herbs have been known for their anti-wart effects, but their effectiveness in livestock is not yet explored much with proper validation and screening. Also, the data on such kind of studies are very limited and especially on the anti-wart effect of *Mukia maderaspatana* (L.) M. Roem is not yet been studied. Hence, the present study was carried out in clinical cases of cattle with warts.

Materials and Methods

The study was conducted in the Department of Veterinary Pharmacology and Toxicology, Veterinary College and Research Institute, Namakkal, Tamil Nadu, India as TANUVAS university sub-project, funded by the university. Also the clinical study was conducted in the cases of

cutaneous warts in cattle from different villages of Namakkal and Erode districts of Tamil Nadu.

Mukia maderaspatana (L.) M. Roem is a creeper herb having global distribution, but generally found in deciduous forests and in the plains. In India, the herbs are available in Tamil Nadu (called as Musumusukkai), Maharashtra, Kerala and Karnataka. The herb belongs to Cucurbitaceae family having symmetrical ovate leaves, angularly with 3-5 lobes. The flowers are in yellow, and the pea-sized fruits are in green, turning to orange and then red, as they mature (Petrus, 2013) [23].

Collection and identification of *Mukia maderaspatana* herb

Whole plant of *Mukia maderaspatana* was collected from the rural villages of Namakkal district, Tamil Nadu, during the period between July to October 2019, and was authenticated by the Department of Botany, Aringar Anna Government Arts and Science College, Kanavaipatti, Namakkal, Tamil Nadu, India (Plate 1).

Preparation of crude powder

The collected plants were washed in pure water and blotted gently with filter paper sheets and shade dried. The whole plant and leaves were finely powdered using a mechanical mixer/grinder after complete drying and used for biological experiments at various inclusion levels.

Preparation of aqueous and ethanolic extracts

Aqueous and ethanolic extracts were prepared separately from the powdered whole plant and leaves materials of 100 g each by using 400 ml of sterile distilled water and 400 ml of 95% ethanol respectively. Both extracts were shaken in an orbital shaker for 48 hours at room temperature. Then the extracts were filtered by using Whatman's filter paper No. 1, to separate the extractable substances. The collected filtrate was then evaporated at 37°C on hot air oven and the dried extracts were collected in a sterile container and stored at 4°C, until used for study.

Qualitative phytochemical analysis

The qualitative phytochemical analysis of aqueous and ethanolic extracts of *Mukia maderaspatana* herb leaves and whole plant was done by using the methods of Trease and Evans (1983) [36] and Kokate *et al.* (1990) [13] at the laboratory of Ethno Veterinary Herbal Research Centre for Poultry, Veterinary Clinical Complex, Namakkal, Tamil Nadu.



Fig 1: Plate 1; *Mukia maderaspatana* herb

Five grams of dried aqueous and ethanolic extracts of the plant leaves and whole plant was added with 50 ml of distilled water and heated below 50 °C for 1 – 2 minutes and utilized for the detection of various phytochemicals.

Detection of flavonoids

Alkaline reagent test

To 2 ml of each extract, few drops of sodium hydroxide solution was added. Formation of intense yellow colour, which became colorless on addition of dilute HCl acid, indicated the presence of flavonoids.

Detection of alkaloids

Hager's test

2 ml of each extract was treated with Hager's reagent (saturated picric acid solution). Formation of an orange/yellow colour precipitate indicated the presence of alkaloids.

Detection of saponins

Froth test

2 ml each extract was diluted with 10 ml of distilled water and shaken for 15 minutes. Formation of layer of foam which remained for 10 minutes indicated the presence of saponins.

Detection of tannins

To 2 ml each extract, 3 drops of 1% of ferric chloride was added. Appearance of blue green color indicated the presence of tannins.

Detection of terpenoids

To 2 ml each extract, an equal amount of chloroform and then 2 ml of conc. H₂SO₄ along the sides of the test tube was added. Formation of a brown color ring at the junction of two liquids indicated the presence of terpenoids.

Detection of carbohydrates

Fehling's test

To 2 ml of each extract, 2 ml of Fehling's A and B solution (each) was added and heated at 50°C for 1 minute. Formation of red precipitate indicated the presence of reducing sugars.

Detection of phylobatannins

To 2 ml of each extract, 1 ml of diluted HCl solution was added. Formation of red precipitate indicated the presence of phylobatannins.

Detection of hydrolysable tannins

To 2 ml of each extract, 2 ml of ammonia solution was added. Formation of an emulsion indicated the presence of hydrolysable tannins.

Detection of glycosides

To 2 ml of each extract, 2 ml of diluted H₂SO₄ was added and heated at 50°C for 2 minutes. Then 1 ml of 10% NaOH was added. To that, 5 ml of Fehling's solution A and B (each) were added. Appearance of brick red precipitate indicated the presence of glycosides.

Detection of cardiac glycosides

To 2 ml of each extract, an equal amount of glacial acetic acid was added. Then, 1 drop of 10% ferric chloride and 2 ml of conc. H₂SO₄ were added. Formation of three layers of colors

(upper layer – Green, middle layer – brown and lower layer – violet) indicated the presence of cardiac glycosides.

Selection of proper base for *Mukia maderaspatana* topical preparation

In this study, seven different bases viz., glycerol monostearate, liquid paraffin, lanolin, white soft paraffin, propylene glycol, polyethylene glycol 4000 and polyethylene glycol 1500 were tried for the topical preparation of *Mukia maderaspatana* herb. Based on the scores as + (poor), ++ (moderate) and +++ (good) given on appearance, texture, non-dehydrating, non-gritting, non-greasy, non-staining, non-hygroscopic like physical properties (Shelke Usha and Mahajan Ashish, 2015) [31], the best base was selected for further clinical application in bovines. Further, based on the feedback received after application, usage and cost effectiveness of the preparation, the suitable base was selected and used for the topical preparation in the clinical trials on warts.

Experimental design

The study trial was conducted in 4 groups to determine and fix the dose (concentration) of *Mukia maderaspatana* as topical preparation for their anti-wart property in bovine. Each group comprised of two animals and a total number of 8 cattle were used for the dose fixation study. The whole plant crude powder of the herb at the concentration levels of 1%, 2%, 5% and 10% was tried as topical ointment preparations on clinical cases of warts in bovines, twice daily application for a minimum period of two weeks (Table. 1).

Table 1: Experimental design for the fixation of dose (Concentration) of *Mukia maderaspatana* ointment preparation in bovine

Groups	Preparation	Dose (Concentration)	No. of Animals
T ₁	<i>Mukia maderaspatana</i> herbal ointment for 14 days as topical use.	1%	2
T ₂		2%	2
T ₃		5%	2
T ₄		10%	2

Parameters studied

In this study, details on signalment, anamnesis of the disease and previous treatments given were collected and recorded. The effect of *Mukia maderaspatana* ointment was assessed based on the cure of wart (drying, shrinking and shedding) and evaluated as before and after treatment. The degree of cure is expressed as no cure, moderate cure and complete cure after two weeks of topical application of the preparation.

Results

Qualitative phytochemical analysis

The qualitative phytochemical screening of aqueous and ethanolic extracts of leaves and of whole plant of *Mukia maderaspatana* is shown in table 2.

In the qualitative phytochemical analysis, the aqueous and ethanolic extracts of *Mukia maderaspatana* showed the presence of tannins, terpenoids, glycosides, flavonoids, saponins, alkaloids and cardiac glycosides. The ethanolic extracts showed enriched phyto-constituents than aqueous extract in both leaves and whole plant powder extracts of *Mukia maderaspatana* herb.

Table 2: Phytochemical constituents of *Mukia maderaspatana* herb extracts identified by qualitative screening

S. No.	Phytochemical constituents	Leaves extract		Whole plant extract	
		Aqueous	Ethanollic	Aqueous	Ethanollic
1	Terpenoids	++	++	++	+++
2	Carbohydrates	++	++	++	+
3	Hydrolysable Tannins	+	-	+	-
4	Glycosides	++	++	+++	-
5	Cardiac Glycosides	++	++	+	+
6	Alkaloids	+	+	+	+
7	Flavonoids	-	+	+	+

The whole plant powder extracts of *Mukia maderaspatana* showed enriched phytochemicals than leaves extracts, especially terpenoids and glycosides. Based on the results, the whole plant powder was selected and further used for topical preparation in this study.

Selection of proper base for *Mukia maderaspatana* topical preparation

Topical dosage forms like paste, cream, gel and ointments were prepared with *Mukia maderaspatana* whole plant crude powder (Table. 3). Based on the scores on physical properties

of topical dosage forms, ointment preparation was selected for the next level.

Ointments prepared with lanolin anhydrous and white soft paraffin bases showed similar score on physical properties. But, the lanolin based preparation showed more greasiness than white soft paraffin based ointment. So, both ointments were tested on animals with warts. Difficulty in washing, cost difference and no difference on impact on efficacy made to select white soft paraffin over lanolin as the base for the preparation of *Mukia maderaspatana* ointment for the next clinical trial.

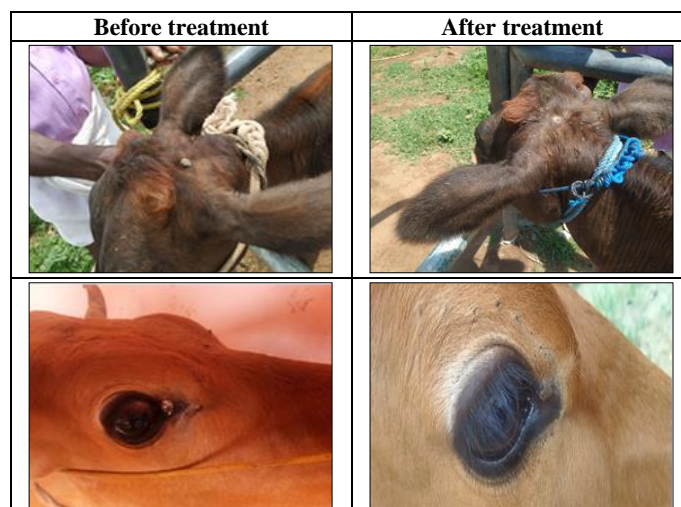
Table 3: Comparison on the physical properties of different topical dosage forms of *Mukia maderaspatana* herb

Physical properties	Paste	Ointment (Lanolin)	Cream	Ointment (WSP)	Gel
Smooth Texture	++	+++	++	+++	++
Appearance	++	+++	+	+++	+
Non Dehydrating	+++	+++	+	+++	+++
Non Gritty	++	+++	+++	+++	++
Non Greasy	+++	+	+++	++	++
Non Staining	+++	++	+++	++	+++
Non Hygroscopic	++	+++	++	+++	+

Clinical trial

At the end of the study period, *Mukia maderaspatana* herbal ointment did not show any significant results on healing/curing of warts in animals of treatment groups T₁ and T₂. But in the treatment group T₃, the herb showed some response terms of reduction in the size or number of warts when applied. In the treatment group T₄, the herb showed significant result in the cure of warts completely in one cattle and good result in another cattle. Based on the results, 10%

Mukia maderaspatana ointment was further studied in another four cattle having warts. So, out of six animals, the herbal ointment showed complete, moderate and no cure as 60%, 20% and 20% respectively (Plate. 2). Based on the warts location in the body of the animal, 80% of clinical cases showed good results having warts other than udder and teats. From this study, it is proved that at 10% *Mukia maderaspatana* ointment showed significant effect on wart healing.






Plate 2: Cattle treated with 10% *Mukia maderaspatana* herbal ointment

Discussion

Phytochemistry

Herbs are considered as an indispensable source of drugs of traditional herbal medicinal practices, modern medicine and chemical entities for synthetic drugs (Neube *et al.*, 2008) [18]. In recent years, plant derived substances have become of great interest owing to their versatile uses (Prashant *et al.*, 2011) [27]. The therapeutic potentials of herbs depend on the type of phytochemical substances they synthesize and store. In the qualitative phytochemical analysis, the aqueous and ethanolic extracts of *Mukia maderaspatana* showed the presence of tannins, terpenoids, glycosides, flavonoids, saponins, alkaloids and cardiac glycosides.

The results of qualitative analysis of this study are in accordance with the results of Gomathy *et al.* (2012) [10], Vishnupriya and Ahmed (2017) [39] and Dhanaraj and Jegadeesan (2011) [8]. These phytochemical constituents are responsible for the medicinal activity of the ethanolic extract of *Mukia maderaspatana* (Gomathy *et al.*, 2012) [10]. Eugenol is the major component found in the whole plant of *Mukia maderaspatana* which has fly repellent, antioxidative properties and inhibition of lipid peroxidation (Gupta *et al.*, 2002) [11]. Saponins in this plant has medicinal values and used in many preparations (Asl and Hosseinzadeh, 2008) [3].

Clinical trial

Based on the results, the study revealed the anti-wart effects above 5% of *Mukia maderaspatana* whole plant ointment. At

5% concentration, clinical cases showed mild to moderate healing on 15 days of treatment. Also, it is proved that *Mukia maderaspatana* ointment at 10% w/w strength showed significant effect on wart healing. Out of six animals it showed significant healing in treated animals. 10% of *Mukia maderaspatana* ointment showed significant results in the same treatment period. On the selected dose 10% *Mukia maderaspatana* ointment showed significant effect (60%) on wart healing.

Musumusukkai [*Mukia maderaspatana* (L.) M. Roem.], is a creeper herb of Cucurbitaceae family reported to be a commonly used ethnomedicinal plant since 2000 years ago by Kani tribe healers, the oldest South Indian ethnic community of Tirunelveli hills of the Western Ghats (Ayyanar and Ignacimuthu, 2011) [4]. It is generally sold by vegetable vendors throughout South India (Nisha and Rajeshkumar, 2010) [19]. Folkloric traditional medicine claims that the leaves and tender shoots are for the treatment of cough, cold, flu, toothache, body pain etc. The herb is useful as aperient, diuretic, stomachic, antipyretic, antipruritic, antisthmatic, antitussive, antihistaminic, antibronchitic and as an expectorant, in addition to its prescription against vertigo and biliousness (Petrus, 2013) [23].

Mukia maderaspatana is widely used in the health-care of livestock to treat hygroma, to increase body immunity and controlling digestive disorders of cattle. The petroleum ether extracts have been found to exhibit moderate larval toxicity against the West Nile virus and filariasis causing vector,

Culex quinquefasciatus (Petrus, 2013) [23]. Traditionally, leaf-extract of this herb is consumed internally to cure piles (Anbarashan *et al.*, 2011 and Lather *et al.*, 2011) [1, 14]. Tannins of this plant are astringents and have medicinal values as potential antiviral (Lin, *et al.*, 2004) [15], antibacterial (Prabakar *et al.*, 2015) [26], vasoprotective (Petrus, 2012a) [25], and antioxidant (Petrus, 2012b) [24]. It is also proposed that, astringent herbs accomplish anti-haemorrhoid activity by inhibiting lipid peroxidation, causing coagulation of proteins and act as vasoconstrictors (Odukoya *et al.*, 2009) [21] which could be the reason for the anti-wart effect of this herb.

Conclusion

An age old traditional herb *Mukia maderaspatana* has been in use for the treatment of various ailments in people and animals. The study results revealed the anti-wart effect at 10% of *Mukia maderaspatana* herbal ointment. Also 10% ointment showed difference on healing of warts, based on its location. Warts located other than udder and teats showed good response (80% of healing) to this drug. This shows that the herb is very effective to certain sub type of BPV which influences the cell involvement, type of warts and its morphology. Further, detailed study on the phytochemicals responsible for the healing of warts, studies on oral administration of the herb alone and combination with topical application can be done.

Acknowledgement

The authors acknowledge the facilities and financial assistance provided by Tamil Nadu Veterinary and Animal Sciences University (TANUVAS), Chennai-5, Tamil Nadu to carry out the research under TANUVAS SUB-PROJECT SCHEME 2019.

References

- Anbarashan M, Parthasarthy N, Padmavathy A. Ethno-floristic survey in sacred groves, Pudukottai district, Tamil Nadu, India. *Journal of Medicinal Plants Research* 2011;5(3):439-443.
- Anonymous. Tamil Nadu innovates, SRISTI and Honey Bee Network, National Innovation Foundation, Ahmedabad, Gujarat, India 2010, 42.
- Asl MN, Hosseinzadeh H. Review of pharmacological effects of *Glycyrrhiza* sp. and its bioactive compounds. *Phytotherapy Research* 2008;22(6):709-724.
- Ayyanar M, Ignacimuthu S. Ethnobotanical survey of medicinal plants commonly used by Kani tribals in Tirunelveli hills of Western Ghats, India. *Journal of Ethnopharmacology* 2011;134(3):851-864.
- Borzacchiello G, Roperto F. Bovine papilloma viruses, papillomas and cancer in cattle. *Veterinary Research* 2008;39:45.
- Campo MS, Jarrett WF, O'neil W, Baron RJ. Latent papilloma virus infection in cattle. *Research in Veterinary Science* 1994;56:151-157.
- Cihan M, Ozaydin I, Ozba B, Baran V. Clinical effects of Levamisole in bovine papillomatosis. *Indian Veterinary Journal* 2004;81:321-323.
- Dhanaraj TS, Jegadeesan M. Physio-chemical and HPTLC studies on leaf and root of *Mukia maderaspatana* (L.) M. Roemer. *Journal of Chemical and Pharmaceutical Research* 2011;3(3):375-380.
- Freitas AC, Silva MAR, Jesus ALS, Mariz FC, Cordeiro MN, Albuquerque BMF, Batista MVA. Recent insights into Bovine Papilloma virus. *African Journal of Microbiology Research* 2011;5(33):6004-6012.
- Gomathy G, Vijay T, Sarumathy K, Gunasekaran S, Palani S. Phytochemical screening and GC-MS analysis of *Mukia maderaspatana* (L.) leaves. *Journal of Applied Pharmaceutical Science* 2012;2(12):104-106.
- Gupta SK, Prakash J, Srivastava S. Validation of traditional claim of Tulsi, *Ocimum sanctum* Linn as a medicinal plant. *Indian Journal of Experimental Biology* 2002;40(7):765-773.
- Jelinek E, Tachezy R. Cutaneous papillomatosis in cattle. *Journal of Comparative Pathology* 2005;132:70-81.
- Kokate CK, Purohit AP, Gokhale SB. *Pharmacognosy*. Edn 1, Nirali Prakashan, Pune 1990, 123.
- Lather A, Gupta V, Garg S, Singh A, Sachdeva K. Pharmacological potential of the plants used in treatment of piles – A review. *Journal of Natura Conscientia* 2011;2(1):255-265.
- Lin LU, Shu-wen L, Shi-bo J, Shu-guang W. Tannin inhibits HIV-1 entry by targeting gp41. *Acta Pharmacologica Sinica* 2004;25(2):213-218.
- Mallikadevi T, Paulsamy S, Karthika K, Jamuna S. Protocol for *in-vitro* culture from leaf and nodal explants of *Mukia maderaspatana* (L.) M. Roem., an important traditional medicinal climber. *Journal of Scientific Research in Pharmacy* 2012;1(3):36-40.
- Mathi PM, Saranya K, Umadevi U, Umakanthan T. An effective treatment regimen for warts in cattle. *Journal of Veterinary Science and Animal Husbandry* 2016;4(2):1-2.
- Neube NS, Afolayan AJ, Okoh AI. Assessment techniques of antimicrobial properties of natural compounds of plant origin: Current methods and future trends. *African Journal of Biotechnology* 2008;7(12):1797-1806.
- Nisha MC, Rajeshkumar S. Survey of crude drugs from Coimbatore city. *Indian Journal of Natural Products and Resources* 2010;1(3):376-383.
- O'Connor JJ. *Dollor's Veterinary Surgery*. Edn 4, CBS Publishers and Distributors, New Delhi 2001, 49-50.
- Odukoya OA, Sofidiya MO, Ilori OO, Gbededo MO, Ajadotugwe JO, Olaleye OO. Hemorrhoid therapy with medicinal plants: astringency and inhibition of lipid peroxidation as key factors. *International Journal of Biological Chemistry* 2009;3:111-118.
- Pattanayak S. Autohaemotherapy in bovine papillomatosis. *Intas Polivet* 2004;5(1):16-17.
- Petrus AJA. Ethnobotanical and pharmacological profile with propagation strategies of *Mukia maderaspatana* (L.) M. Roem.- A concise overview. *Indian Journal of Natural Products and Resources* 2013;4(1):9-26.
- Petrus AJA. *Mukia maderaspatana* (L.) M. Roemer - A Review of its global distribution, phytochemical profile and antioxidant capacity. *Asian Journal of Chemistry* 2012b;24(6):2361-2368.
- Petrus AJA. *Mukia maderaspatana* (Linn.) M. Roemer: A potentially antidiabetic and vasoprotective functional leafy-vegetable. *Pharmacognosy Journal* 2012a;4(34):1-12.
- Prabakar K, Periyasamy S, Deepak C. Phytochemicals screening, antioxidant and antibacterial potential of *Mukia scabrella* (Musumusukkai) against nosocomial bacterial pathogens. *International Journal of Pure and*

- Applied Zoology 2015;3(1):1-8.
27. Prashant T, Bimlesh K, Mandeep K, Gurpreet K, Harleen K. Phytochemical screening and extraction: A Review. *Internationale Pharmaceutica Scientia* 2011;1(1):98-106.
 28. Radostitis OM, Gay CC, Hinchcliff KW, Constable PD. *Textbook of Veterinary Medicine*. Edn 10, El-sevier, Spain, ISBN: 978-0-7020- 2777-2 2007, 1421-1423.
 29. Ranjan R, Ghumman SPS, Bhatt GR, Singh RS. Efficacy of autogenous vaccine and auto-hemotherapy in bovine cutaneous papillomatosis. *Intas Polivet* 2013;14(2):411-414.
 30. Reddy KR, Sudarsanam G. Plants used as veterinary medicine in Chittoor district, Andhra Pradesh, India. *International Journal of Crude Drug Research* 1987;25:145-152.
 31. Shelke Usha Y, Mahajan Ashish A. Review on: An Ointment. *International Journal of Pharmacy and Pharmaceutical Sciences* 2015;4(2):170-192.
 32. Singh V, Somvanshi R, Tiwari VK. Papillomatosis in Indian cattle: Occurrence and etiopathology. *Indian Journal of Veterinary Pathology* 2009;33:52-57.
 33. Singh V, Somvanshi R. Spontaneous teat papillomatosis in Indian cows: A pathological study. *Indian Journal of Veterinary Pathology* 2010;34:5-8.
 34. Sowndhararajan K, Jince Mary Joseph, Rajendrakumaran D, Manian S. *In vitro* antioxidant characteristics of different parts of *Melothria maderaspatna* (L.). *Cogn. International Journal of Pharmacy and Pharmaceutical Science* 2010;2(3):117-123.
 35. Srilatha BR, Ananda S. Antidiabetic effects of *Mukia maderaspatana* and its phenolics: An *in vitro* study on gluconeogenesis and glucose uptake in rat tissues. *Pharmaceutical Biology* 2014;52(5):597-602.
 36. Trease GE, Evans WC. *Text book of Pharmacognosy*. Edn 12, Balliere, Tindall, London 1983.
 37. Venugopalan A. *Essentials of Veterinary Surgery*. Edn 8, Oxford and IBH publication Co. Pvt. Ltd., New Delhi 2000, 85-86.
 38. Vijayasarithi MK, Sheeba A, Venkatesan M. Therapeutic management of bovine calf papillomatosis. *Indian Veterinary Journal* 2018;95(9):60-61.
 39. Vishnupriya C, Ahmed F. Potency of two commonly available plants *Pisonia alba* and *Mukia maderaspatana* in the health industry. *International Journal of Current Microbiology and Applied Sciences* 2017;6(1):721-732.