



ISSN (E): 2277- 7695
ISSN (P): 2349-8242
NAAS Rating: 5.23
TPI 2021; SP-10(4): 21-23
© 2021 TPI
www.thepharmajournal.com
Received: 16-02-2021
Accepted: 18-03-2021

Rohit Kumar Sharma
MVSc, Department of
Veterinary Surgery and
Radiology, CVAS, RAJUVAS,
Bikaner, Rajasthan, India

Dependra Singh Saran
MVSc Scholar, Department of
Veterinary Surgery and
Radiology, CVAS, RAJUVAS,
Bikaner, Rajasthan, India

Anil Kumar Bishnoi
Assistant Professor, Department
of Veterinary Surgery and
Radiology, CVAS, RAJUVAS,
Bikaner, Rajasthan, India

External skeletal fixation of tibial fracture in a domesticated rabbit

Rohit Kumar Sharma, Dependra Singh Saran and Anil Kumar Bishnoi

DOI: <https://doi.org/10.22271/tpi.2021.v10.i4Sa.5952>

Abstract

Present case reports a successful diagnosis and surgical management fractured left tibia bone through linear external skeletal fixation system (LESF) in a 1.5 year old male rabbit. Surgery was performed under general anaesthesia. A Rabbit presented in Veterinary clinical complex, CVAS, RAJUVAS, Bikaner, with a history of fall from height and clinical as well as radiographic examination revealed compound, segmental fracture of diaphysis of left tibia bone. LESF was done and owner was advised for further follow-up at regular interval. ESF assembly as well as weight bearing status was evaluated as objective of this study.

Keywords: transarticular LESF, general anaesthesia, rabbit, tibia, compound fracture

Introduction

As we all know that rabbits are very active with their powerful limbs and sudden excitement from the external environment causes this animal more prone to fractures. Rabbits were earlier used as laboratory animals but now a day's rabbit rearing became a people's fond. Skeleton of this species is very light which comprises only 7 to 8% of the body weight as compared to the skeleton of a cat, which makes about 12 to 13% of the body weight (Tiwari *et al.*, 2012) ^[1]. Improper handling or caging with external physical stress and over activity of trapped limb in improperly sized wire mesh are the predisposing factors for fractures in this animal. However occurrence of tibia fracture is more common in rabbit (Richardson, 2000) ^[2]. Fractures in lower limbs are often open (Compound fractures), due to the minimal presence of soft tissue (Reusche, 2008) ^[3]. They are often difficult to treat through internal fixation techniques and need to be mended with patience, in order to avoid further tearing of the skin and that's why to manage such compound fractures, external skeletal fixation is required. External skeletal fixation technique (ESF) is most versatile and much acceptable technique in veterinary orthopaedics especially for management of comminuted, open or infected fractures (Egger *et al.*, 1998) ^[4] and can be used with variety of configurations (Beever *et al.*, 2018) ^[5].

Anamnesis

A 1.5 year old male rabbit was presented with history of fall from height injury having compound tibia fracture in left hind limb. Animal was able to walk on remaining (unaffected) limbs and all other habits like feeding and water intake were normal.

Diagnosis

On clinical examination, the rabbit was having severe pain on palpation and unable to bear weight on the affected limb. Gross and radiographic examination (two orthogonal radiographs) revealed compound (open) mid-shaft segmental short-oblique fracture of left tibia (Fig. 1).

Pre-Operative Planning, Materials Used, Anaesthesia and Surgical Procedure

On the basis of pre-operative two orthogonal radiographs (Fig:1), intamedullary pinning with LESF technique was decided. Various measurements viz. cortex to cortex bone diameter and medullary cavity diameters at different level in fractured bone were noted and on the basis of these measured diameters, size of IM-pin and transcortical pins (for ESF) were decided. Materials used for stabilization of fracture were mentioned in Table 1. For intamedullary pinning with ESF technique, 40-50% of medullary cavity diameter was decided for IM-pinning and 25-30% of cortex to cortex was decided for transcortical pin insertion.

Corresponding Author:
Rohit Kumar Sharma
MVSc, Department of
Veterinary Surgery and
Radiology, CVAS, RAJUVAS,
Bikaner, Rajasthan, India

Detailed information of anaesthetic protocol which was used in present cases is described in Table 2. After anaesthesia, surgical site was prepared aseptically and animal was kept in ventro-dorsal position. Incision was made on the medial aspect of the bone and bone was exposed. At the time of

surgery during IM-pin insertion the fracture become comminuted and leads to failure of IM-pinning technique and that's why uniplanner bilateral linear external skeletal fixation assembly was applied to immobilize the fracture fragments.

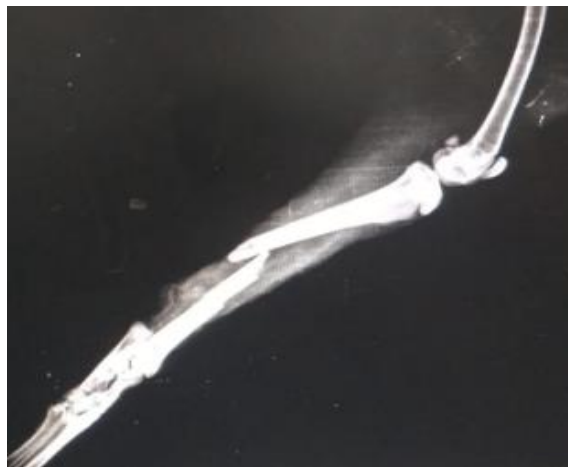


Fig 1: (Pre-operative radiograph)

Table 1: Materials used for construction of LESF assembly

Materials used	Metal	Number	Size
Transcortical pins (Non-threaded)	Stainless steel	Total 3 (2 in proximal fragment and 1 in distal fragment)	2 mm (all pins)
Jess-clamp	Stainless steel	Total 6 (4 in proximal fragment and 2 in distal fragment)	08X12 mm (Nebula surgical)
Smooth connecting bar	Stainless steel	Total 2 (one in each side)	2.5 mm
L-key was used and clamps was tightened	Iron	-	-

Table 2: General anaesthesia according to Tranquilli *et al.*, (2013)^[6] were used to unconscious the animal with appropriate dose calculated after measuring the body weight of rabbit.

Drug used for balance anaesthesia	Dose rate & Route of administration
Xylazine HCL	5 mg/Kg B.W. & I.M.
Ketamine HCL	35mg/Kg B.W. & I.M.
Note: For maintenance, similar dose rate was used as per need.	

Surgical procedure of ESF: After preparing surgical site aseptically, one transcortical pin (first proximal pin) was drilled through safe corridors preventing nerve and muscle injury, in the proximal fragment. After placement of proximal pin, distal most pin was drilled into the tarsal bones and then second proximal pin was placed after manual reduction of fracture. Before placement of second proximal pin, both connecting bars lodged with all 6 jess-clamps, were applied and most proximal and most distal pin was tightened with the help of L-Key and then second proximal pin was inserted into the jess-clamp (already lodged in connecting bar) and then drilled through both the cortices. All the assembly was loosened and manual reduction of fracture fragments was done and then complete ESF was tightened. Incision wound (which was created for IMP as described earlier), was closed by simple interrupted suture pattern by using non-absorbable silk No. 1.

Post-Operative Care

ESF assembly and wound was protected from external contamination through bandaging of complete limb from stifle to phalanges. Owner was advised for regular dressing (cleaning of pin-skin interfaces) and post-operative follow-up examination (clinical as well as radiographic evaluation). Antibiotics (ceftriaxone with tazobactam) and NSAID (Meloxicam) were used for 7 and 5 days respectively. Sutures

were removed 21 days after surgery. limb function was also restricted up to 1 month after surgery.

Results and Discussion

a. Assembly evaluation: Uniplanner bilateral construct which included 3 K-wires (2mm), 2 smooth connecting bars and 6 jess beta clamps, provided adequate reduction of overriding fracture till implant was removed. Present assembly was maintained at position till removal. No faulty placement of transcortical pins were observed in immediate post-operative radiographs. Saunders and Houston, (2018)^[7] treated closed radius-ulna fracture in a 3 year old male rabbit and they used 0.9 mm positive profile, 7 transcortical pins with 6 mm diameter tubular external fixator bar. However Tiwari *et al.*, (2012)^[1] concluded that open/compound tibial fractures in rabbits can be successfully repaired by intramedullary pinning technique.

b. Evaluation of post-operative radiographs: Owner was advised for follow-up radiographs at regular interval. Minimum bridging callus was evident in radiograph taken after 1.5 month of surgery (Fig: 3 & 4). Many researchers (Saunders and Houston, 2018)^[7] also explained about minimum evidence of callus formation in post operative follow-up radiographs especially in rabbits.

- c. Clinical evaluation of limb function:** Due to transarticular ESF application, operated limb was remained extended till removal (Fig:2) however extension-flexion was observed in remaining joints of same limb. Partial weight bearing was observed from 2nd month onward. Complete weight bearing was noticed by owner (which remained in telephonic contact) from 3.5 to 4 month after surgery. complete weight bearing on operated limb in rabbit was observed between 1 -2 months by few studies (Tiwari *et al.*, 2012 ; Saunders and Houston, 2018) ^[1, 7].
- d. Post-operative complications:** No exudation at pin-skin interface was observed till implant removal. 2nd proximal transcortical pin got loosened by day 62. All 3 pins were found loosened at the time of implant removal but assembly was maintained at position. Slight long term joint stiffness was reported as major post-operative complication in present case.
- e. Day of Implant Removal:** When radiographic healing was achieved, ESF construct was removed (on day 92 after surgery). Saunders and Houston, (2018) ^[7] removed ESF from radius-ulna bone of rabbit after 2 month of surgery.



Fig 2: (Rabbit after transarticular ESF)

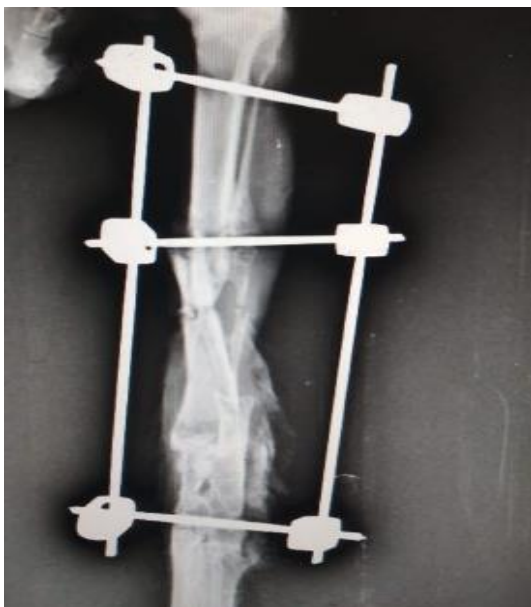


Fig 3: (Progressive radiographic healing)

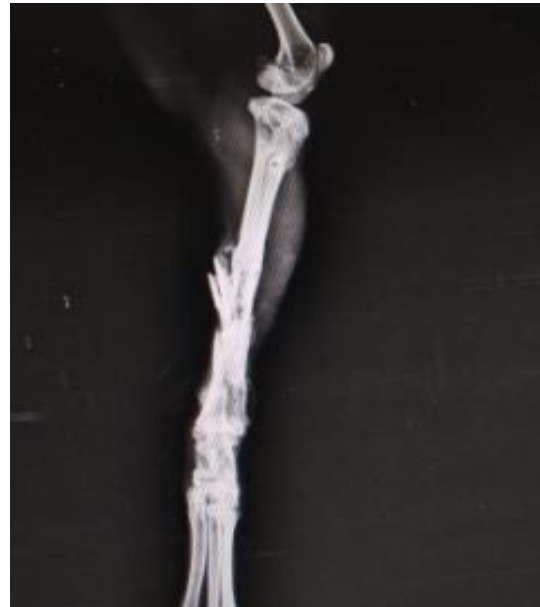

Fig 4: Radiograph after complete healing

Conclusions

In case of rabbit, radiographic evaluation of operated limb will provide only information regarding safe placement of ESF construct rather than much evident callus formation as seen in radiographs of other species. Clinical evaluation of limb function is more significant instead of radiographic evaluation in this species (See in figures). ESF can be a better and versatile technique to the skilled veterinarian for management of compound tibial fractures in rabbit.

Acknowledgement

Authors are thankful to the Head, Department of Veterinary Surgery and Radiology, CVAS, RAJUVAS, Bikaner for providing necessary facilities and highly acknowledge the efforts of authors concerned to this article.

References

1. Tiwari DK, Parikh PV. Clinical Management of Tibial Fracture in a Rabbit. *Intas Polivet* 2012;13(2):462-463.
2. Richardson VCG. The Musculo-skeletal system. In: *Rabbit: Health, Husbandry and Diseases*. Publ. Wiley-Blackwell Publishers, Ames, Iowa, USA 2000, 108-114.
3. Reusche B. Back and Hind limb quandaries. *Vet. Times* 2008;38:38-39.
4. Egger EL. External skeletal fixation. In: *Current techniques in small animal surgery*, Bojrab M J, IV ed. Williams and Wilkins Baltimore, USA 1998, 941-950.
5. Beever LJ, Giles K, Meeson RL. Postoperative complications associated with external skeletal fixators in dogs. *Veterinary and Comparative Orthopaedics and Traumatology* 2018;31(2):137-143.
6. Tranquilli WJ, Thurmon JC, Grimm KA. (Eds.). *Lumb and Jones' veterinary anesthesia and analgesia*. John Wiley & Sons 2013.
7. Saunders R, Houston C. A novel method of external skeletal fixation in a rabbit (*Oryctolagus cuniculus*). *Companion Animal* 2018;23(1):30-32.