www.ThePharmaJournal.com

The Pharma Innovation

ISSN (E): 2277- 7695
ISSN (P): 2349-8242
NAAS Rating: 5.23
TPI 2021; SP-10(4): 01-04

www.thepharmajournal.com
Received: 01-02-2021
Accepted: 03-03-2021

Y Vishnu Prasanth Reddy
Department of Veterinary Pathology, College of Veterinary Science, Srivenkateswara Veterinary University, Tirupati, Andhra Pradesh, India

A Anand Kumar
Professor and Head, Department of Veterinary Pathology, College of Veterinary Science, Sri Venkateswara Veterinary University, Tirupati, Andhra Pradesh, India

P Amaravathi,
Assistant Professor, Veterinary Clinical Complex, College of Veterinary Science, Sri Venkateswara Veterinary University, Tirupati, Andhra Pradesh, India

A Nasreen,
Department of Veterinary Pathology, College of veterinary Science, Srivenkateswara Veterinary University, Tirupati, Andhra Pradesh, India

CH Srilatha
Professor and University head, Department of Veterinary Pathology, College of Veterinary Science, Proddatur, Andhra Pradesh, India

K Sujatha
Department of Veterinary Pathology, College of Veterinary Science, Srivenkateswara Veterinary University, Tirupati, Andhra Pradesh, India

Corresponding Author:
A Anand Kumar
Professor and Head, Department of Veterinary Pathology, College of Veterinary Science, Sri Venkateswara Veterinary University, Tirupati, Andhra Pradesh, India

A case report of haemangiosarcoma form of leukosis complex in birds effected with Marek's disease

Y Vishnu Prasanth Reddy, A Anand Kumar, P Amaravathi, A Nasreen, CH Srilatha and K Sujatha

Abstract
Six BV 380 layer strain birds of 100 day old were presented to department of Veterinary Pathology, College of Veterinary Science, Tirupati for necropsy examination. Birds had shown the clinical signs of dullness, depression, anorexia, emaciation and nervous signs prior to death as informed by the owner. Grossly, nodular lymphoid masses of varied sizes in heart, lungs, spleen, kidney, proventriculus, intestine, ovary were noted. Impression smears revealed the presence of mixed population of pleomorphic small to large lymphocytes, lymphoblasts, plasma cells. Histopathological examination revealed focal to diffuse infiltration of the pleomorphic lymphoid cells in the liver, spleen, lung, proventriculus and loss of normal archetecture was observed. Huge cavernous spaces lined by neoplastic endothelial cells packed with the RBC were noticed and confirmed as haemangiosarcoma a form of leucosis complex in the birds affected with Marek's disease effected birds.

Keywords: hemangiosarcoma, histopathology, marek's disease, poultry

Introduction
Neoplastic disease conditions of poultry fall into two broad classes, with infectious and non-infectious etiologies. The neoplasms with the infectious etiology are of greater economic importance as commercial poultry stock are being affected. Three main classes of virus causing neoplasms of lymphatic tissues in poultry are a) Marek's disease virus (MDV), a herpes virus b) Avian leukosis virus (ALV), a retrovirus c) Reticuloendotheliosis virus (REV) (Biswas *et al.*, 2018). Marek's disease (MD) is a lymphoproliferative disease of chicken and other domesticated and wild birds caused by herpes virus. Marek's disease of fowls is a panzootic caused by a herpesvirus which induces tumorous growths in various organs and tissues. It cause major economic threat to flocks of young adult fowls. In chickens, MD can occur at any time, beginning at 3–4 weeks of age or older, sometimes even well after the onset of egg production. Hemangiosarcomas are malignant tumors and they typically metastasize widely, especially in to the lungs (Meuten, 2002) [5].

Material and Methods
Six dead BV 380 layer strain 100 day old birds were presented for necropsy to the Department of Veterinary Pathology, College of Veterinary Science, Tirupati. Impression smears of liver and spleen were taken and stained with Leishman's stain for cytological study. Tissues like proventriculus, liver, spleen and lungs where the lesions observed were collected and preserved in 10% neutral buffered formalin for histopathological examination. Then preserved tissues were processed through various steps dehydration, clearing and embedding and 5 microns thick sections were cut with the help of microtome and these sections were mounted on a clear glass slide. Then sections were stained with Hematoxylin and Eosin and examined under microscope (Culling, 1974) [2].

Results
A small commercial growing unit having 2000 birds with history of approximately 80 birds died over the previous 5-6 weeks and mortality rate was 2-5 birds per day presented six dead birds of 100 day old for necropsy at department of Veterinary Pathology, College of Veterinary Science, Tirupati. The birds showed the clinical signs of dullness, depression, anorexia, emaciation and showed nervous signs immediately before death as informed by the owner.

Grossly, the birds were emaciated with poor body condition and up on internal examination revealed lymphoid nodular growths of varied sizes mainly in the liver, heart, lungs, spleen, kidney, proventriculus, ovary. Liver was enlarged, bright red in color and completely filling the whole abdominal cavity with nodular to diffuse multifocal lymphoid masses of various sizes. Spleen was enlarged along with multifocal nodular growths on the surface. Thickened proventriculus along with haemorrhages. Lungs were enlarged and consolidated along with blonchy areas of haemorrhages. Grossly no lesions were observed in the brain and peripheral nerves.

Impression smears were collected form the organs showing the lymphoid growths and on staning and examination revealed mixed population of pleomorphic small to large lymphocytes, lymphoblasts, plasma cells in the heart, liver, spleen.

Histologically, in the liver revealed focal to diffuse infiltration of the pleomorphic lymphoid cells, degeneration and necrosis was noted in the hepatocytes and also there was proliferation of the neoplastic endothelial cells were observed in between the hepatic cords in the liver. Fibrous tissue proliferation was observed in the spleen along with infiltration of the pleomorphic lymphoblast cells. Pleomorphic lymphoid cells were observed in between the proventricular glands. Loss of normal archetecture was observed in the organs affected. Huge cavernous spaces lined by endothelial cells and packed with the RBC were observed in the lungs. Infiltration of the neoplastic endothelial cells along with pleomorphic lymphoid cells was observed in the proventriculus.

Discussion

These observations of dullness, depression, anorexia, emaciation and nervous signs before death were similar to clinical signs reported by Fujimato *et al*. (1971) [3], Ali *et al*. (2014) [1], Sawale *et al*. (2014) [8] with Marek's disease and Rajkhowa and Arya (2016) [7] with haemangiomas in chicken. Impression smears were collected form the organs showing the lymphoid growths and on staning and examination revealed mixed population of pleomorphic small to large lymphocytes, lymphoblasts, plasma cells in the heart, liver, spleen are in line with previous reports on Marek's disease by Das *et al*. (2018) and Kumar *et al*. (2018) [4]. Grossly, enlargement of organs with lymphoid nodular growth was similar to the observations by previous authors Ali *et al.* (2014) [1] and Vishnuvinayagam *et al.* (2019), Kumar *et al.* (2018) [4], Namratha *et al.* (2019) [6] with respect to Marek's disease. Bright red color organs with blonchy haemorrhages on the lungs and haemorrhages in the proventriculus was similar to the observations of Vamsi krishna (2015) [10] in relation to hemangisarcoma. Focal to diffuse infiltration of the pleomorphic lymphoid, proliferation of the neoplastic endothelial cells, fibrous tissue proliferation was observed in the liver, spleen and proventriculus and huge cavernous spaces lined by endothelial cells and packed with the RBC in the lungs were similar to observations of Marek's disease effected birds by Swathi *et al.* (2012) [9], Ali *et al*. (2014) [1] and Visnuvinayagam *et al.* (2019 [11] the neoplastic endothelial cells proloferation was similar to the findings of the previous records by Vamsi krishna (2015) [10] and Meuten (2002) [5].

Fig 1: Photograph showing bright red color liver with diffuse focal nodules, blonchy hemorrhages and consolidated areas on the lungs, cauliflower like growths on the ovary, pale heart.

Fig 2: Photograph of liver showing bright red color liver with nodular growths on the surface.

Fig 3: Photograph showing the thickened proventriculus along with hemorrhages in the mucosa and pale heart.

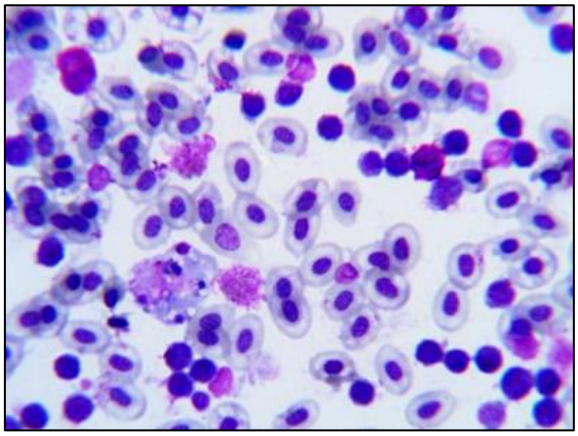

Fig 4: Cytological smear of liver showing pleomorphic lymphoid cells. Leishman's stain x 1000

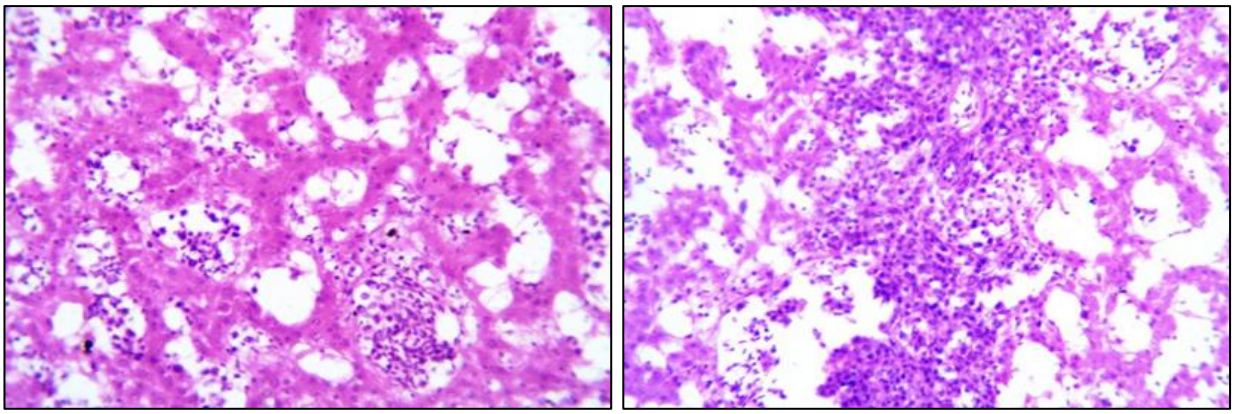

Fig 5,6: Histological section of liver showing severe infiltration of pleomorphic lymphoid cells along with neoplastic endothelial cells in between the hepatocytes. H&E: X400.

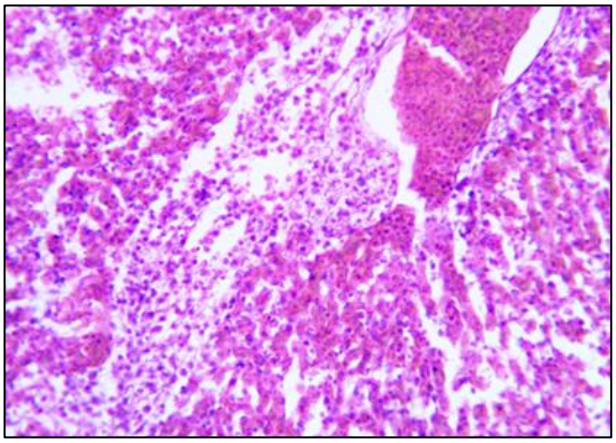

Fig 7: Histological section of lungs showing severe hemorrhages along with spindle shaped plumpy neoplastic endothelial cells in the lung parenchyma. H&E: X400.

Conclusion

The present study indicated haemangiosarcoma a form of leucosis complex is an incidental finding in the birds affected with Marek's disease.

Acknowledgement

Authors are thankful to authorities of Sri Venkateswara Veterinary University for providing the facilities.

References

1. Ali A Moniem A, RA El-Attar ES, H Mohamed M, M Abdel Ghany H. Comparative Diagnostic Studies on Marek's Disease in chickens by Use of Histopathology and Molecular Investigation. Zagazig Veterinary Journal 2014;42(3):225-241.
2. Culling CFA. Handbook of Histopathological and Histochemical Techniques. Edn 1974;3:214.

3. Fujimoto Y, Nakagawa M, Okada K, Okada M, Matsukawa K. Pathological studies of Marek's disease: The histopathology on field cases in japan. Japanese Journal of Veterinary Research 1971;19(1-2):7-26.
4. Kumar MA, Palanivelu M, Barathidasan R, Kumar D, Singh SD, Lateef SK, *et al*. Cytological and immunocytological detection and differentiation of Marek's disease and lymphoid leucosis in poultry. Virus Disease 2018;29(3):349-354.
5. Meuten DJ. Tumors in domestic animals. Edn 4, Iowa State Press 2002, Pp:55
6. Namratha ML, Reddy KAK, Kumar YR, Lakshman M. Marek's disease outbreak in adult Rajasri layer chicken. Journal of Entomology and Zoology Studies 2019;7(4):1326-1328.
7. Rajkhowa TK, Arya RS. Concurrent occurrence of haemangioma and hepatocellular carcinoma in layer chicken–A case report. Indian Journal of Veterinary Pathology 2016;40(1):96-98.
8. Sawale GK, Shelke VM, Kinge GS. Observation on occurrence of neural form of Marek's disease in desi chickens. Indian Journal of Veterinary Pathology 2014;38(2):94-97.
9. Swathi B, Kumar AA, Reddy MR. Histological and molecular diagnosis of poultry tumours. Indian Journal of Veterinary Pathology 2012;36(1):41-48.
10. Vamsi Krishna A Pathomorphological, immunohistochemical and molecular studies on avian tumors. Thesis submitted to the Sri Venkateswara Veterinary University, Tirupati 2015.
11. Visnuvinayagam S, Dash BB, Barathidasan R, Mayilkumar K, Selvaraju G. Anatomopathological and molecular studies of Mareks disease virus in India. Brazilian Journal of Veterinary Pathology 2019;12(2):33-40.