The Pharma Innovation Journal 2021; SP-10(2): 243-248

www.ThePharmaJournal.com

The Pharma Innovation

ISSN (E): 2277- 7695
ISSN (P): 2349-8242
NAAS Rating: 5.23
TPI 2021; SP-10(2): 243-248

www.thepharmajournal.com
Received: 11-12-2020
Accepted: 15-01-2021

Manojkumar Villavan
Division of Animal Nutrition, Indian Veterinary Research Institute, Izatnagar, Uttar Pradesh, India

Gopi Marappan
Division of Avian Physiology and Reproduction, ICAR-Central Avian Research Institute, Izatnagar, Uttar Pradesh, India

Jaydip Jaywant Rokade
Division of Avian Genetics and Breeding, ICAR-Central Avian Research Institute, Izatnagar, Uttar Pradesh, India

Shyam Kumar
Division of Veterinary Pharmacology and Toxicology, ICAR-Indian Veterinary Research Institute, Izatnagar, Uttar Pradesh, India

Corresponding Author
Manojkumar Villavan
Division of Animal Nutrition, Indian Veterinary Research Institute, Izatnagar, Uttar Pradesh, India

Effect of nucleoside supplementation through feed in digestive enzymes and gut health in broilers

Manojkumar Villavan, Gopi Marappan, Jaydip Jaywant Rokade and Shyam Kumar

Abstract
An experiment was conducted to study the effect of nucleotides in digestive enzymes and intestinal growth**.** A total 240 chicks which belongs to the broiler breed CARIBRO VISHAL were used for this study. All the chicks were divided into 6 groups 40 birds in each group. T1 served as Control. T2, T3, T4 and T5 groups were supplemented with Adenosine, Guanosine, Cytosine and Uridine @ 0.1 % respectively. Group T6 was supplemented with combination of all four nucleoside (Adenosine, Guanosine, Cytosine and Uridine) bases each at 0.1%. The bases were administered through feed for initial 14d of age. The results indicated that the plasma amylase activity was significantly higher in T6 group (P<0.05). Plasma lipase activity was significantly higher in cytosine supplemented group, followed by T6. Results of intestinal growth parameters showed that nucleoside supplemented groups had higher intestinal villi growth than control group. T6 had siginificantly higher intestinal villi growth ((P<0.05) than other groups. From this study it was concluded that chicks that supplemented with combination of nucleosides had better gut health.

Keywords: nucleosides, gut health, histo-morphology, digestive enzymes, broiler chickens

1. Introduction
Poultry production in India has taken a quantum leap over the last four decades. It has completed its journey from backyard system to a fully automatic farming system, culminating into a high profile industry. The growth performance and meat yield of commercial broilers has improved linearly each year with greater input efficiency [6]. Hence, many research works are focussing to promote the health of chickens and to increase the production. Nucleotides are intracellular compounds with low molecular weight that are required for almost all biochemical processes. Nucleotides are essential nutrients involved in gut development and repair, skeletal muscle development, heart function and immune response [5]. Nucleotide increases the development of the villi, intestinal wall thickness, protein content, and DNA and RNA contents [15]. They are important in the development of enzymes in the intestinal brush border [15]. The tissues such as immune and intestinal mucosa cells requires these nucleotides higher than denova synthesis due to their rapid proliferation rate [14]. Nucleotide absorbed in the intestine as nucleoside [4]. Thus, effects of individual nucleosides and their combination were supplemented through feed and on enhancing digestive enzymes activity and gut health parameters in broilers were studied.

2. Material and Methods
The current experiment was carried out in ICARCentral Avian Research Institute, Bareilly. A total 240 chicks which belongs to the broiler breed CARIBRO VISHAL were used for this study. All the chicks were divided into 6 groups, T1: Control, T2: Adenosine (0.1%); T3: Guanosine (0.1%); T4: Cytosine (0.1%); T5: Uridine (0.1%) and T6: Combination of all four nucleoside (Adenosine, Guanosine, Cytosine and Uridine) bases each at 0.1%. The bases were administered through feed for initial 14d of age. After 14 days all the 6 groups were fed with standard diet (ICAR, 2013) for the trial period (Table 1) upto 42d of age. Birds were sacrificed at the end of 7, 14 and 42nd d of experiment to study intestinal development.

2.1 Digestive enzyme activities
The activities of digestive enzymes *viz.*, α-amylase, lipase were assessed in blood plasma using the commercial kits provided by the Coral Clinical systems, India.

2.2 Gross intestinal morphology
Intestinal length and weight was measured after slaughter on each week to study the effect of nucleotide supplementation on the development of intestine in broilers.

2.3. Intestinal histo-morphometry
Segments of jejunum were collected after slaughter and store in 10% formalin solution for histo-morphometrical analysis. Histological sections were analysed under 10x of compound microscope. Length, width and crypt depth of villi were measured using MOTIC 2.0 software.

2.4. Statistical analysis
The results were subjected to analysis of variance single factor using SPSS version 20.0 and the means were compared with Tukey's range test for significance (P<0.05).

3. Results and Discussion
3.1. Digestive enzymes activity
On second week, the plasma amylase activity was significantly higher in the combination supplemented group, followed by cytosine supplemented group (Table 1). Plasma lipase activity was significantly higher in cytosine supplemented group, followed by chicks supplemented with combination of nucleosides. Amylase and lipase were important enzymes in the digestion of carbohydrates and fat respectively. Both the enzymes activity was increased in nucleoside supplemented groups.

Supplementation of nucleosides which can be converted to nucleotides may involve tissue function in the GI tract and stimulate brush border enzymes activity [11]. Increase in the activity of brush border and pancreatic enzymes leads to increase in the digestion and absorption of nutrients.

Table 1: Effect of individual and combination of nucleosides feeding on plasma digestive enzymes in broiler chicks

Group	14th day	
	Amylase (U/L)	Lipase (U/L)
I	511.96^{c}±12.02	104.20^{d}±05.81
II	562.82^{bc}±14.61	119.51^{cd}±13.21
III	610.00^{ab}±16.44	162.63^{ab}±13.96
IV	648.67^{a}±14.27	190.72^{a}±07.20
V	626.28^{ab}±34.20	144.27^{bc}±04.01
VI	653.32^{a}±10.55	174.52^{ab}±06.67
SEM	10.30	5.70
P-value	0.001	0.001

3.2. Intestinal gross morphology (length and weight)
During first week, a significant increase in the length of intestines was observed in chicks supplemented with combination of nucleotides, while the intestinal weight was significantly reduced (Table 2). Significant increase in intestinal weight was observed during first week in chicks supplemented with adenosine, compared to other nucleosides and their combination.

During 14th day slaughter, there was no significant difference in either intestinal weight or length in all groups. On final slaughter after 42 days, significant increase in intestinal length was observed in combination supplemented group, followed by adenosine supplemented group.

The positive effect on the gastrointestinal tract in animals fed the diet supplemented with dietary nucleosides may be due to enhanced DNA and RNA synthesis by increasing the nucleotide pools. Increase in the synthesis of DNA and RNA enhances growth and differentiation of the enterocytes after injuries or malnutrition [3, 15]. These entire factors may be contributing in increasing intestinal length and weight.

Table 2: Effect of individual and combination of nucleosides feeding on intestinal length and weight in broiler chicks

Group	7d		14d		42d	
	Intestinal weight (g/kg bwt)	Intestinal length (cm/kg bwt)	Intestinal weight (g/kg bwt)	Intestinal length (cm/kg bwt)	Intestinal weight (g/kg bwt)	Intestinal length (cm/kg bwt)
I	14.28^{b}±0.53	81.01^{b}±1.99	13.16±0.56	46.19±1.72	81.25±2.96	171.00^{b}±2.29
II	16.98^{a}±0.49	85.83^{b}±3.72	12.37±0.48	43.58±0.86	86.00±3.40	181.50^{ab}±2.05
III	14.22^{b}±0.36	80.36^{b}±0.67	11.96±0.62	50.19±2.21	87.50±3.20	176.25^{b}±5.55
IV	14.42^{b}±0.05	90.12^{b}±2.08	12.84±0.60	50.27±2.71	85.50±3.05	176.75^{b}±2.79
V	14.17^{b}±0.13	98.84^{ab}±4.73	12.34±0.50	49.07±1.65	91.75±4.01	176.25^{b}±1.79
VI	12.61^{c}±0.39	117.91^{a}±9.38	13.78±0.30	46.72±2.01	90.75±2.43	186.50a±4.06
SEM	0.24	2.63	0.22	0.83	0.54	1.24
P-value	0.001	0.001	0.179	0.125	0.221	0.033

3.3. Intestinal histo-morphometry
On intestinal histo-morphometry analysis, a significant increase in the villi length of jejunum was observed in group supplemented with combination of nucleosides, consistently on first week, second week and on final slaughter after 42 days. Crypt depth was significantly reduced in all supplemented groups compared to control group after 7, 14 and 42 days. Villi diameter didn't show significant change after 42 days in any groups, while it was lower in nucleoside combination supplemented group on first week compared to other groups. In all groups, on final slaughter after 42 days, significant increase in intestinal villi length was observed in combination supplemented group, followed by adenosine supplemented group.

Similar to our current findings, [15] reported that protein levels in mucosal contents, enzymes activity and villi length were increased in weanling rats which was fed with 0.8% w/w of nucleotides in diet. In a study group supplemented with 0.25% Torula yeast and 2% Nupro, had longer villi length than the unsupplemented control [9]. The increase in length of intestinal villi has been attributed to improve the feed efficiency in broiler [1, 10, 12, 13]. Nucleosides increases villi length of small intestine through rapid cell turnover which allows chicks to utilise nutrients more efficiently in their early life and improve growth performance [2]. Increased villus height has been correlated to increased performance due to improving nutrient absorption [8]. All these effects were due to the administration of nucleosides which were converted to nucleotides after absorption.

Table 3: Effect of individual and combination of nucleosides feeding on Intestinal morphometric (µm) changes in broiler chicks

Group	7d			14d			42d		
	VL	VD	CD	VL	VD	CD	VL	VD	CD
I	505.35^{c} ±6.36	91.21^{b} ±2.42	170.46^{a} ±10.38	338.70^{b} ±2.45	85.80^{bc} ±4.37	138.38^{a} ±7.59	801.35^{c} ±7.69	105.79 ±4.38	212.45^{a} ±3.84
II	600.21^{ab} ±13.99	91.37^{b} ±0.98	165.41^{a} ±10.71	382.93^{b} ±9.18	69.88^{c} ±2.86	125.01^{b} ±8.85	791.06^{c} ±10.73	93.65 ±9.52	179.97^{bc} ±13.54
III	597.66^{ab} ±10.73	106.45^{ab} ±4.32	144.60^{ab} ±2.74	411.43^{b} ±11.01	100.52^{ab} ±8.20	135.78^{ab} ±8.39	875.15^{bc} ±3.65	105.52 ±1.39	203.70^{ab} ±0.11
IV	562.00^{bc} ±14.68	92.50^{b} ±3.74	142.00^{ab} ±7.35	393.44^{b} ±14.21	118.03^{a} ±8.46	133.31^{b} ±12.35	920.38^{ab} ±14.32	98.20 ±1.89	179.00^{c} ±0.68
V	613.66^{ab} ±14.07	123.40^{a} ±9.43	155.80^{ab} ±5.92	404.43^{b} ±2.46	69.39^{c} ±1.97	107.53^{b} ±2.29	816.11^{c} ±24.56	96.58 ±5.46	184.20^{bc} ±0.83
VI	640.81^{a} ±1.61	84.23^{b} ±6.78	129.71^{b} ±6.75	782.13^{a} ±16.21	74.77^{c} ±2.74	103.19^{b} ±3.88	986.80^{a} ±47.33	110.98 ±1.48	176.08^{c} ±2.74
SEM	4.57	2.82	3.64	2.85	3.34	5.73	13.65	2.11	2.92
P-value	0.001	0.001	0.005	0.01	0.01	0.01	0.001	0.135	0.001

VL: villi length; VD: villi diameter; CD: crypt depth.

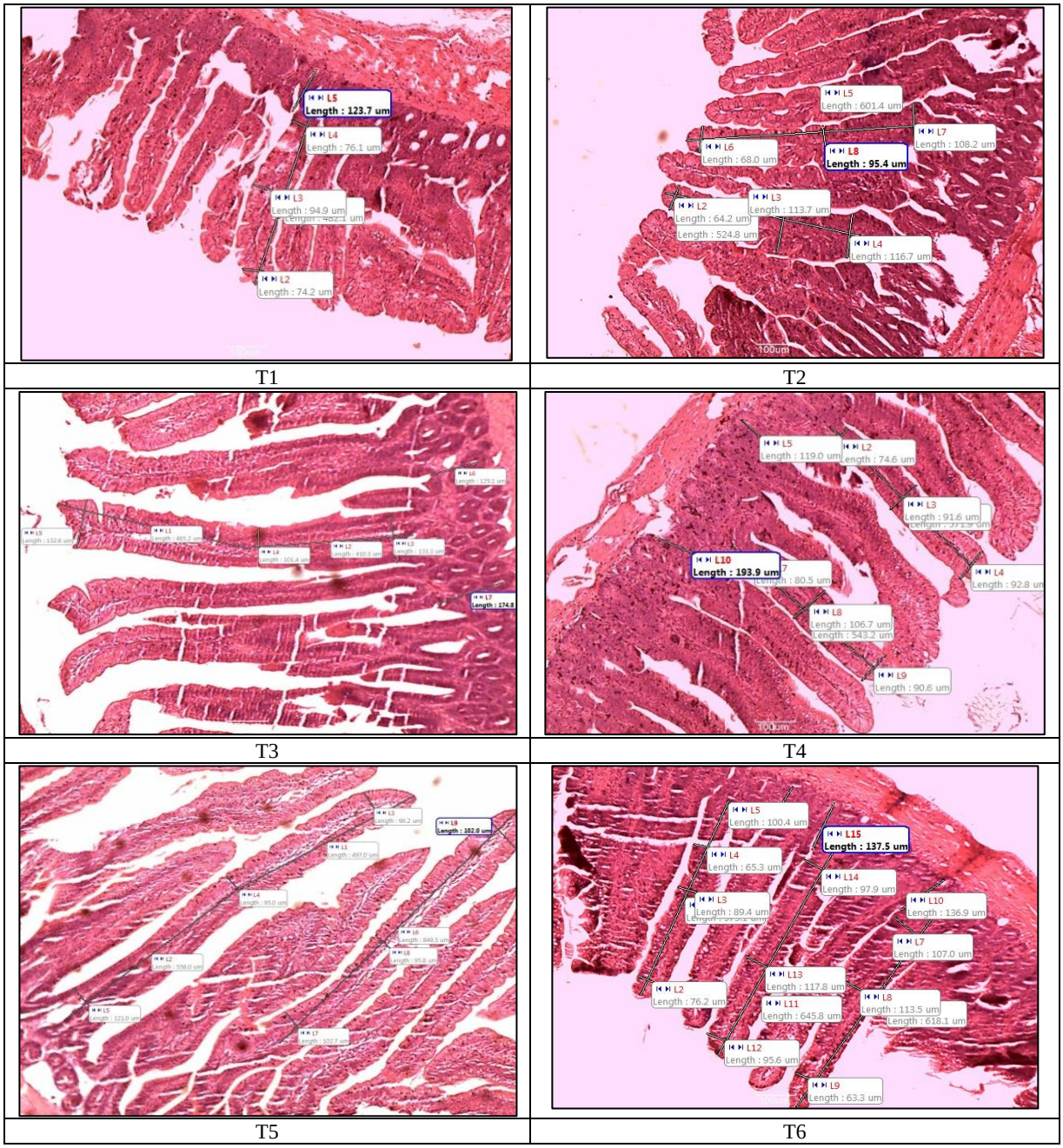

Fig 1: Histo-morphological changes in jejunum fed with individual and combination of nucleosides in broilers (7d)

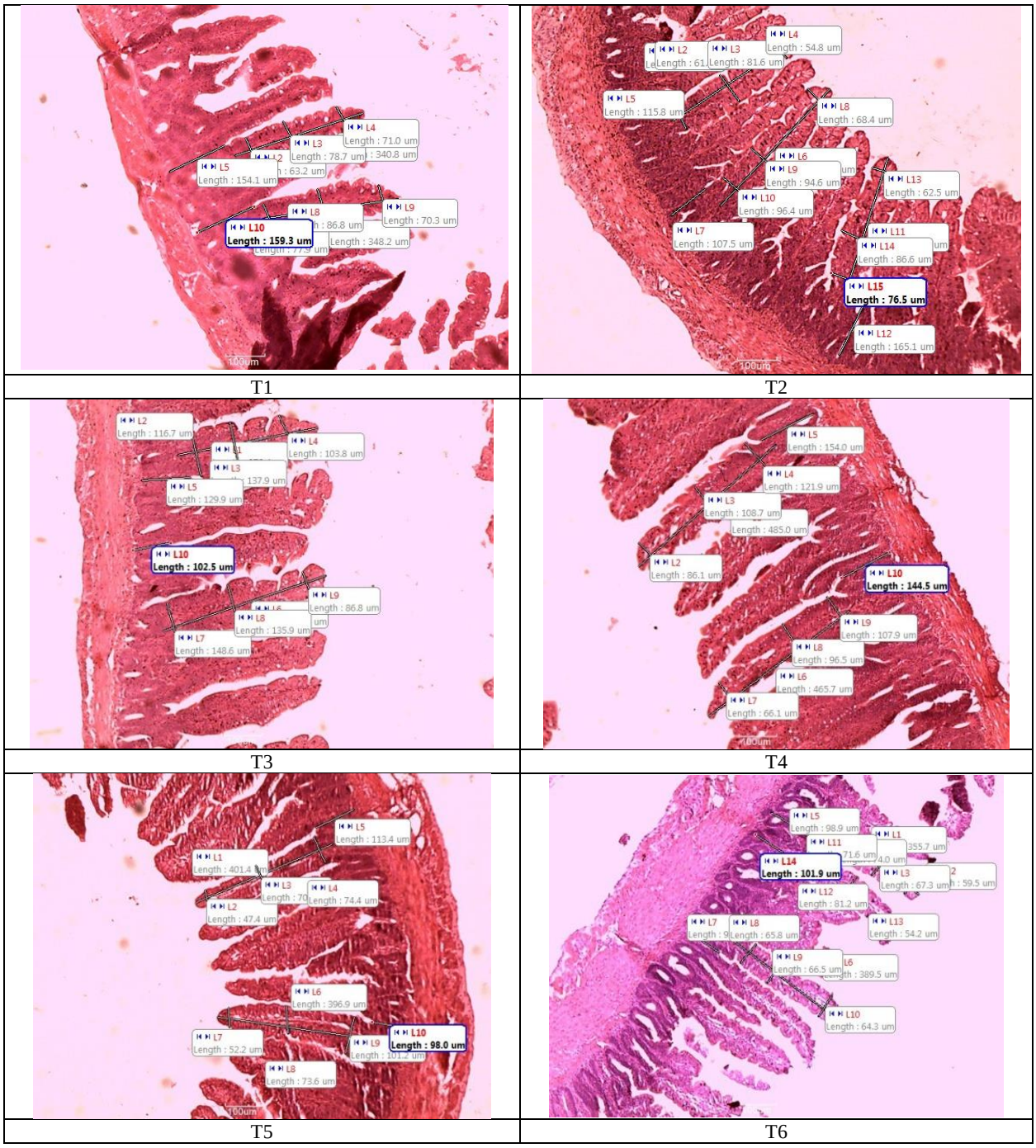

Fig 2: Histo-morphological changes in jejunum fed with individual and combination of nucleosides in broilers (14d)

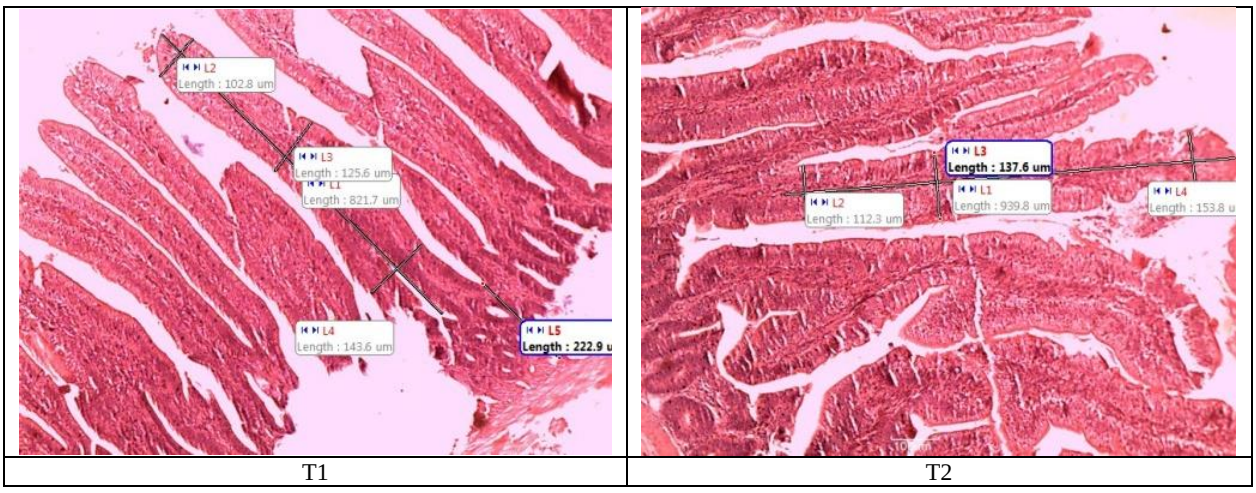

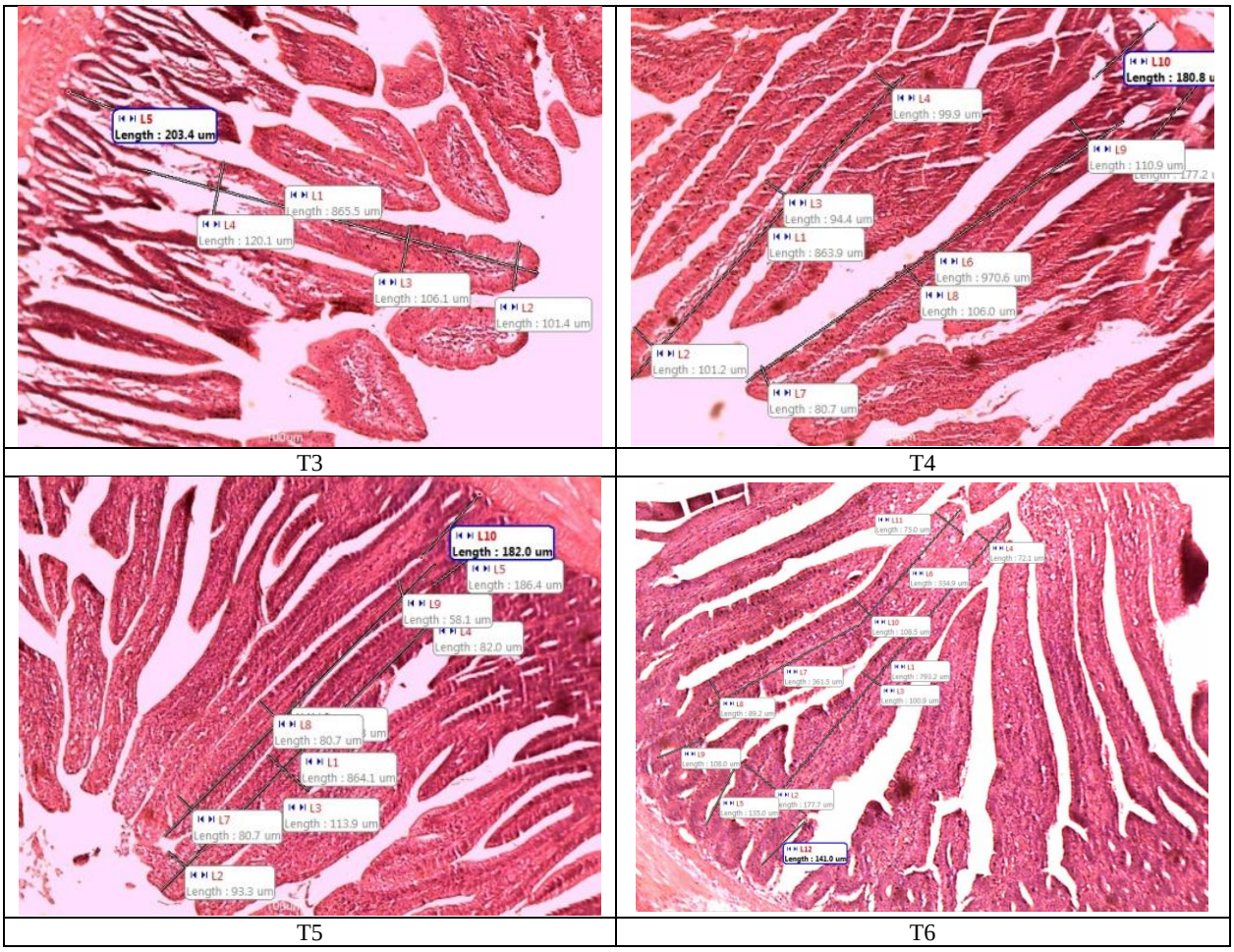

Fig 3: Histo-morphological changes in jejunum fed with individual and combination of nucleosides in broilers (42d)

4. Conclusion

Based on the present study, it was found that nucleoside supplementation improved the digestive enzyme activity and intestinal growth. Among the supplemented groups, T6 which was fed with combination of nucleosides– adenosine, guanosine, cytosine and uridine performed better than supplementing individual nucleosides in broiler chicks, for enhancing the gut development. Intestinal development leads to increase in the digestion and feed efficiency in broilers.

5. References

1. Awad WA, Böhm J, Razzazi-Fazeli E, Ghareeb K, Zentek J. Effect of addition of a probiotic microorganism to broiler diets contaminated with deoxynivalenol on performance and histological alterations of intestinal villi of broiler chickens. Poultry science 2006;85(6):974-9.
2. Bartell SM, Batal AB. The effect of supplemental glutamine on growth performance, development of the gastrointestinal tract, and humoral immune response of broilers. Poultry science 2007;86(9):1940-7.
3. Bueno J, Torres M, Almendros A, Carmona R, Nunez MC, Rios A, *et al*. Effect of dietary nucleotides on small intestinal repair after diarrhoea. Histological and ultrastructural changes. Gut 1994;35(7):926-33.
4. Carver JD, Walker WA. The role of nucleotides in human nutrition. The Journal of Nutritional Biochemistry 1995;6(2):58-72.
5. Grimble GK, Westwood OM. Nucleotides. In Nutrition and Immunology. Humana Press, Totowa, NJ 2000, 135-144.
6. Havenstein GB, Ferket PR, Qureshi MA. Growth, livability, and feed conversion of 1957 versus 2001 broilers when fed representative 1957 and 2001 broiler diets. Poultry science 2003;82(10):1500-1508.
7. ICAR. Nutrient Requirements of poultry. Indian Council of Agricultural Research, New Delhi, India 2013.
8. Izat AL, Thomas RA, Adams MH. Effects of dietary antibiotic treatment on yield of commercial broilers. Poultry Science 1989;68(5): 651-5.
9. Jung B, Batal AB. Effect of dietary nucleotide supplementation on performance and development of the gastrointestinal tract of broilers. British poultry science. 2012;53(1):98-105.
10. Kumar S, Yadav SP, Chandra G, Sahu DS, Kumar R, Maurya PS, *et al*. Effect of dietary supplementation of yeast (Saccharomyces cerevisiae) on performance and hemato-biochemical status of broilers. Indian Journal of Poultry Science 2019;54(1):15-9.
11. Manojkumar V, Gopi M, Rokade JJ, Shyamkumar TS, Prabakar G, Beulah PV, *et al*. Oral administration of nucleosides improved the performance and gut health in broiler chickens. Indian Journal of Poultry Science 2020;55(1):37-41.
12. Samanya M, Yamauchi KE. Histological alterations of intestinal villi in chickens fed dried Bacillus subtilis var. natto. Comparative Biochemistry and Physiology Part A: Molecular & Integrative Physiology 2002;133(1):95-104.
13. Samli HE, Senkoylu N, Koc F, Kanter M, Agma A. Effects of *Enterococcus faecium* and dried whey on broiler performance, gut histomorphology and intestinal microbiota. Archives of animal nutrition 2007;61(1):42-

9.
14. Uauy R, Quan R, Gil A. Nucleotides in infant nutrition. In: Nutritional and Biological Significance of Dietary Nucleotides and Nucleic Acids, ed. A Gil and R Uauy. Barcelona: Doyma 1996, 169-180.
15. Uauy R, Stringel G, Thomas R, Quan R. Effect of dietary nucleosides on growth and maturation of the developing gut in the rat. Journal of pediatric gastroenterology and nutrition 1990;10(4):497-503.