



ISSN (E): 2277- 7695

ISSN (P): 2349-8242

NAAS Rating: 5.03

TPI 2021; SP-10(1): 42-45

© 2021 TPI

www.thepharmajournal.com

Received: 12-11-2020

Accepted: 20-12-2020

Ram Niwas

Department of Veterinary
Surgery and Radiology,
Lala Lajpat Rai University of
Veterinary and Animal Sciences,
Hisar, Haryana, India

Sandeep Saharan

Department of Veterinary
Clinical Complex
Lala Lajpat Rai University of
Veterinary and Animal Sciences,
Hisar, Haryana, India

Priyanka

Department of Veterinary
Surgery and Radiology,
Lala Lajpat Rai University of
Veterinary and Animal Sciences,
Hisar, Haryana, India

Sandeep Kumar

Scientist, Department of
Veterinary Surgery and
Radiology, College of Veterinary
Sciences, Lala Lajpat Rai
University of Veterinary and
Animal Sciences, Hisar,
Haryana, India

Corresponding Author:**Sandeep Kumar**

Scientist, Department of
Veterinary Surgery and
Radiology, College of Veterinary
Sciences, Lala Lajpat Rai
University of Veterinary and
Animal Sciences, Hisar,
Haryana, India

Ultrasound guided tube cystotomy in buffalo calves

Ram Niwas, Sandeep Saharan, Priyanka and Sandeep Kumar

DOI: <https://doi.org/10.22271/tpi.2021.v10.i1Sa.5504>

Abstract

The present study was under taken to evaluate the efficacy of ultrasound guided tube cystotomy in male buffalo calves with intact and turgid urinary bladder. All these calves have pulsating urethra. Frequent micturition posture along with twitching of urethra observed from two to three days. Tube cystotomy was done by minimum stab incision under sonographic examination. Early recovery with minimum complication was noticed in most of buffalo calves by this technique. This study concluded that ultrasonography guided tube cystotomy is safe and reliable technique for treatment of retention of urine in buffalo calves with intact urinary bladder.

Keywords: Buffalo calves, retention of urine, tube cystotomy, ultrasonography

Introduction

Urinary obstruction is a major complication in growing calves during or just after end of winter season due to less water intake (Amarpal *et al.* 2004) ^[1]. It is multi factorial clinical condition in which sex, age, season, water, breed, soil, hormone, urinary tract infections (Udall and Chow, 1969) ^[22] and minerals, particularly excessive or imbalanced intake of calcium, phosphorus and magnesium (McIntosh 1978) ^[12] plays important role in the pathogenesis. Both sexes seems to be equally affected however due to anatomical difference of urinary tract, it is primary problem of males (Larson, 1996; Radostits *et al.*, 2000) ^[7, 15]. Briefly, the disease is characterized by restlessness, inappetence to anorexia, pulsating urethra, frequent attempt to urinate and maintaining urinating posture (Mangotra *et al.*, 2016) ^[9]. Multiple surgical options are available including urethroscopy and laser lithotripsy (Halland *et al.*, 2002) ^[5], tube cystostomy (Rakestraw *et al.*, 1995; Ewoldt *et al.*, 2006) ^[17, 4], urethrotomy (Singh *et al.*, 2010) ^[18], perineal urethrostomy (Van Weeren *et al.*, 1987) ^[23] and bladder marsupialisation (May *et al.*, 1998) ^[11]. Tube cystotomy is a fast and easier procedure particularly in intact urinary bladder where Foley's catheter could be inserted bluntly into the urinary bladder (Kuswaha *et al.*, 2014; Singh *et al.*, 2014) ^[6, 19]. Ultrasonography serves as a useful diagnostic aid in assessing urinary bladder, especially in calves and small ruminants (Braun *et al.*, 1992; Singh *et al.*, 2014) ^[2, 19]. In dogs ultrasound-guided placement of a pigtail cystostomy tube may be beneficial as it is not technically challenging, can be performed rapidly, and may avoid the need for general anaesthesia (Culler *et al.*, 2019) ^[3]. With this background the present study was carried out to evaluate the efficacy of ultrasound guided tube cystotomy in buffalo calves.

Materials and methods

Buffalo calves of age between 2-4 months were included in this study that has history of urine retention from 2-3 days. All the calves were dull, depressed, having inappetance to anorexia, pulsating urethra with frequent contraction and relaxation of preputial orifice, micturition posture and dehydrated condition. After shaving of left caudo-ventral area ultrasonographic examination was done using Siemens Acuson S2000 machine with 3-4.5 MHz transducer to evaluate the shape and size of the urinary bladder, uroliths in urinary bladder, if any. During ultrasonographic examination in only ten calves, urinary bladder was found intact and fully turgid. These ten cases were selected for tube cystotomy under sonographic examination. All calves were sedated using xylazine @0.05mg/kg body weight intravenously. Surgical site was prepared by using 2% chlorhexidine scrub, followed by 70% isopropyl alcohol and ultrasonography probe was also cleaned with isopropyl alcohol before surgery.

Sonography was done again to find a locus at which urinary bladder lies very close to abdominal wall without interposition of intestine between them (Fig. 1b). Cases where intestines found in between abdominal wall and urinary bladder (Fig. 1a) a gentle pressure was Applied by using probe to facilitating escape of intestine in between urinary bladder and abdominal wall.

After locating point of insertion, 3 to 4 ml of local anaesthetic (2% lignocaine) was injected, then a stab incision was given just enough to puncture abdominal wall keeping the probe static. Blunt dissection was done to enlarge incision site to facilitate smooth entry of Foley's catheter. In three cases rectus abdominis was grasped and lifted by thumb forceps and incision was made with scissor. Then Foley's catheter no. 18 mounted on artificial insemination gun plunger acting as stylet (Fig. 2b), was made to penetrate the urinary bladder (Fig.3a). After ensuring the position of catheter ultrasonographically in the lumen of urinary bladder, balloon was inflated using 20 ml of normal saline solution to fix catheter inside bladder (Fig. 3b). Catheter was pulled towards the insertion point as balloon seals the rent to prevent urine seepage in to abdominal cavity. One horizontal mattress suture including catheter lumen was applied to the stab

incision site and free length of catheter was fixed with skin using two simple interrupted sutures.

Post operatively antibiotic ceftriaxone @ 10 mg/kg body weight (Maradiya *et al.*, 2010) ^[10], analgesic melonex @ 0.5mg/kg body weight (Papich, 2011) ^[14] for five days and ammonium chloride @ 500 mg/kg PO, q 12 h) for 20 days (Mangotra *et al.*, 2016) ^[9] was administered along with antiseptic dressing for 10 days prescribed. Owners were advised to flush catheter with diluted betadine solution to remove debris from Foley's catheter and to block urine channel of catheter for 6-12 hours daily after three days to observe dribbling through urethra. Once dribbling was noticed the period of occlusion was increased till free flow of urine observed. After attaining normal urination, catheter was removed in between 9-22 days after surgery. Suture was removed after 10-12 days after surgery.

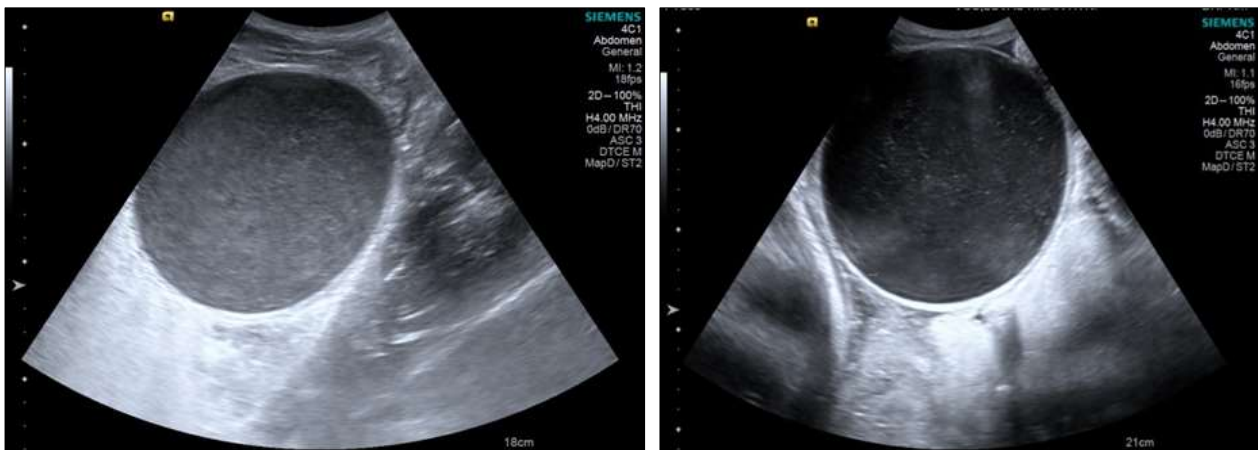


Fig 1: Showing interposed viscera (white arrow) (b) Fully turgid urinary bladder in close contact with abdominal wall

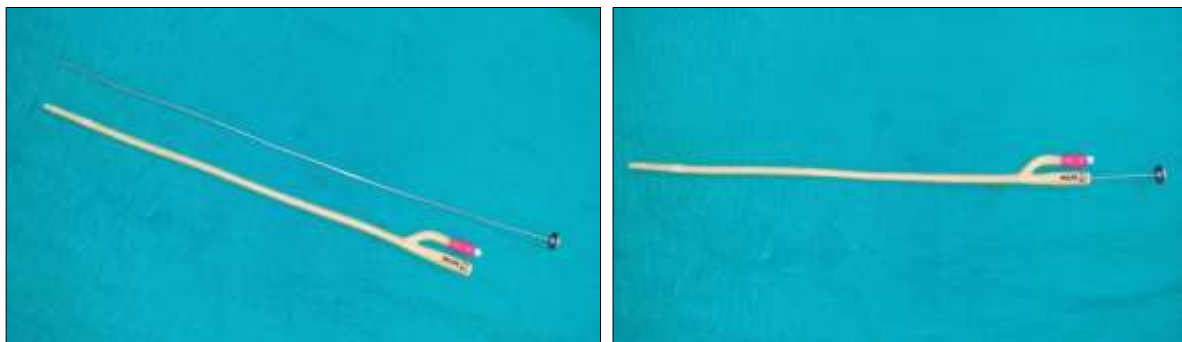


Fig 2: Foley's catheter and AI Gun plunger (as Stylet) (b) Assembled Foley's catheter and AI gun plunger

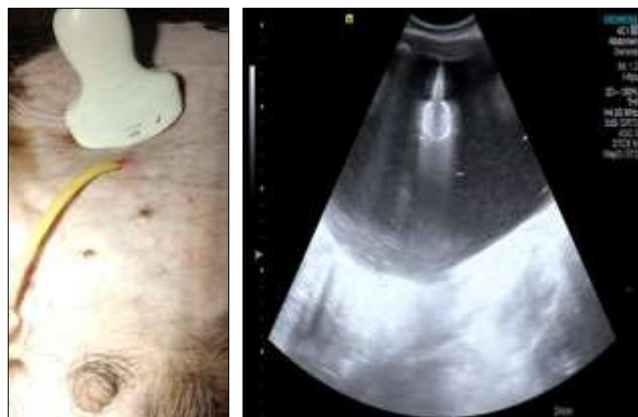

Fig 3: Ultrasound guided insertion of Foley's catheter (b) balloons inside urinary bladder

Result and Discussion

In the present study animals were dull and depressed, have Inappetance to anorectic condition and pulsating urethra which is in accordance with the findings of Mangotra *et al.* (2016)^[9]. In all the cases no complication during surgery was observed and tube cystotomy was found safe, reliable technique for retention of urine in buffalo calves. Tube cystotomy include simple procedure, preservation of the reproductive function of the animal and less tendency of recurrences of retention of urine (May *et al.*, 1998)^[11]. In all selected cases bladder was intact. Hence frequent micturition posture, presence of pulsating and twitching of urethra were reliable subjective methods to conclude presence of intact urinary bladder which was in agreement with findings of Sharma *et al.* (2007)^[20]. In two calves, blockage of Foley's catheter was observed within 7 post-operative days that also seen in conventional method of tube cystotomy (Mangotra *et al.*, 2016)^[9] may be due to improper flushing of catheter by the owner sometimes. Catheter blockade and catheter dislodgment were common post-operative complications following tube cystotomy in ruminants (Singh *et al.*, 2014)^[19]. Both these cases later on operated using conventional method of tube cystotomy and in both cases no evidence of visceral adhesions observed, as there were no/ little manipulations inside abdominal cavity was done by this technique.

Infection was observed in two cases at entry point of catheter. Subcutaneous tunnelling of catheter also leads to infection in nearly 25% cases in tube cystotomy technique (Mangotra *et al.*, 2016)^[9]. The mean time of urine dribbling was 7 days (3–14 days) and for free flow of urine from urethra was 11 days (6–20 days). The mean time for removal of Foley's catheter after recovery was 13.5 days (9–22 days) which co-related with the finding of Kushwaha *et al.* (2014)^[6]. Tube cystotomy was found to be a simple, useful technique in the management of obstructive urolithiasis in calves and small ruminants with overall success rate of 73.33% (Mahajan *et al.*, 2017)^[8]. The majority of abdominal surgery has abdominal adhesions, and yet only a small number will ever develop subsequent adhesive obstruction (Menzies and Ellis, 1990)^[13]. Approximately 85% of adhesions that cause intestinal obstruction are post-surgical, 10% are inflammatory and 5% are congenital (Raf, 1969)^[16].

Small surgical incision in abdominal cavity always leads to minimal complication then conventional surgical technique. Laparoscopic assisted cystotomy with subsequent tube cystotomy can be helpful in male small ruminants suffering from obstructive urolithiasis for removal of uroliths and debris from the urinary bladder (Streeter *et al.*, 2002)^[21].

Conclusion

Ultrasonographic guided tube cystotomy is safe, reliable, less invasive technique with minimal complications for surgical management of retention of urine in male buffalo calves. Now a day ultrasonography machine is available at various field hospitals and not much expertise is required to locate urinary bladder and adopt this technique.

References

1. Amarpal, Kinjavdekar P, Aithal HP, Pawde AM Singh T, Pratap K. Incidence of urolithiasis: A retrospective study of five years. *Indian Journal of Animal Sciences* 2004; 72(2):175-77.
2. Braun U, Schefer U, Fohn J. Urinary tract

- ultrasonography in normal rams and rams with obstructive urolithiasis. *Can. Vet. J* 1992;33:654-659.
3. Culler CA, Fick M, Viganani A. Ultrasound-guided placement of pigtail cystostomy tubes in dogs with urethral obstruction. *J Vet Emerg Crit Care (San Antonio)* 2019;29(3):331-336. doi: 10.1111/vec.12832. Epub 2019 Apr 17. PMID: 30994963.
4. Ewoldt JM, Anderson DE, Miesner MD, Saville WJ. Short- and long-term outcome and factors predicting survival after surgical tube cystostomy for treatment of obstructive urolithiasis in small ruminants. *Vet Surg* 2006;35:417-422.
5. Halland SK, House JK, George LW. Urethroscopy and laser lithotripsy for the diagnosis and treatment of obstructive urolithiasis in goats and potbellied pigs. *J Am Vet Med Assoc* 2002;220:1831-1834.
6. Kushwaha RB, Amarpal, Aithal HP, Kinjavdekar P, Pawde AM. Clinical appraisal of 48 cases of obstructive urolithiasis in buffalo calves treated with tube cystostomy and urethrotomy. *Adv. Anim. Vet. Sci* 2014;2(2):106-110.
7. Larson BL. Identifying, treating, and preventing bovine urolithiasis. *Vet. Med.* 1996;91:366-377.
8. Mahajan A, Gupta AK, Bhadwal MG, Bhat MA, Bhardwaj HR. Occurrence and management of obstructive urolithiasis in ruminants. *Journal of Animal Research* 2017;7(4):723-731.
9. Mangotra V, Singh K, Chaudhary RN, Kumar A, Tayal R. Management of obstructive urolithiasis by tube cystostomy technique in male buffalo calves. *Indian Journal of Animal Sciences* 2016;86(3):260-263.
10. Maradiya JJ, Goriya HV, Bhavsar SK, Patel UD, Thaker AM. Pharmacokinetics of ceftriaxone in calves. *Vet. Arhiv* 2010;80(1):1-9.
11. May KA, Moll HD, Wallace LM, Pleasant RS, Howard RD. Urinary bladder marsupialization for treatment of obstructive urolithiasis in male goats. *Vet Surg* 1998;27:583-588.
12. McIntosh GH. Urolithiasis in animals. *Australian Veterinary Journal* 1978;54:267-71.
13. Menzies D, Ellis H. Intestinal obstruction from adhesions—how big is the problem? *Ann R Coll Surg Engl* 1990;72:60-63.
14. Papich MG. In: *Saunders Handbook of veterinary drugs: Small and large animals*. 3rd edi Elsevier Publications 2011;469-471
15. Radostits OM, Blood DC, Gay CC, Hinchcliff KW. *Veterinary Medicine: a textbook of the diseases of cattle, sheep, pigs, goats and horses*. Baillière Tindall, London 2000;493-498.
16. Raf LE. Causes of abdominal adhesions in cases of intestinal obstruction. *Acta Chir Scand* 1969;135:73-76.
17. Rakestraw PC, Fubini SL, Gilbert RO, Ward JO. Tube cystostomy for treatment of obstructive urolithiasis in small ruminants. *Vet Surg* 1985;24:498-505.
18. Singh TP, Amarpal HP, Kinjavdekar, Pawde AM. Comparison of four surgical techniques for the management of obstructive urolithiasis in male goats. *Indian Journal of Veterinary Surgery* 2010;31:15-20.
19. Singh K, Gopinathan A, Shakya P, Bodh D, Sangeetha P. Efficacy of tube cystostomy for treatment of obstructive urolithiasis in goats with intact urinary bladder. *Ind. J. Small Rumin* 2014;20(2):74-78.
20. Sharma AK, Mogha IV, Singh GR, Aithal HP. Incidence of urethral obstruction in animals. *Indian J. Anim. Sci.*

2007;77:455-546.

21. Streeter RN, Washburn KE, McCauley CT. Percutaneous tube cystotomy and vesicular irrigation for treatment of obstructive urolithiasis in a goat. *Journal of the American Veterinary Medical Association* 2002;221:546-549.
22. Udall RH, Chow FH. The etiology and control of urolithiasis. *Adv. Vet. Sci. Comp. Med* 1969;13:29-57.
23. Van Weeren PR, Klein WR, Voorhout GR. Urolithiasis in small ruminants. A retrospective evaluation of urethrostomy. *Vet Q* 1987;9:76-83.