



ISSN (E): 2277- 7695
ISSN (P): 2349-8242
NAAS Rating: 5.03
TPI 2020; SP-9(8): 57-58
© 2020 TPI
www.thepharmajournal.com
Received: 12-06-2020
Accepted: 16-07-2020

Angeline Felicia Bora C
Department of Veterinary
Parasitology, Rajiv Gandhi
Institute of Veterinary
Education and Research, Tamil
Nadu, India

SS Das
Department of Veterinary
Parasitology, Rajiv Gandhi
Institute of Veterinary
Education and Research, Tamil
Nadu, India

C Mathivathani
Department of Veterinary
Parasitology, Rajiv Gandhi
Institute of Veterinary
Education and Research, Tamil
Nadu, India

Corresponding Author:
Angeline Felicia Bora C
Department of Veterinary
Parasitology, Rajiv Gandhi
Institute of Veterinary
Education and Research, Tamil
Nadu, India

Case report of *Babesia canis* infection in a Non-descript dog of Puducherry region

Angeline Felicia Bora C, SS Das and C Mathivathani

Abstract

A four year male non descript dog was presented with a history of pyrexia, jaundice, vomition, anorexia with severe tick infestation. On clinical examination, Rectal temperature: 104°F, pale mucus membrane, swollen lymph node, heart rate 104 bpm was observed. On blood smear examination, large round to pear shaped piroplasm of *Babesia canis* was observed.

Keywords: Dog, *Babesia canis*, microscopic examination, tick infestation

Introduction

Canine babesiosis is one of the most common haemoprotozoan diseases prevalent in dogs worldwide (Homer *et al.*, 2000) ^[1] and naturally transmitted by the tick vector *Rhipicephalus sanguineus*. *Babesia gibsoni* and *B. vogeli* which are co-endemic in India. *Babesia gibsoni* is highly pathogenic whereas *B. vogeli* is mildly pathogenic. However, co-infections of *Babesia* with *Ehrlichia*, *Hepatozoon*, *Bartonella* and *Leishmania* also have been reported in dogs (O'Dwyer *et al.*, 2001) ^[13].

Taxonomically *Babesia* is under the phylum Apicomplexa, class Aconoidasida, order Piroplasmorida, family Babesiidae (Taylor *et al.*, 2016) ^[2]. Traditionally, Babesiosis was classified based on the morphology of the piroplasm within the red blood cell as large (eg: *Babesia canis*) or small forms (eg: *Babesia gibsoni*) (Gallego *et al.*, 2016) ^[3]. Later, several species of *Babesia* were identified by molecular techniques. Previously considered large form of *Babesia* (*Babesia canis*) has been included as a distinct species namely *B. canis*, *B. rossi* and *B.vogeli* (Carret *et al.*, 1999) ^[4]. The morphological similarity of *B. rossi* and *B. vogeli* were considered as sub species of *B. canis* though differences exist in geographical distribution, vector specificity and clinical presentation (Carret *et al.*, 1999; Zahler *et al.*, 2000; Irwin *et al.*, 2009; Gallego *et al.*, 2011) ^[4, 5, 10, 6, 7]. The fourth large form of *Babesia* namely *B. bigemina* was described in North Carolina in United States (Birkenheuer *et al.*, 2004) ^[8]. On the basis of clinical importance, there are three small *Babesia* species described namely *B. gibsoni*, *B. conradae* (Kjemtrup *et al.* 2006) ^[9] and *B. microti* like species which was identified in a Spanish dog and the name was proposed as *Theileria annae* (Zahler *et al.*, 2000) ^[5, 10]. In India 17 per cent of households own domesticated dog (Sudarshan *et al.* 2001) ^[11]. The increasing population of dogs and change in climatic conditions resulted in emergence and re-emergence of tick borne diseases. In Puducherry the data or reports on incidence of babesiosis in dog is scanty. The present paper deals with an incidence of babesiosis in Puducherry urban region.

Materials and Methods

A referred case of a four year old male non descript dog from Moolakulam, Puducherry was presented with pyrexia, jaundice, vomition, anorexia with severe tick infestation. On clinical examination, Rectal temperature: 104°F, pale mucus membrane, swollen lymph node, heart rate 104 bpm was observed. The dog was screened for the presence of haemoparasites by blood smear examination. For this purpose, hair around margin of ear was clipped and disinfected with methylated spirit and sharp sterilized needle was used to prick the ear vein. Both thick and thin blood smears were prepared from ear vein. The consistency of the blood was noticed to be diluted. The smear was stained with Leishman's stain and examined under light microscope (40X) and then examined by using oil immersion objective (100X).

Results and Discussion

Microscopic examination revealed the presence of large round to pear shaped piroplasm

Babesia canis organism within RBC (Fig:1). The clinical history and microscopic examination confirmed the presence of *Babesia canis* infection. Diagnosis of *B. canis* mainly depends on the clinical signs, blood smear examination and haematological profiling (Vidotto and Trapp, 2004) [14]. Due to unspecified clinical signs and chances of false negative results in blood smear examination, molecular methods and immunodiagnostic tests are necessary to confirm and treat the infection (Solano-Gallego *et al.*, 2016) [3]. In Puducherry, probably the cases reported are very less compared to *Babesia gibsoni*.

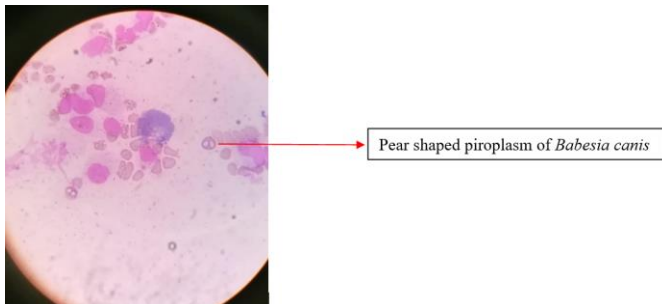


Fig 1: *Babesia canis* organism within RBC

References

- Homer MJ, Aguilar-Delfin I, Telford SR, Krause PJ, Persing DH. Babesiosis. Clin. Microbiol. Rev. 2000; 13:451-469.
- Taylor MA, Coop RL, Wall RL. Veterinary Parasitology (2nd Ed.). Set in 9/11pt Minion Pro by Aptara Inc., New Delhi, India. Terao, M., Akter, S., Yasin, M.G., Nakao, R., Kato, H., Alam, M.Z. and Katakura, K. 2015. Molecular detection and genetic diversity of *Babesia gibsoni* in dogs in Bangladesh. Infect. Genet. Evol. 2016; 31:53-60.
- Gallego LS, Sainz Á, Roura X, Estrada-Peña A, Miró G. A review of canine babesiosis: the European perspective. Parasit. Vector. 2016; 9:336.
- Carret C, Walas F, Carcy B, Grande N, Précigout É, Moubri K *et al.* *Babesia canis canis*, *Babesia canis vogeli*, *Babesia canis rossi*: differentiation of the three subspecies by a restriction fragment length polymorphism analysis on amplified small subunit ribosomal RNA genes. J Eukaryotic Microbiol. 1999; 46:298-301.
- Zahler M, Rinder H, Zwegarth E, Fukata T, Maede Y, Schein E *et al.* *Babesia gibsoni* of dogs from North America and Asia belong to different species. Parasitol. 2000; 120:365-369.
- Irwin PJ. Canine babesiosis: from molecular taxonomy to control. Parasit. vectors. 2009; 2:S4.
- Gallego LS, Baneth G. Babesiosis in dogs and cats-Expanding parasitological and clinical spectra. Vet. Parasitol. 2011; 181:48-60.
- Birkenheuer AJ, Neel J, Ruslander D, Levy MG, Breitschwerdt EB. Detection and molecular characterization of a novel large *Babesia* species in a dog. Vet. Parasitol. 2004; 124:151-160.
- Kjemtrup AM, Conrad PA. A review of the small canine piroplasms from California: *Babesia conradae* in the literature. Vet. Parasitol. 2006; 138:112-117.
- Zahler M, Rinder H, Zwegarth E, Fukata T, Maede Y, Schein E *et al.* *Babesia gibsoni* of dogs from North America and Asia belong to different species. Parasitol. 2000; 120:365-369.
- Sudarshan MK, Mahendra BJ, Narayan DH. A community survey of dog bites, anti-rabies treatment, rabies and dog population management in Bangalore city. J Commun. Dis. 2001; 33:245-251.
- Sahu A, Panda MR, Mohanty BN, Dehur M. Canine tick borne haemoprotozoan Diseases; Epidemiology, Pathogenesis and Diagnostic approaches-review. Int. J Adv. Res. 2016; 4:1134-1141.
- O'Dwyer LH, Massard CL, de Souza JCP. *Hepatozoon canis* infection associated with dog ticks of rural areas of Rio de Janeiro State, Brazil. Vet. Parasitol. 2001; 94:143-150.
- Vidotto O, Trapp SM. Babesiose canina. Rev. Bras. Parasitol. Vet. 2004; 13:58-62.