



ISSN (E): 2277- 7695

ISSN (P): 2349-8242

NAAS Rating: 5.03

TPI 2020; SP-9(7): 73-74

© 2020 TPI

[www.thepharmajournal.com](http://www.thepharmajournal.com)

Received: 07-05-2020

Accepted: 08-06-2020

## Biswadeep Jena

Assistant Professor, Department of Veterinary Surgery and Radiology, College of Veterinary Science & Animal Husbandry, OUAT, Bhubaneswar, Odisha, India

## Indramani Nath

Professor and Head, Department of Veterinary Surgery and Radiology, College of Veterinary Science & Animal Husbandry, OUAT, Bhubaneswar, Odisha, India

## Sidhartha S Behera

Assistant Professor, Department of Veterinary Surgery and Radiology, College of Veterinary Science & Animal Husbandry, OUAT, Bhubaneswar, Odisha, India

## S Dhanalaxmi

PhD Scholar, Department of Veterinary Surgery and Radiology, College of Veterinary Science & Animal Husbandry, OUAT, Bhubaneswar, Odisha, India

## Sagar Sahoo

M.V.Sc. Scholar, Department of Veterinary Surgery and Radiology, College of Veterinary Science & Animal Husbandry, OUAT, Bhubaneswar, Odisha, India

## Corresponding Author:

### Biswadeep Jena

Assistant Professor, Department of Veterinary Surgery and Radiology, College of Veterinary Science & Animal Husbandry, OUAT, Bhubaneswar, Odisha, India

## Successful surgical management of persistent right aortic arch in a dog

**Biswadeep Jena, Indramani Nath, Sidhartha S Behera, S Dhanalaxmi, and Sagar Sahoo**

### Abstract

A 70-day-old female German shepherd dog weighing 4kg brought with a history of recurrent emesis diagnosed with Persistent right aortic arch (PRAA) after contrast radiography with a barium meal. Obligation of proper surgical techniques and maintenance of adequate postoperative measures rewarded with uneventful recovery.

**Keywords:** Canine, PRAA, vascular ring anomaly, thoracotomy

### Introduction

Persistent right aortic arch (PRAA), the most common type of vascular ring anomaly that cause constriction of the esophagus. The esophagus is constricted by this vascular “ring” and begins to dilate cranially as food accumulates. Food that does not pass beyond the constriction is intermittently regurgitated. Approximately 95% of animals diagnosed with vascular ring anomalies have a persistent right aortic arch (PRAA) (Koç *et al.*, 2004; Kim *et al.*, 2006, Fossum, 2013 and Bodh *et al.*, 2015) [5, 3, 2, 1]. This communication deals with successful surgical management of persistent right aortic arch in a 4 months old Labrador puppy.

### Material s and Methods

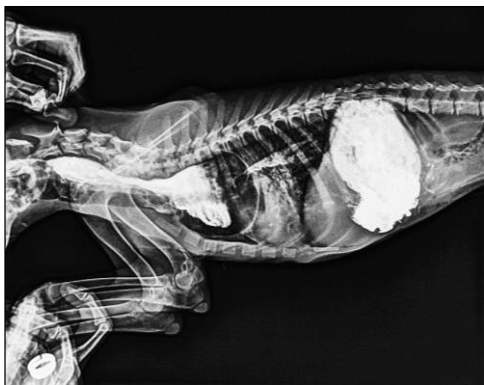A 70-day-old female German shepherd dog weighing 4 kg was brought for clinical examination of chronic recurrent post-prandial emesis for 20 days. The dog started emesis 20 days before the day of clinical presentation, at the time of weaning to solid food. The dog had no other clinical problem and its vaccination, deworming status were complete. However, the dog had reduced growth compared with its littermate. The dog was thin, underweight, and unthrifty and had a sparse hair coat. Cardiac murmurs were not detected on auscultation of the thorax. A test meal of dog food was given and the dog regurgitated masticated, nondigested food a few minutes after eating. Contrast esophagram with 15ml of 60% W/V barium sulphate suspension with milk revealed contrast material accumulating in the distended oesophagus starting caudal to thoracic inlet and ending cranial to the heart (Fig. 1), which confirmed to be PRAA. After overnight fasting, the dog was anaesthetised for exploratory thoracotomy with atropine sulphate (0.03 mg/kg, SC), followed by xylazine hydrochloride (1 mg/kg, IM) and ketamine hydrochloride (5 mg/kg, IM). Anaesthesia was maintained with 1.2% isoflurane and oxygen delivered through a #5 mm cuffed endotracheal tube which also maintained the intermittent positive pressure ventilation at 6 breaths/min with the help of an Ambu bag with a 1 lit rebreathing bag. A left fifth intercostal thoracotomy for the surgical approach to the thoracic cavity was performed. The cranial and caudal portions of the left cranial lung lobe and an adequate view of the base of the heart were packed off caudally using moistened surgical sponges. Vagal and phrenic nerves were identified and separated from the surgical site with utmost care.

The dilated portion of the oesophagus cranial to the stricture and the right of the aortic arch was apparent (Fig. 2). The aorta was seen dorsal to the oesophagus. The oesophageal fibrous bands, which were pivotal in the obstruction of the oesophagus by the persistent right aortic arch, and the ligamentum arteriosum over the stricture area were dissected with careful blind dissection after placement of stay sutures at both ends. Thoracotomy closure was accomplished by placing interrupted circumcostal sutures of 1-0 ployglactin 910 (Vicryl ®) encompassing the ribs immediately cranial and caudal to the incision. Before the final interrupted circumcostal sutures were tightened and tied, pneumothorax was eliminated by

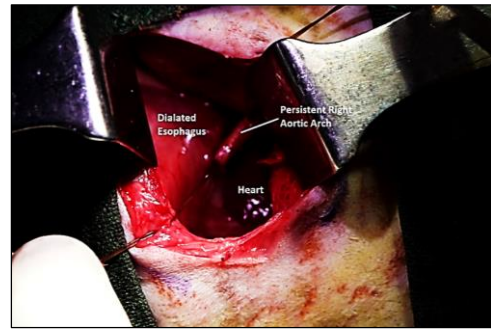
inflation and expansion of the lung to re-establish negative intrathoracic pressure. As young patients were more susceptible to hypoglycemia, oral intake was resumed within 12 to 24 hours of surgery. Initially gruel food was given in an upright posture, maintained for 5 to 10 minutes after eating to prevent distension of dilated esophagus and to re-establish esophageal muscle tone and size. After 4 months of meticulous postoperative care resulted in uneventful recovery which was governed by contrast radiography (Fig. 3)

Six pairs of aortic arches surround the esophagus and trachea during early fetal life. The left pulmonary artery and the descending aorta are connected by the ductus arteriosus during fetal life, helps in diverting blood from non-functional fetal lungs. The PRAA is a developmental anomaly in which the aorta is formed by the right fourth aortic arch instead of the left fourth aortic arch leading to persistent fourth right aortic arch which form an esophageal extramural fibrous band as ligamentum arteriosum or patent ductus arteriosus. These findings were in consistent with the previous report of similar anomaly in dogs (Koç *et al.*, 2004; Kim *et al.*, 2006, Fossum, 2013 and Bodh *et al.*, 2015) [4, 3, 2, 1]. The anomaly was actually more of a gastrointestinal disorder than a heart disease because it often resulted in post-prandial regurgitation of solid foods after weaning, rather than cardiac dysfunction (Koç *et al.*, 2004; Fossum, 2013; Bodh *et al.*, 2015 and Morgan & Bray, 2019) [4, 3, 2, 1, 5].

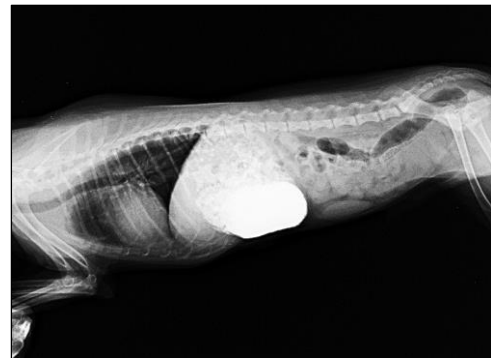The PRAA is most frequently diagnosed in young large-breed dogs. As, medical treatment was unrewarding, surgical ligation and transection of the ligamentum arteriosum was the only recommended method of treatment (Koç *et al.*, 2004; Kim *et al.*, 2006; Fossum, 2013 and Morgan & Bray, 2019) [4, 3, 2, 5]. Early diagnosis and surgery associated with good prognostic indicator (Muldoon *et al.*, 1997; Ve *et al.*, 2017 and Morgan & Bray, 2019) [6, 7, 5]. Hence successful surgical management of aforementioned case associated with early presentation, proper surgical intervention and adequate post-operative care.



**Fig 1:** Showing contrast radiography of the oesophagus revealed contrast material accumulating in the oesophagus at the thoracic inlet and cranial to the heart base



**Fig 2:** Showing dilated portion of the oesophagus cranial to the periesophageal fibrous band of PRAA and heart base.



**Fig 3:** Showing radiograph after 04 months with complete resolution of PRAA

## References

1. Bodh D, Bhat SA, Mann KK, Gill AS, Atray M, Kahlon A *et al.* Persistent right aortic arch in a Pomeranian dog. *Indian Journal of Veterinary Surgery.* 2015; 36(2):138.
2. Fossum TW. *Small Animal Surgery.* 4<sup>th</sup> Edn, Elsevier Mosby, Missouri, 2013, 456-461.
3. Kim NS, Alam MR, Choi IH. Persistent right aortic arch and aberrant left subclavian artery in a dog: a case report. *Veterinari Medicina-Praha.* 2006; 51(4):156.
4. Koç Y, TURGUT K, ŞEN İ, Alkan F, Birdane FM. Persistent right aortic arch and its surgical correction in a dog. *Turkish Journal of Veterinary and Animal Sciences.* 2004; 28(2):441-6.
5. Morgan KR, Bray JP. Current diagnostic tests, surgical treatments, and prognostic indicators for vascular ring anomalies in dogs. *Journal of the American Veterinary Medical Association.* 2019; 254(6):728-33.
6. Muldoon MM, Birchard SJ, Ellison GW. Long-term results of surgical correction of persistent right aortic-arch in dogs: 25 cases. *J Am. vet. Med. Ass.* 1997; 210:1761-4.
7. Ve L, Ober C, Millgram J, Bel L, Bogdan S, Peştean C *et al.* Short-term outcome of a dog following surgical correction of the persistent right aortic arch pathology. *Agricultura,* 2017, 101(1-2).