



ISSN (E): 2277- 7695

ISSN (P): 2349-8242

NAAS Rating: 5.03

TPI 2020; 9(4): 363-368

© 2020 TPI

www.thepharmajournal.com

Received: 20-02-2020

Accepted: 22-03-2020

NB Shridhar

Principal Investigator and Head
Obscure Disease Research Center
Veterinary College Campus,
KVAFSU, Shivamogga,
Karnataka, India

Hematobiochemical, pathomorphological and therapeutic features of *Ficus tsjahela* toxicity in Malnad Gidda cattle

NB Shridhar

DOI: <https://doi.org/10.22271/tpi.2020.v9.i4f.4614>

Abstract

Malnad Gidda cattle native of Western Ghat districts of Karnataka do consume the leaves of *Ficus tsjahela* accidentally and succumb to toxicity. The clinical signs of the toxicity include initial excitation, paddling movements, stereotypic gnawing behavior, ataxia, salivation, hyperaesthesia, nystagmus, generalized tonic clonic seizures, recumbency and eating inanimate objects. The affected Malnad Gidda were managed successfully with administration of diazepam @ 0.5 mg/kg i/v, B-complex vitamin inj 10 ml per animal deep IM, 10% dextrose solution 5-10 ml/kg slow IV 2 times a day at 10 to 12 h for a duration of 3-4 days with administration of activated charcoal @ 2g/kg orally. The estimated hematological parameters like Hb, TC, DLC etc. were unaltered. There was an increasing in serum biochemical parameters like ALT, AST, BUN, creatinine and glucose and no change in calcium, magnesium, phosphorus. In post mortem, the gross lesions were extensive hemorrhage in brain and histology revealed the degenerative changes in the neurons and glial cells. Phytoconstituents like glycosides, diterpenes, tannins, terpenes, steroids, lactones and flavonoids were detected in methanol extract of the plant leaf.

Keywords: *Ficus tsjahela*, toxicity, malnad gidda cattle, pathology, biochemistry, treatment, diazepam, B-complex, dextrose, activated charcoal.

Introduction

Plant toxicity is also one of the major causes of death in ruminants in different parts of India. Malnad Gidda cattle are habitat of Western Ghat Districts of Karnataka State and let out for grazing in forest and do have more access to toxic plants.

Malnad Gidda cattle are small size animals and distributed in Malnad area of Karnataka. The population of the breed is about 7-8 lakh in Karnataka. Malnad Gidda is a dwarf breed. It is said that these cattle do can differentiate the poisonous from edible plant which seems to be false. Because of the edible nature of the plants like *Embelia tserium cottom* and *Mimosa invisa* cattle do consume them and succumb to toxicity. Malnad Gidda cattle usually said to be resistant to bacterial and viral diseases but susceptible to plant toxicities because of their grazing nature. The average weight of the adult cattle is 100-150 kg and average milk yield is 2 liters (Singh *et al.*, 2008)^[27].

Ficus tsjahela is one among the a fig tree belonging to Ficus species of the *Moraceae* family found in the Western Ghat region of the peninsula of India and Srilanka. It is a very common tree in Western Ghat districts of Karnataka especially in Shivamogga, Uttara Kannada, Udupi, Chikkamagaluru, Dakshina Kannada districts of Karnataka. One among 5 trees is *Ficus tsjahela* on the road side (Figure 1 and 2). Birds consume the fruit of the plant and the seeds will be propagated through bird droppings on other trees. Initially it will be a parasitic tree on other plants, destroy them and grow independently. Many Ficus family trees are toxic to cattle (Paterson and Clinch, 1994)^[19]. It is commonly known as the "Karibasari" in Kannada (Gopalakrishna Bhat, 2003)^[6]. The tree is also found in Mandya (Dhanya *et al.*, 2010)^[4].

Farmers cut the tree for various agriculture purpose and discard the leaves on the ground. Many times, the tree leaves are put on the paddock of the cattle as a usual practice in Western Ghat districts. In such time, the cattle get access to the leaves and do consume them and succumb to the toxicity. Scanty reports are there on the toxicity of the plant in Malnad Gidda cattle. The clinical signs and therapeutic regime of the *Ficus tsjahela* is documented in cattle and buffaloes of Karnataka State (Shridhar *et al.*, 2014; Shridhar, 2017)^[25, 26].

Corresponding Author:

NB Shridhar

Principal Investigator and Head
Obscure Disease Research Center
Veterinary College Campus,
KVAFSU, Shivamogga,
Karnataka, India

The data on pathomorphological, hematobiochemical and clinical toxicity features of *Ficus tsjahela* with therapeutic measures is lacking inspite the toxicity is very common in them. Hence, the present study was aimed to evaluate the toxic feature of *Ficus tsjahela* toxicity in Malnad Gidda cattle succumbed with natural toxicity.

Material and methods

The study was conducted in Shivamogga, Uttara Kannada and Udupi Districts during the year 2016 to 2019. Whenever the natural toxicity of *Ficus tsjahela* was reported, the place was visited, ailing animals were examined, post mortem of the dead animals was conducted and initiated the therapy with follow-up of local veterinarian and suitable samples were collected for laboratory identification. In the present study, emphasis was given to toxicity in Malnad Gidda cattle as more number of the animals were succumbed to toxicity

naturally. Always the toxicity was followed by the history of accidental consumption of discarded leaves on the ground or eating the the leaves of the tree put on paddock. The age of the affected Malnad Gidda cattle was in the range of 6-15 years with both male and females.

The toxicity clinical signs were documented with photography and videography the toxicity was diagnosed by the exhibition of clinical signs like convulsions, twitching, eating inanimate objects etc. The other neurological diseases with overlapping clinical signs like trypanosomiasis, hypomagnesaemic tetany, meningitis etc. were ruled out by careful clinical examination and available laboratory tests. Rabies an important viral disease was ruled out by absence of characteristic bellowing and other history (Figure 3 and 4).

The plant was botanically identified as *Ficus tsjahela* by Dr K. Gopalakrishna Bhat, Retd Professor and Head, Department of Botany, Purnaprajna College, Udupi.



Fig 1: *Ficus tsjahela* leaves



Fig 2: *Ficus tsjahela* tree



Fig 3: Clinical signs of *Ficus tsjahela* toxicity in a Malnad Gidda cattle



Fig 4: Malnad Gidda cattle recovering the after toxicity

The temperature, heart rate, pulse rate and respiratory rate were recorded timely. In the regular interval of 24, 48, 72 and 96 h following the onset of the signs of toxicity, blood samples from the affected cattle were drawn. The blood was also drawn from few unaffected Malnad Gidda cattle belonging to both sex to serve as control for comparison.

The animals exhibiting the clinical signs of the toxicity were treated with diazepam @ 0.5 mg/kg i/v, B-complex vitamins, IM followed by intravenous administration of 5-10 ml/kg of 10% dextrose solution twice in an interval of 10-12 h for three days and activated charcoal @ 2g/kg orally as 1:8 slurry twice

at 10 to 12 h interval for two consecutive days.

Alanine aminotransferase (ALT), aspartate aminotransferase (AST), blood urea nitrogen (BUN), serum creatinine (CRT), calcium, magnesium, phosphorus and glucose were estimated in serum of the affected as well as the normal control Malnad Gidda animals.

Postmortem of three Malnad Gidda cattle which succumbed to death due to *Ficus tsjahela* toxicity was conducted and the gross lesions were noted down. Representative tissue samples of the brain, heart, spleen, intestine, kidney, liver, rumen and abomasums were collected in 10% NBF for histopathology.

Phytochemical analysis of the leaf extract and latex was conducted by the technique as explained by Harborne (1998) [9].

All data are expressed as the Mean \pm Standard Error of Mean (SEM) and GraphPad Prism Trial Version 8.0.0 software for Windows was used for statistical analysis and One-way ANOVA followed by Dunnett's multiple comparisons test was performed. Differences were deemed significant for values when $P < 0.05$.

Results and discussion

The toxic dose of the *Ficus tsihela* leaves in Malnad Gidda cattle was 15-30 g/kg. Mild toxicity was observed in the 15 g/kg followed by severe toxicity and death in 30 g/kg. Similar toxic dose of *Ficus tsiela* exerted in experimental toxicity in calves as observed by Nair *et al.* (1985, 1987) [15, 16].

There was no change in the hematological parameters (Table 2). This indicated that the toxicity had not affected hematological system and this is accordance with the finding of few workers who also noted that no change in such parameters in such plants. Mathew *et al.* (2014) [14] who studied the effects of fresh juice and extract of *Ficus tsiela* on

rat hematology opened that no adverse effect on the hemopoietic system at the given doses and further stated that this might be attributed to the species variation rather than the non-toxic nature of the plant.

In estimated biochemical parameters, an increase ($P < 0.05$) in glucose, AST, ALT, BUN and CRT of the affected Malnad Gidda cattle during the course of toxicity was observed. Blood glucose returned to normal at 96 h. There was no change in calcium, magnesium and phosphorus was observed (Table 1). Very similar finding of transient hypoglycaemia was observed in experimentally induced *Ficus tsiela* toxicity in calves as reported by Nair *et al.* (1987) [16]. Tonic clonic convulsions leading to increased skeletal muscles activity might be the cause of hyperglycemia in the present study. Along with the neurological signs, there was hyperglycaemia in calves with *Ficus tsihela* toxicity which was attributed to excessive muscle contractions for which more glucose is needed. Acute hyperglycemia during seizures, suggested reflux increase in muscle activity and increase in blood glucose concentration (Ratnasooriya *et al.*, 1992; Geetha *et al.*, 1994) [2, 5].

Table 1: Haematological profile in healthy and *Ficus tsihela* toxicity observed Malnad Gidda Cattle

Group	Healthy Malnad Gidda cattle (n=6)	Malnad Gidda cattle with toxicity (n=10)	Reference values
RBCs (106/ μ l)	7.15 \pm 1.10	7.84 \pm 0.48	5.0-10.0
Hb (g/dl)	12 \pm 0.20	11.77 \pm 0.28	8-15
PCV (%)	32.15 \pm 2.5	33.24 \pm 0.78	24-46
MCV (fl)	46.12 \pm 5.4	44.63 \pm 6.8	40-60
MCH (pg)	13.10 \pm 2.4	13.30 \pm 3.2	11-17
WBCs (103/ μ l)	11.50 \pm 1.3	11.97 \pm 4.38	4.0-12.0
Platelets (103/ μ l)	280.47 \pm 66.57	263.26 \pm 47.94	100-800
Lymphocytes (%)	58.15 \pm 4.5	56.15 \pm 4.30	62-63
Neutrophils (%)	28.17 \pm 5.4	39.89 \pm 1.7	15-33
Eosinophils (%)	11.79 \pm 0.33	10.87 \pm 0.43	0-20
Monocytes (%)	5.75 \pm 0.5	4.77 \pm 1.28	0-8

The values are expressed as Mean \pm SEM.

RBCs, Red blood cells; Hb, Hemoglobin; PCV, Packed cell volume; MCV, mean corpuscles volume; MCH, Mean corpuscles hemoglobin; WBCs, White blood cells.

Table 2: Biochemical profile in healthy and *Ficus tsihela* toxicity observed Malnad Gidda cattle

Parameter	Apparently healthy Malnad Gidda cattle (n=10)	Malnad Gidda cattle affected with <i>F. tsihela</i> toxicity (n=10)				
		0 hour	24 hours [#]	48 hours [#]	72 hours	96 hours
Alanine amino Transferase (ALT in U/L)	30.5 \pm 3.10	29.17 \pm 1.89	26.68 \pm 2.78	45.3 \pm 2.73*	49.5 \pm 2.24*	58.8 \pm 2.56*
Aspartate amino Transferase (AST in U/L)	67.2 \pm 2.5	68.67 \pm 2.58	67.97 \pm 2.26	89.3 \pm 2.68*	88.8 \pm 2.42*	97.4 \pm 1.34*
Blood Urea Nitrogen (BUN in U/L)	33.66 \pm 1.62	35.38 \pm 2.64	38.16 \pm 1.25	65.7 \pm 1.45*	68.5 \pm 2.68*	78.3 \pm 1.42*
Creatinine (mg/dl)	1.10 \pm 0.25	1.24 \pm 0.36	1.75 \pm 0.25	1.64 \pm 0.58	2.60 \pm 0.64*	3.59 \pm 0.26*
Calcium (mg/dl)	12.3 \pm 1.38	11.37 \pm 1.26	11.04 \pm 1.37	11.56 \pm 1.72	11.84 \pm 1.89	11.39 \pm 1.29
Magnesium (mg/dl)	2.78 \pm 0.56	2.98 \pm 0.76	2.32 \pm 0.19	2.89 \pm 0.69	2.62 \pm 0.31	2.80 \pm 0.69
Phosphorus (mg/dl)	4.98 \pm 0.69	4.79 \pm 0.73	4.33 \pm 0.39	4.96 \pm 0.23	4.87 \pm 0.28	4.72 \pm 0.29
Glucose (mg/dl)	77.89 \pm 2.93	76.56 \pm 2.94	271 \pm 22.30*	171 \pm 11.36*	97 \pm 2.66*	84 \pm 2.39

The values are expressed as Mean \pm SEM.

* $P < 0.05$

[#]Treatment was given with diazepam 0.5 mg/kg i/v, B-Complex 10 ml i/m and 5-10 ml of 10% dextrose solution i/v.

The increase in activity of the AST and ALT is often seen following liver damage and it is attributed to the leakage of the enzymes from damaged hepatocytes. High levels of AST also indicate cardiac infarction and muscle injury. Kidney damage is indicated by the increase in the concentration of BUN and CRT values as reported in earlier studies (Kaneko *et al.*, 2008; Gowda *et al.*, 2018) [10, 7]. Increase in activity of serum AST and ALT, BUN and CRT values and concurrent histopathological lesions in kidney and liver were reported

earlier in calves in experimental *Ficus tsiela* toxicity (Nair *et al.*, 1985) [15]. So in the present study, the biochemical alterations could be largely attributed to its pathological effects on vital organs.

Toxicity signs observed were initial abnormal gait causing uncoordinated movements. This was followed by excitation, salivation and twitching of eyelids with gradually increasing excitement with light and sound reflexes. Inanimate objects were chewed including their own skin. Anxiety was expressed

with erect ears, widely opened eyes and nostrils. This was progressed with generalized tonic and clonic convulsions with paddling of all the limbs in many affected animals. Due to rigidity of the limb muscles, the animals could not lay down properly and got into a dog sitting posture. Malnad Gidda cattle with *Ficus tsiela* toxicity exhibited other clinical signs like anorexia, excitement, twitching of palpebral muscles, frequent involuntary jaw movements, anxiety, opisthotonos, inanimate object biting etc were similar to that of the clinical signs in other neurotoxic plants like *Ficus tsiela* and *Ficus tsiela* toxicity exhibited by affected animals as reported earlier (Rajan *et al.*, 1986; Nair *et al.*, 1985, 1987, 1997 ; Shridhar, 2017) [20, 15, 16, 17, 26]. Physical symptoms, which occur include excessive salivation, laboured breathing and intermittent tonic convulsions in the present study compared to *Ficus tsiela* toxicity (Rajan *et al.*, 1986; Nair *et al.*, 1985, 1987) [20, 15, 16] except frequent bellowing in contrast to the observations of clinical signs in the present

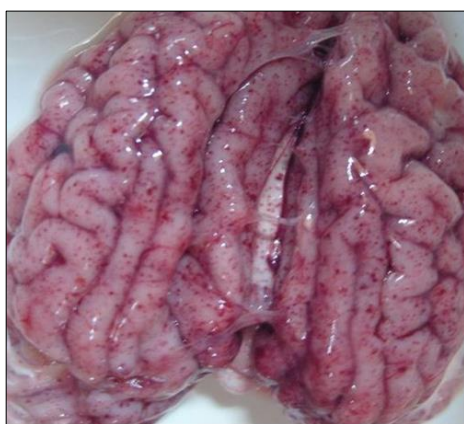

Fig 5: Petechial and extensive hemorrhages in the brain of Malnad Gidda cattle died due to toxicity of *Ficus tsiela*

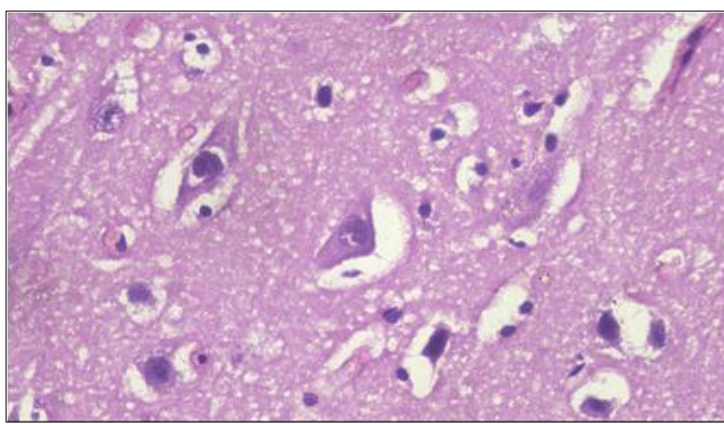


Fig 6: Section of brain of Malnad Gidda cattle affected with *Ficus tsiela* toxicity showing multifocal to diffuse vacuolations, vascular congestion, occasional haemorrhages and edema (100 x H&E).

Similar observations were done by Nair *et al.* (1995) [15] who induced the experimental toxicity of *Ficus tsiela* in cross calves with similar neurological signs. Studies suggested that the leaves contain substances which predominantly affect the capillaries of the central nervous system. The brain ultra structural changes revealed degenerative changes in the neurons and glial cells, vacuolation and myelin degeneration with structural alterations in axosomatic and axodendritic synapses. Pathological studies suggested that the leaves contain substances which predominantly affect the capillaries of the central nervous system (Nair *et al.*, 1985, 1987, 1997; Myburgh *et al.*, 1994) [15, 16, 17, 13].

The phytochemical analysis revealed the positivity of steroids, terpenes, diterpenes, lactones, flavonoids, tannins and glycosides. In earlier studies of phytochemical extraction of leaf extract of *Ficus tsiela* also revealed positive to glycosides anthraquinones, terpenoids, tannins, steroids, flavonoids, saponins and phlobatannin (Mathew, 2014; Ramesh *et al.*, 2012; Bafor *et al.*, 2009) [14, 21, 1]. It was evident that the latex of the plant *Ficus tsiela* induces the toxicity which may contain the high quantity of the toxin which is an integral part of the leaves. Several potentially toxic substances have been isolated from *Ficus* spp. The proteolytic enzyme ficin is found in the latex of several members of the genus, including *Ficus carica*. This compound is more toxic when administered intravenously than when ingested, and the

study. This might be attributed to the species difference of the plants and difference in phytochemicals.

In three of the animals, death occurred in spite of the treatment in the present study. Mortality in cattle and buffaloes due to consumption of the leaves of *Ficus tsiela* and *Ficus tsiela* has been reported from a number of areas of India (Rajan *et al.*, 1986; Nair *et al.*, 1987; Shridhar *et al.*, 2014; Shridhar, 2017) [20, 16, 25, 26]. The symptoms are predominantly nervous in nature and associated with significant histological changes, including cerebral oedema and demyelination, together with renal and hepatic degeneration and necrosis (Nair *et al.*, 1985; Rajan *et al.*, 1986) [15, 20].

Extensive haemorrhages in the brain of the affected Malnad Gidda cattle was observed during the post mortem. There were degenerative changes in the neurons and glial cells and multifocal to diffuse vacuolations, vascular congestion, occasional haemorrhages with edema (Figure 5 and 6).

toxicity depends primarily on the amount given, rather than on the concentration of the dose. Sub-lethal doses provoke vomiting, sanguineous diarrhoea and general prostration. A furo-coumarin, ficusin (also known as psoralene), has been isolated from the leaves of *Ficus carica* and a dialysable, alkaloid-like compound has been found in the latex. This species is known to cause percutaneous photosensitization in man, probably due to the presence of coumarins and furocoumarins, including ficusin (Watt and Breyer Brandwijk, 1962) [30].

The affected Malnad Gidda cattle were treated with slow administration of 5-10 ml/kg dextrose solution, 0.5 mg/kg diazepam, B-complex vitamins with gradual reduction in severity of the toxicity after 48 h. The condition of the affected Malnad Gidda cattle was improved markedly indicated by consumption of feed and water. On day 4 of the initiation of the therapy, the Malnad Gidda cattle became normal in terms of dung and urine passing. There was re-occurrence of the toxicity signs in 3 Malnad Gidda cattle after day 4 and the therapy was repeated with recovery and this might be attributed to the presence of neuroactive phytotoxin in blood due to consumption of more quantity of the plant (Shridhar *et al.*, 2014; Shridhar, 2017) [25, 26].

The tonic and clonic convulsions exhibited by the Malnad Gidda cattle in *Ficus tsiela* plant leaf toxicity was suggestive of a neurotoxic content of the plant which might

have stimulated the limbic system, cerebral cortex (Rodostists *et al.*, 2007) [24].

Diazepam was administered in the interval of 10-12 h interval with satisfactory recovery in most of the affected Malnad Gidda cattle @0.5 mg/kg and most of the clinical signs subsided after administration of diazepam. Diazepam is a benzodiazepine that exerts anticonvulsant, sedative, anxiolytic, musclerelaxant, and amnesic effects. These effects are brought by mimicking gamma aminobutyric acid (GABA) receptor which are inhibitory in nature in CNS. It is also a drug for short term treatment of epilepsy. Being a good sedative, it has got the anti-anxiety property. The recovery of the animals might be attributed to this. Hence, the clinical signs might have subsided (Mandrioli *et al.*, 2008; Riss *et al.*, 2008) [11, 23]. Picrotoxin initiates its action through GABA receptor. The satisfactory clinical recovery of the Malnad Gidda animals in *Ficus tsjahela* toxicity indicated the dose and interval selected might be appropriate (Booth and McDonald, 1998) [2]. Pankaj Kumar Patel *et al.* (2018) [18] also managed the calf with ivermectin toxicity exhibiting the neurological signs with administration of diazepam.

B-complex vitamins are vital dietary supplements. Thiamine is an important vitamin in the B complex family which is needed for metabolism of carbohydrates. In carbohydrate metabolism, for formation of thiamine pyrophosphate, thiamine is a cofactor in carbohydrate metabolism and produces energy. Impairment in its synthesis or deficiency affects the carbohydrate metabolism and induces opisthotonus, circling movements, listlessness, muscle tremors in ruminants. In the present study, B-complex vitamins containing thiamine with administration of dextrose might augmented the recovery of the toxicity affected Malnad Gidda cattle (Christiane, 2017; Tolga *et al.*, 2010) [3, 29].

In the present study, activated charcoal was administered at the dose of 2 g/kg orally as a 1:8 slurry which might have adsorbed the toxins from the gut. The activated charcoal is a black powder available as a laboratory grade chemical which produces a fine suspension when mixed with water. In many toxicities in cattle, activated charcoal is used for the treatment effectively. Activated charcoal is administered in toxicities in early stage before absorption of the toxin/s into circulation or during the onset of clinical signs of the toxicity to inhibit the further absorption of the toxicants in the gut. Many plant toxicities were treated effectively by administration of activated charcoal in similar dose with examples of *Lantana* toxicity (Michael and Coralie Stewart, 1984; Gupta *et al.*, 2019) [12, 8] and Yellow tulp (*Moraea pallid*) toxicity (Snyman *et al.*, 2009) [28].

There is a need to find a more appropriate therapy for the toxicity with more effective anti-epileptic and anti-anxiety medication with long half-life, wide margin of safety and ease of availability.

Toxicity therapy with more effective anti-epileptic and anti-anxiety drugs with a long half-life wide margin of safety and ease of availability is needed. Further work is needed to explain the exact phytochemical component responsible for toxicity.

Conclusion

Ficus tsjahela is a toxic plant that affect the Malnad Gidda cattle of Western Ghat of Karnataka state. The affected animals exhibited with clinical signs of toxicity like excitation, paddling of limbs, ataxia, salivation, generalized seizures, unable to get up and head pushing etc. The animals were administered with 0.5 mg/kg diazepam IV, B-complex vitamins 10 ml deep IM, 10% dextrose 5-10 ml kg slow IV

two times daily for 3 days with oral administration of activated charcoal 2 g/kg for two days gave good recovery. There was no change in the hematological parameters where there was an increase in serum glucose, AST, ALT, BUN, CRT without alteration in other parameters. Postmortem of the animals revealed a characteristic hemorrhages in brain with microscopic lesions of degenerative changes neuronal degenerative changes and glial cells. Glycosides, diterpenes, tannins, terpenes, steroids, lactones and flavonoids were the phytochemical constituents in the latex and plant leaf extract.

Conflict of interest: Nil

Acknowledgements

The financial assistance by Government of Karnataka for the establishment of Obscure Disease Research Center in Veterinary College Campus, Shivamogga, Karnataka for the study of diseases of unknown etiology in cattle and buffaloes is sincerely acknowledged.

References

1. Bafor EE, Igbinuwen O. Acute toxicity studies of the leaf extract of *Ficus exasperata* on haematological parameters, body weight and body temperature. *J. Ethnopharmacol.* 2009; 123(2):302-307.
2. Booth NH, McDonald LE. Psychotropic agents. In: *Veterinary Pharmacology and Therapeutics*, 6th edn. Panima Publishing Corporation, New Delhi, 1998, 363-395.
3. Christiane LG. New approaches, development, and improvement of methodologies for the assessment of B-vitamin requirements in dairy cows. *Brazilian J. Anim. Sci.* 2017; 46(7):614-620.
4. Dhanya B. Viswanath, Syam, Purushothaman Seema, Suneeta B. *Ficus* trees as components of rained agrarian systems in Mandya District of Karnataka. *My Forest.* 2010; 46(2):161-165.
5. Geetha BS, Mathew BC, Augusti KT. Hypoglycemic effects of leucodelphinidin derivative isolated from *Ficus bengalensis* (Linn). *Indian J. Physiol. Pharmacol.* 1994; 38:220-222.
6. Gopalakrishna Bhat K. *Ficus* Family; Flora of Udupi. *Indian Naturalist*, 2003, 597p.
7. Gowda HK, Narayanaswamy M, Veena T, Krishnaswamy A, Nagaraja CS, Shridhar NB *et al.* Biochemical profile of Malnad Gidda breed of cattle. *J. Cell Tissue Res.* 2018; 18(1):6407-6412.
8. Gupta RK, Niyogi D, Nayan R, Singh SV, Mishra A, Varun VK. Clinico-pathological study of *Lantana camara* toxicity in a sheep farm *J. Pharmacogn. Phytochem.* 2019; 8(4):2219-2221.
9. Harborne JB. *Methods of Plant Analysis*. In: *Phytochemical Methods A Guide to Modern Techniques of Plant Analysis*. Springer, Dordrecht, 1998.
10. Kaneko JJ, Harvey JW, Bruss ML. *Clinical Biochemistry of Domestic Animals*. 6th ed. Academic Press, California, USA, 2008.
11. Mandrioli R, Micolini L, Raggi MA. Benzodiazepine metabolism: An analytical perspective. *Curr. Drug. Metab.* 2008; 9:827-844.
12. Michael A. Pass, Coralie Stewart. Administration of activated charcoal for the treatment of *Lantana* poisoning of sheep and cattle. *J. Applied Toxicol.* 1984; 4(5):269-271.
13. Myburgh JG, Fourie N Van der Lugt JJ, Kellerman TS, Cornelius ST, Ward CA. A nervous disorder in cattle, caused by the plants *Ficus ingens* var. *ingens* and *Ficus*

- cordata* subsp. *salicifolia*. Onderstepoort J. Vet. Res. 1994; 61(2):171-176.
14. Mathew L, Divakaran Nair N, Vijayan N, Mercey KA. Hemato-biochemical and oxidative effect of fresh juice and ethanolic extract of *Ficus tsiela* Roxb in rats. Vet. World. 2014; 7(10):890-894.
 15. Nair ND, Valsala KV, Ramachandran KM, Rajan A. Experimental studies on Chela leaf (*Ficus tsiela* Roxb) poisoning in calves. Kerala J. Vet. Sci. 1985; 16:94-99.
 16. Nair ND, Abraham MJ, Valsala KV, Nair MG, Rajan A. Clinico-pathological features of experimental Chela leaf poisoning in calves. Kerala J. Vet. Sci. 1987; 18:84-90.
 17. Nair ND, Rajan A, Nair MK. Histopathology of toxicity of *Ficus tsiela* in cattle. Indian J. Vet. Pathol. 1995; 19:1-5.
 18. Pankaj Kumar Patel, Sawita Kumari Patel, Sonam Bhatt, Desh Deepak, Arun Prabhakar, Brijesh Patel *et al.* Therapeutic management of ivermectin toxicity in a calf: A case report. Int. J. Curr. Microbiol. App. Sci. 2018; 7(04):1964-1969.
 19. Paterson RT, Clinch NJL. Use of Trees by Livestock: Ficus. I edn. Chatham, UK. Natural Resources Institute, 1994.
 20. Rajan A, Nair ND, Valsala KV, Maryamma KI, Ramachandran KM. Pathology of a nervous disorder in cattle caused by the toxicity of leaves of the tree *Ficus tsiela* Roxb. Indian Vet. J. 1986; 63:184-186.
 21. Ramesh K Satdive, Raghuram Chimata, Ajay Namdeo, Devanand P Fulzele. *In vitro* screening for phytochemical and antimicrobial activity of poisonous plant *Ficus Tseila* Roxb. Int. J. Pharma Bio. Sci. 2012; 3(2):213-221.
 22. Ratnasooriya WD, Premakumar GAS, Tillekeratne LMV. Exploratory behavior of male rats treated with a crude extract of *Ficus tsiela* leaves. Med. Sci. Res. 1992; 20:233-234.
 23. Riss J, Cloyd J, Gates J, Collins S. Benzodiazepines in epilepsy: Pharmacology and pharmacokinetics. Acta Neurologica Scandinavica. 2008; 118(2):69-86.
 24. Rodostists OM, Blood DC, Gay CC. Diseases of Nervous System. In: Veterinary Medicine. 10th edn. E.L.B.S, London, 2007, 458-503.
 25. Shridhar NB, Krishna NS, Santhosh Kumar CN. Toxicity of *Ficus Tsjahela* leaves in cattle and its clinical management. Indian Vet. J. 2014; 91(7):49-50.
 26. Shridhar NB. Therapeutic management of toxicity of *Ficus tsjahela* leaves in cattle. Toxicol. Int. 2017; 24(3):313-318.
 27. Singh PK, Rakesh P, Manjunath VK, Rudresh BH, Govindaiah MG. Features and status of miniature indigenous germplasm of cattle-Malnad Gidda. Indian J. Anim. Sci. 2008; 78:1123-1126.
 28. Snyman LD, Schultz RA, Botha CJ, Labuschagne L, Joubert JPJ. Evaluation of activated charcoal as treatment for Yellow tulp poisoning in cattle. J. South Afr. Vet. Assoc. 2009; 80(4):274-275.
 29. Tolga K, Murat D, Omer K. Thiamine status of feedlot cattle fed a high-concentrate diet. Can. Vet. J. 2010; 51(11):1251-1253.
 30. Watt JM, Breyer-Brandwijk MG. Medicinal and Poisonous Plants of Southern and Eastern Africa. 2nd Edn. Edinburgh: Collins, 1962.