



ISSN (E): 2277- 7695
ISSN (P): 2349-8242
NAAS Rating: 5.03
TPI 2020; 9(2): 34-36
© 2020 TPI
www.thepharmajournal.com
Received: 22-12-2019
Accepted: 24-01-2020

Deepak
Veterinary Surgeon, Department
of Animal Husbandry and
Dairying, Haryana, India

Dinesh Gulia
Veterinary Surgeon, Department
of Animal Husbandry and
Dairying, Haryana, India

Jagat Singh Kadian
Veterinary Surgeon, Department
of Animal Husbandry and
Dairying, Haryana, India

Siddharth Deswal
Veterinary Surgeon, Department
of Animal Husbandry and
Dairying, Haryana, India

Therapeutic management of *Moniezia expansa* infection in Murrah calves

Deepak, Dinesh Gulia, Jagat Singh Kadian and Siddharth Deswal

DOI: <https://doi.org/10.22271/tpi.2020.v9.i2a.4340>

Abstract

The study describes the clinical signs, diagnosis via microscopical faecal examination and treatment of the *Moniezia expansa* infection in Murrah buffalo calves. The calves were successfully treated with praziquantel, castor oil and parenteral medicinal therapy.

Keywords: Moniezia, proglottids, praziquantel, calves

1. Introduction

The state of Haryana is famous for its Murrah breed of buffalo. Helminth infection in domestic ruminants causes significant economic losses to the farmers and hence is a disease of major concern. *Moniezia* spp. are the most common cestodes prevailing in the small intestine of ruminant calves [1]. *Moniezia expansa* infects mainly sheep, goats, cattle and buffalo [2]. Although most of the *Moniezia* infections are asymptomatic in ruminants but heavy parasitic load may cause poor hair coat, constipation, diarrhoea, dysentery and sometimes anaemia. Aforementioned clinical signs are mainly seen in the calves below 6 months of age which are especially on a poor diet [3]. The current study was conducted to evaluate the clinical signs, diagnosis and therapeutic management of *Moniezia expansa* infection in Murrah buffalo calves.

2. History and Clinical findings

Four Murrah buffalo calves with age ranging from 2.5 to 5 months were reported to Government Veterinary Hospital, Bhagwi, Charkhi Dadri (Haryana) out of which two calves were with a complaint of constipation and the remaining two calves were with a complaint of explosive diarrhoea and emaciation since 4-5 days. White coloured cooked rice grain type of crumbs was observed in the gross faecal examination of the calves (Fig. 1).



Fig 1: White coloured cooked rice grain type of crumbs in faeces

Corresponding Author:

Deepak
Veterinary Surgeon, Department
of Animal Husbandry and
Dairying, Haryana, India

2.1 Clinical signs and diagnosis

The calves were showing body temperature from 100.2 °F to 101.7 °F. The heart rate and respiratory rate were increased.

The haemoglobin values lied within normal range (Table 1). Confirmatory diagnosis was based on the microscopic faecal examination under the low power (10X) magnification (Fig. 1) and the high power (40X) magnification (Fig. 2). Microscopic examination revealed the presence of triangular shaped eggs with hexacanth embryonic mass in them (Fig. 3). Reference values of the above mentioned parameters were taken from the literature [4].

Table 1: Haemoglobin values and physiological parameters of the affected calves

Parameter	1 st calf	2 nd calf	3 rd calf	4 th calf	Normal Values [4]
Temperature (°F)	101.2	101.7	101.4	100.2	101-102
Respiration rate / minute	36	40	42	35	12-16
Heart rate / minute	68	70	71	66	40-60
Haemoglobin (g/dl)	11.4	11.0	10.8	12.3	8.5-12.5

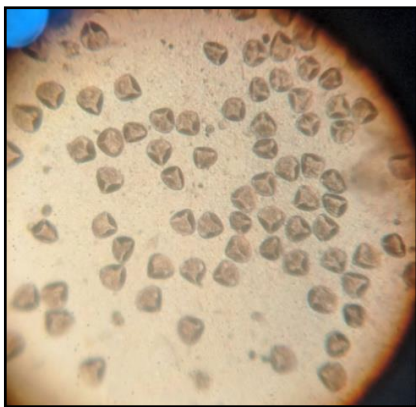


Fig 2: Microscopic field showing triangular shaped *Moniezia expansa* eggs (10X)

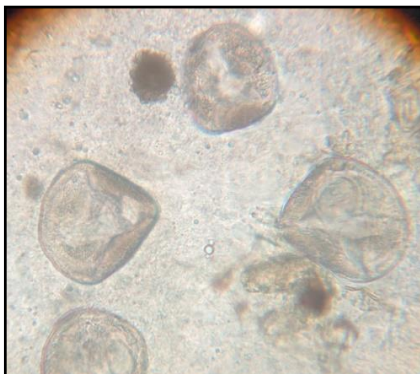


Fig 3: Microscopic field showing triangular shaped *Moniezia expansa* eggs (40X)

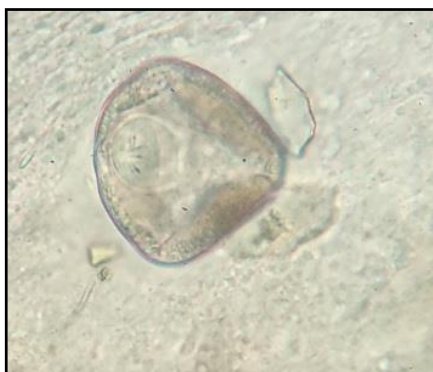

Fig 4: Triangular shaped *Moniezia expansa* egg with hexacanth embryo (40X)

3. Treatment

Single dose of praziquantel (Tablet Distoside®: Chandra Bhagat Pharma Pvt. Ltd.) @ 5mg/kg b. wt. [5] was given to all the four calves. Along with it, the calves with diarrhoea were also given ceftriaxone 1gm (Inj. Cefstan®: Zoetis India Ltd.), chlorpheniramine maleate 3ml (Inj. Avilin® vet: Intervet India Pvt. Ltd.) and ketoprofen 4ml (Inj. Neoprofen®: Zydus AH) for consecutive four days to treat them for enteric infection. Remaining two calves with constipation were also given 25 ml of castor oil orally for consecutive four days.

4. Results and Discussion

The affected calves showed improvement from 3rd day post-treatment. The faeces of all the four calves were again examined on 7th day post treatment and they were found negative for *Moniezia expansa* eggs. Post-therapeutic remission of clinical signs confirmed complete recovery.

Moniezia spp. infection is quite common in young calves during their first year of life and relatively less common in older animals [6]. Importance of tapeworms is ambiguous in ruminants, as farmers usually overemphasize their significance and veterinarians underestimate it. Although most of the *Moniezia spp.* infections are asymptomatic, occasionally heavy worm load may cause unthriftiness, poor hair coat and digestive disturbances like constipation, diarrhoea, and dysentery [3].

The affected calves were successfully treated with praziquantel. This broad spectrum anthelmintic drug is active against a wide range of larval and adult cestodes leading to very rapid contraction and vacuolization of the tegument, inhibition of glucose uptake and decrease in glycogen content of the worm [7]. The supportive therapy was given to control the secondary bacterial infection.

Tapeworm eggs are passed in the faeces individually or protected in proglottids. The life cycle of tapeworms begins when eggs are passed in the faeces. The eggs are ingested by pasture (oribatid) mites, which serve as an intermediate host. Eggs must reach the gut of the mite hosts within one day of release otherwise they desiccate [6]. The mites feed on the eggs by breaking the shell with their chelicerae and ingesting the developing embryo, or the oncosphere. In the mite, the oncosphere penetrates the mid-gut wall to enter the hemocoel, where it slowly develops to cysticercoid in about four weeks. The developmental time however, varies significantly with different species and environmental temperatures, ranging from two to seven months [8]. Infected oribatid mites are consumed with grasses and other forages by ruminants while grazing. The cysticercoids are then released as the mites are digested and they further attach to the wall of the alimentary tract of the ruminants, where they grow and mature to adult tapeworms in about 5–6 weeks. Meanwhile they release egg-filled proglottids which are diagnosed as the cooked rice shaped structures passed in the host faeces [6, 8, 9].

5. Conclusion

The cestodal infection (*M. expansa*) generally causes minor health problems especially in young ruminants but it significantly affects the growth and productivity of the animals causing remarkable economic losses to the farmers. Praziquantel is a proven broad spectrum anthelmintic drug and its efficacy against *Moniezia spp.* is proved by the current study. Scheduled frequent deworming is advised in the prevalent areas of helminthic infections for enhanced growth and productivity of the animals.

6. References

1. Das M, Deka DK, Sarmah AK, Sarmah PC, Islam S. Gastrointestinal Parasitic Infections in Cattle and Swamp Buffalo of Guwahati, Assam, India. *Indian Journal of Animal Research*. 2018; 52(12):1732–38.
2. Borthakur SK, Das MR. Incidence of monieziosis in cattle and buffalo calves of Assam. *Journal of Veterinary Parasitology*. 2005; 19(2):173-174.
3. Constable PD, Hinchcliff KW, Done SH, Grünberg W. *Veterinary Medicine: a textbook of the diseases of cattle, horses, sheep, pigs and goats*. 11th Edition, Volume 1, Elsevier Ltd., China, 2017, 420-422.
4. Sharma MC, Kumar M, Sharma RD. *Textbook of Clinical Veterinary Medicine*. 1st Edn, ICAR, New Delhi, 2009, 604-609.
5. Irie T, Sakaguchi K, Ota-Tomita A, Tanida M, Hidaka K, Kirino Y et al. Continuous Moniezia Benedeni Infection in Confined Cattle Possibly Maintained by an Intermediate Host on the Farm. *Journal of Veterinary Medical Science*. 2013; 75(12):1585-1589.
6. Yadav S, Patel PK, Deepak D, Verma NK, Dixit SK. Medical Management of Moniezia Expansa Infection in a Buck: A Case Report. *Journal of Pharmacognosy and Phytochemistry*. 2019; 8(1):1686-1688.
7. Andrews P, Thomas H, Pohlke R, Seubert J. Praziquantel. *Medicinal Reviews*. 1983; 3(2):147-200.
8. Mullen GR, Oconnor BM. Medical and Veterinary Entomology, In: *Mites (Acari)*. Elsevier science, USA. 2002, 449-516.
9. Miller JE, Kaplan RM, Pugh DG. Sheep and Goat Medicine, In: *Internal Parasites*. Second Edition, Elsevier, USA, 2012, 106-124.