



ISSN (E): 2277- 7695

ISSN (P): 2349-8242

NAAS Rating: 5.03

TPI 2019; 8(6): 624-626

© 2019 TPI

www.thepharmajournal.com

Received: 19-04-2019

Accepted: 21-05-2019

## Manu Jaiswal

a) Department of Veterinary Clinical Complex, Post Graduate Institute of Veterinary Education and Research, Jaipur, Rajasthan, India

b) Faculty of Veterinary and Animal Science, Institute of Agricultural Sciences, Rajiv Gandhi South Campus, Banaras Hindu University, Barkachha, Mirzapur, Uttar Pradesh, India

## Vivek Kumar Singh

Faculty of Veterinary and Animal Science, Institute of Agricultural Sciences, Rajiv Gandhi South Campus, Banaras Hindu University, Barkachha, Mirzapur, Uttar Pradesh, India

## Kuldeep Saini

Department of Veterinary Parasitology, Post Graduate Institute of Veterinary Education and Research, Jaipur, Rajasthan, India

## Correspondence

### Vivek Kumar Singh

Faculty of Veterinary and Animal Science, Institute of Agricultural Sciences, Rajiv Gandhi South Campus, Banaras Hindu University, Barkachha, Mirzapur, Uttar Pradesh, India

## Concurrent infection of theileriosis and anaplasmosis in crossbreed cattle

Manu Jaiswal, Vivek Kumar Singh and Kuldeep Saini

### Abstract

A 5-year-old crossbred cattle with history of anorexia, pyrexia, salivation was presented to Veterinary Clinical Complex, PGIVER, Jaipur, India. On clinical examination, it was revealed that the animal was dull and depressed with rectal temperature of 105.2°F. The cow also exhibited nasal discharge, coughing, moist rales on auscultation of lungs, ruminal atony, dehydration, rough body coat, paler mucous membrane of conjunctiva and vulva and enlargement of prescapular lymph nodes. Heavy tick infestation was also observed. History and clinical signs suggested haemoprotozoan infection. Laboratory examination revealed mixed infection of *Theileria* spp. and *Anaplasma* spp. with low haemoglobin level (4.2g/dl). The cattle was treated with buparvaquinon, fluid therapy, liver extracts, antipyretic and antihistaminics for three days, but eventually succumbed at 8<sup>th</sup> day. Post-mortem examination revealed severe anaemic carcass with congestion and petechiae in the visceral organs. Lungs showed severe congestion suggesting that the animal might have died due to secondary bacterial pneumonia together with toxemia.

**Keywords:** Cattle, moist rales, post-mortem examination, toxemia


### Introduction

The arthropod borne hemoparasitic diseases are of great economic impact on livestock affecting 80% of the world cattle population and causes economic loss due to morbidity and mortality (Kasozzi *et al.*, 2014) [8]. Theileriosis is one such commonest haemoprotozoan diseases of Indian subcontinent causing severe economic losses. Theileriosis is caused by *Theileria annulata* and transmitted through the bites of tick *Hyalomma anatolicum*. It has been considered as the most important blood protozoan parasite with higher incidence in exotic breeds and the crossbred cattle of all age groups. *Theileria annulata*, an intracellular obligate hemoprotozoan, causes tropical theileriosis in both wild and domestic animals. The most frequently observable clinical symptom of theileriosis are high fever, enlargement of regional superficial lymph nodes, inappetence, cessation of rumination, cachexia, anemia, leucopenia, laboured breathing, lacrimation and conjunctivitis. After clinical recovery from acute infections, animal may become carriers with long-term persistent infections (Brown, 1990) [2]. Bovine anaplasmosis caused by the obligate intra-erythrocytic rickettsia, *Anaplasma marginale* (Ristic, 1980) [15] is responsible for great economic losses in developing countries. Anaplasmosis is endemic in tropical and subtropical areas but is frequently reported in temperate regions of the world (Kuttler, 1984) [10]. Anaplasmosis is currently classified in list B of the Office International des Epizooties (OIE) Terrestrial Animal Health Code due to its socioeconomic importance and significance in terms of restriction and animal products (OIE, 2003) [14]. The number of infected erythrocytes increases logarithmically and removal of these infected cells by phagocytosis results in development of haemolytic anaemia and icterus. Acute anaplasmosis causes anaemia, abortion, decreased milk production and death (Ajayi *et al.*, 1978) [1]. Cattle recovered from acute infection remain persistently infected and protected from clinical disease, serving as reservoirs for *A. marginale*, which are not detectable by microscopic methods in the carrier stage of infection (Ewing, 1981; Kieser *et al.*, 1990) [7, 9].

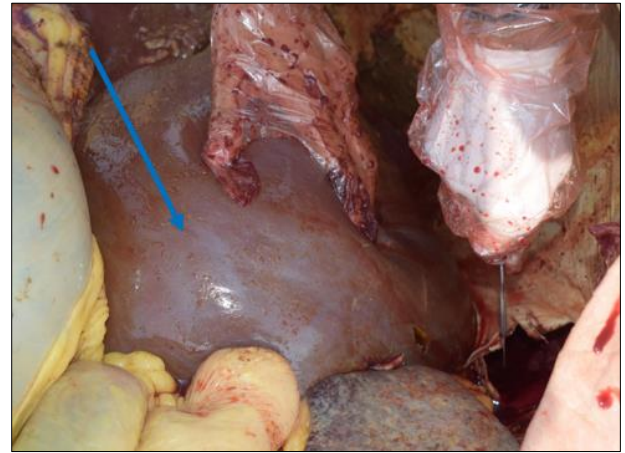
### Case history, clinical observation and diagnostic work -up

A 5-year-old crossbred pregnant cattle with history of anorexia, pyrexia, salivation was presented to Veterinary Clinical Complex, PGIVER, Jaipur, India. On clinical examination, it was revealed that the animal was dull and depressed with rectal temperature of 105.2°F. The cow also exhibited nasal discharge, coughing, moist rales on auscultation of lungs, ruminal atony, dehydration, rough body coat,

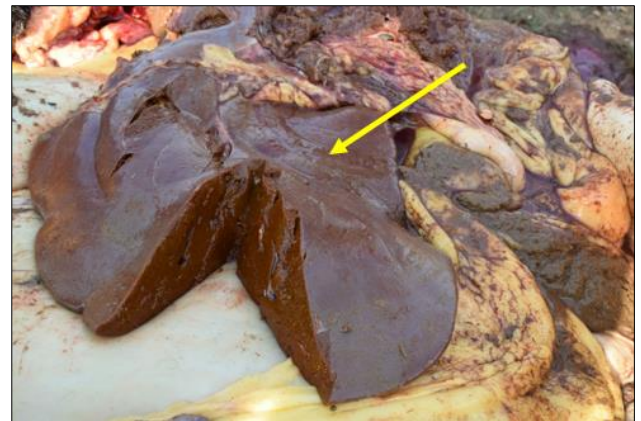
paler mucous membrane of conjunctival and vulvar and enlargement of prescapular lymph nodes. Closed physical examination of medial aspect of pinna and udder were completely yellowish which indicate towards jaundice. Heavy tick infestation was also observed. On the basis of clinical examination, blood sample was collected aseptically from jugular vein in a sterilized EDTA vial for haematological examination. The Haemoglobin (Hb) was 4.2 g/dl indicative of marked anaemia. A peripheral blood smear was made from ear tip and stained with Giemsa and microscopic examination done under oil immersion for the presence of any haemoprotozoan. Peripheral blood smear examination revealed mixed infection of *Theileria* spp. And *Anaplasma* spp. (Fig 1)



**Fig 1:** Signet ring piroplasms of *Theileria* spp. in RBCs (red arrow) and *Anaplasma* spp. (Yellow arrow)



**Fig 2:** Gross lesion of the liver showing marked enlargement (hepatomegaly) blue arrow



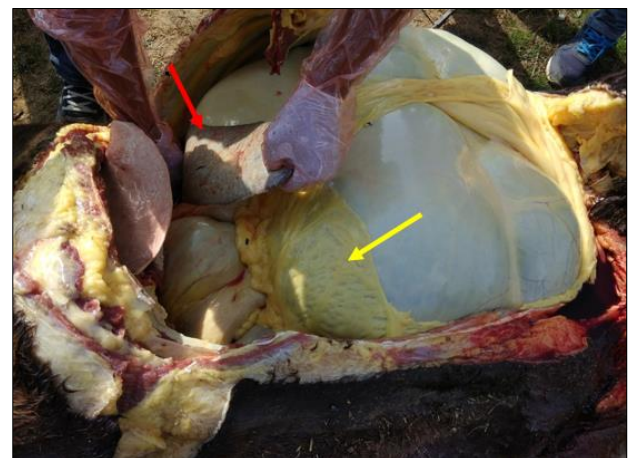**Fig 3:** Necrosed liver

**Treatment and post-treatment follow up**

The cow was treated with the single dose of injection Zubion 20 ml deep intramuscular (Buparvaquone, Intas Animal Health) @ 2.5 mg/kg b.wt single dose, injection Melonex Plus, 10 ml intramuscular (Meloxicam and Paracetamol, Intas Animal Health) @ 0.2 mg/kg b.wt. and injection Avilin Vet 07 ml (Pheniramine Maleate, MSD, Intervet India Pvt. Ltd) @ 0.5 mg/kg body weight, along with three doses of oxytetracycline long acting (Oxytetracycline-LA, Zydus AH) deep I/M @ 20 mg/kg BW at every 48 hours interval. A pour on solution of Flumethrin 40ml (Bayer Animal Health) was applied topically for control of ticks population and supplemented with Liquid Vitakind Liv @50ml orally in a day. A total 5 ml of a commercial formulation containing vitamin A 2.5 lac IU, vitamin D<sub>3</sub> 25,000 IU, vitamin E 100 IU, and biotin 12.4 mcg/ml (Intavita-H) was also given intramuscularly. After 4-5 days of treatment cattle show drooping of left ear pinna and continuing salivation from mouth, these signs indicate partial paralysis of half side of face. The rectal temperature was gone lower side (98.6 °F) and cattle and eventually succumbed after 8<sup>th</sup> day of treatment.

**Post-mortem examination**

Upon post mortem examination, the gross lesions encountered included pale mucous membrane with emaciated carcass; serosal surfaces of the abdominal organs had yellowish discoloration indicating icterus. Splenomegaly with congestion and hepatomegaly were also seen. The lungs were congested. (Fig 02, 03, 04)



**Fig 4:** Gross lesion of the spleen showing enlargement (splenomegaly) red arrow, with yellowish discoloration of the omentum (Yellow arrow).

**Discussion**

A significant feature of the disease is anemia owing to overproduction of cytokines and reactive oxygen species (Nazifi *et al.*, 2009; Saleh *et al.*, 2011) [12, 16]. Presence of oxidative stress for development of anaemia in animals affected with Theileriosis has been reported by the previous scientific workers (El-Deeb and Younis, 2009; Nazifi *et al.*, 2011) [6, 13]. Previously antioxidant potential of vitamins A, D<sub>3</sub>, E and H has been demonstrated (Singh *et al.*, 2012) [18]. Buparvaquone is a promising compound for the therapy and prophylaxis of all forms of theileriosis. The adjunction of

antioxidants and anti-theilerial agents can prevent the animals from fatal theileriosis. Moreover, large scale clinical studies are on adjunctive antioxidant is required to provide a novel therapeutic regimen of theileriosis. However, to prevent the infection of *Theileria* infection in animals *in vitro* attenuated schizont cell culture vaccine is available with trade name of 'Rakshavac T' manufactured by Indian immunologicals limited, Hyderabad (Singh *et al.*, 2014) [17]. It is further recommended that the high valued animals or high yielding animals may be vaccinated with this vaccine to prevent them with *Theileria* infection. Tetracyclines are effective against the schizonts of *T. annulata* (Mallick *et al.*, 1987) [11] and of *T. parva* (Dolan, 1981) [5], but only when used in large doses during the prepatent/incubation period of infection.

Oxytetracycline and Chlortetracycline are effective drugs against bovine anaplasmosis, provided they are given early in the course of the infection, before the onset of severe anemia (Campbell and Rew, 2013) [3]. The other treatment options such as diminazene aceturate (dosed at 3 to 5 mg/kg, IM), amicarbalide (dosed at 5 to 10 mg/kg, IM), and imidocarb (dosed at 1 to 3 mg/kg, IM) are most often used (Campbell and Rew, 2013) [3].

The most useful postmortem lesions are marked splenic enlargement and congestion (Kieser *et al.*, 1990) [9] and this is consistent with the lesions we observed in this report. The jaundice and anaemia reported in this case is due to the destruction of red blood cells and their contents being released into the blood stream. Similarly, splenomegaly with congestion and discoloration of the spleen reported in our case is in agreement with the results of (Devos *et al.*, 2006) [4], who reported that the spleen of infected cows was enlarged following anaplasmosis. This is associated with excessive destruction of defective erythrocytes by macrophages within the spleen (Devos *et al.*, 2006) [4]. Anaplasmosis is an infectious disease of cattle that causes anaemia, abortions, and death. Adult cattle have the most severe symptoms of the disease.

## References

1. Ajayi SA, Wilson AJ, Campbell RS *et al.* Experimental bovine anaplasmosis: Clinico-pathological and nutritional studies. *Research in Veterinary Science*. 1978; 25:76-81.
2. Brown CG. Control of tropical theileriosis (*Theileria annulata* infection) of cattle. *Parassitologia*. 1990; 32:23-31.
3. Campbell WC, Rew RS. *Chemotherapy of parasitic diseases*. Springer Science & Business Media, 2013.
4. DeVos AJ, Brock R, Molly JB *et al.* Tick borne diseases of cattle. In: *Australian and New Zealand Standard Diagnostic Procedures*. Sub Committee on Animal Health Laboratory Standards, 2006, 1-29.
5. Dolan TT. Progress in the chemotherapy of theileriosis. In: Irvin AD, Cunningham MP, Young AS, eds. *Advances in the control of theileriosis*. The Hague, Netherlands: Martinus Nijhoff Publishers, 1981, 186-208.
6. El-Deeb WM, Younis EE. Clinical and biochemical studies on *Theileria annulata* in Egyptian buffaloes (*Bubalus bubalis*) with particular orientation to oxidative stress and ketosis relationship. *Veterinary Parasitology*. 2009; 164:301-305.
7. Ewing SA. Transmission of *Anaplasma marginale* by arthropods. In: *Proceedings of the 7th National Anaplasmosis Conference*, (Mississippi State University, MS. USA), 1981, 395-423.
8. Kasozi KI, Matovu E, Tayebwa DS, Natuhwera J, Mugezi I, Mahero M *et al.* Epidemiology of increasing hemo-parasite burden in Ugandan Cattle. *Open Journal of Veterinary Medicine*. 2014; 4(10):220-231.
9. Kieser ST, Eriks IS, Palmer GH *et al.* Cyclic rickettsemia during persistent *Anaplasma marginale* infection of cattle. *Infectious Immunology*. 1990; 58:1117-1119.
10. Kuttler LK. *Anaplasma* infections in wild and domestic ruminants: A review. *Journal of Wildlife Diseases*. 1984; 20:12-20.
11. Mallick KP, Dhar S, Malhotra DV, Bhushan C, Gautam OP *et al.* Immunization of neonatal bovines against *Theileria annulata* by an infection and treatment method. *Veterinary Parasitology*. 1987; 24(3-4):169-173.
12. Nazifi S, Razavi SM, Esmailnejad Z, Gheisari H. Study on acute phase proteins (haptoglobin, serum amyloid A, fibrinogen, and ceruloplasmin) changes and their diagnostic values in bovine tropical theileriosis. *Parasitology Research*. 2009; 105(1):41-46.
13. Nazifi S, Razavi SM, Kianiamin P, Rakhshandehroo E. Evaluation of erythrocyte antioxidant mechanisms: antioxidant enzymes, lipid peroxidation, and serum trace elements associated with progressive anemia in ovine malignant theileriosis. *Parasitology Research*. 2011; 109:275-281.
14. OIE. (Office International des Epizooties website), *Terrestrial Animal Health Code*. Bovine Anaplasmosis, 2003. Chapters 2.3.7, accessed on July 28. <http://www.oie.int/eng/normes/mcode/a-00062.htm>
15. Ristic M. Anaplasmosis. *Bovine Medicine and Surgery*, (American Veterinary Publications Inc., Santa Barbara) 1980; 1:324-348.
16. Saleh MA, Mahran OM, Al-Salahy MB. Corpuscular oxidation in newborn crossbred calves naturally infected with *Theileria annulata*. *Veterinary Parasitology*. 2011; 182(2-4):193-200.
17. Singh AK, Verma AK, Tiwari R, Neha, Karthik K, Dhama K *et al.* Trends and advances in vaccines against protozoan parasites of veterinary importance: a review. *Journal of Biological Sciences*. 2014; 14(2):95-109.
18. Singh SK, Dimri U, Sharma MC, Swarup D, Kumar M, Tiwary R. *Psoroptes cuniculi* induced oxidative imbalance in rabbits and its alleviation by using vitamins A, D3, E, and H as adjunctive remedial. *Tropical Animal Health and Production*. 2012; 44(1):43-48.