The Pharma Innovation Journal 2019; 8(2): 569-571

www.ThePharmaJournal.com

The Pharma Innovation

ISSN (E): 2277- 7695
ISSN (P): 2349-8242
NAAS Rating: 5.03
TPI 2019; 8(2): 569-571

www.thepharmajournal.com
Received: 14-12-2018
Accepted: 17-01-2019

NS Sunilkumar
Assistant Professor, Department of Veterinary Anatomy and Histology, College of Veterinary and Animal Sciences, Mannuthy, Thrissur, Kerala, India

KV Jamuna
Professor, Department of Veterinary Anatomy, Veterinary College, Bangalore, Karnataka, India

RV Prasad
Dean, Veterinary College, Bangalore, Karnataka, India

NM Rajashailesha
Assistant Professor, Department of Veterinary Anatomy, Veterinary College, Hassan, Karnataka, India

MH Girish
Assistant Professor, Department of Veterinary Anatomy, Veterinary College, Bangalore, Karnataka, India

KT Lakshmisree
Assistant Professor, Department of Veterinary Anatomy, Veterinary College, Shivamogga, Karnataka, India

Correspondence
NS Sunilkumar
Assistant Professor, Department of Veterinary Anatomy and Histology, College of Veterinary and Animal Sciences, Mannuthy, Thrissur, Kerala, India

Studies on cytoarchitecture of parasympathetic oculomotor nucleus in the buffalo (*Bubalus bubalis*)

NS Sunilkumar, KV Jamuna, RV Prasad, NM Rajashailesha, MH Girish and KT Lakshmisree

Abstract
The cytoarchitecture of the parasympathetic oculomotor nucleus in the buffalo has been described by materials collected from eight buffalos. Serial and semi serial sections of brain stem were used for the study. The parasympathetic oculomotor nucleus was composed primarily of small and medium sized fusiform cells. The neurons had prominent nucleus with central or eccentric nucleolus and a small amount of cytoplasm. Coarse clumps of deeply stained Nissl substance was distributed in the scarce cytoplasm. The mean neuron population in the nucleus was 18,834. In the nucleus the mean diameter of medium sized neurons was 29.87 ± 0.41 µm and that of small sized neurons was 23.1 ± 0.29 µm.

Keywords: Buffalo, cytoarchitecture, parasympathetic oculomotor nucleus

Introduction
The nucleus of oculomotor nerve belongs to general somatic efferent column that control and coordinate the activity of extraocular muscles, which is the motor component. The oculomotor nucleus in addition has a visceral component belonging to the general visceral efferent column that controls the pupillary light reflex and accommodation, which is the parasympathetic component. Information on detailed morphology, extent and cytoarchitecture of parasympathetic oculomotor nucleus though extensive in man (Donzelli *et al.*, 1998) [5], cat (Roste and Dietrichs, 1988; Taber, 1961) [8, 9], and pig (Breazile, 1967) [4], studies are meager in buffaloes. Hence, the present investigation was undertaken.

Materials and methods
Brains of eight buffaloes, obtained from the Corporation Slaughter House, Bangalore formed the material used in this study. The heads were collected immediately after slaughter and were perfused with 10 per cent buffered formalin through the common carotid artery till a clean fluid came out. Perfused heads were kept for two weeks in 10 percent buffered formalin. The cranium was broken carefully and the brain along with the brainstem were removed and preserved in 10 percent buffered formalin for a further period of two weeks. The brainstems were cut and processed for paraffin technique.
Transverse serial sections of 20 µm thickness were prepared from six brains. The sections were stained with toluidine blue, neutral red and cresyl fast violet (Keller, 1960) [6] for Nissl substance for cytoarchitectural studies. The true neurons population was determined by following the procedure described by Blinkov and Ponomarev (1965) [2]. An ocular micrometer was used to measure the size of the neurons. The cells were measured at a magnification of 600. Only those cells that had an intact nucleolus were measured. The length and width of a cell was measured and the average was taken to arrive at its diameter. Similarly the size of the nucleus was also was determined. Size of 200 randomly selected neurons and their nuclei were measured. These diameters were considered as the true diameters. The true diameter of the cell body formed the basis for classification of neurons in the nuclei under study. Neurons were considered large if they were over 50 µm, medium 26 to 50 µm and small below 25 µm in diameter.

Results and discussion
Type and structure of neurons
The parasympathetic nucleus of oculomotor nerve in the buffalo consisted primarily of medium and small sized fusiform cells. Few oval, triangular and multipolar stellate shaped cells were also present (Figs. 1 & 2).

The neurons had a prominent nucleus with central or eccentric nucleolus and a small amount of cytoplasm. Coarse, clumped and deeply stained Nissl substance was distributed in the scarce cytoplasm (Figs. 3 & 4). In man (Donzelli *et al.*, 1998) [5] and in the buffalo the parasympathetic nucleus of oculomotor nerve consisted primarily of small and medium sized fusiform cells. Few oval, triangular and multipolar stellate shaped cells were also present. The neurons had a prominent nucleus with central or eccentric nucleolus and a small amount of cytoplasm. The Nissl substance was arranged in clumps near the periphery of the cell in man while in the buffalo coarse, clumped and deeply stained Nissl substance was distributed in the scarce cytoplasm.

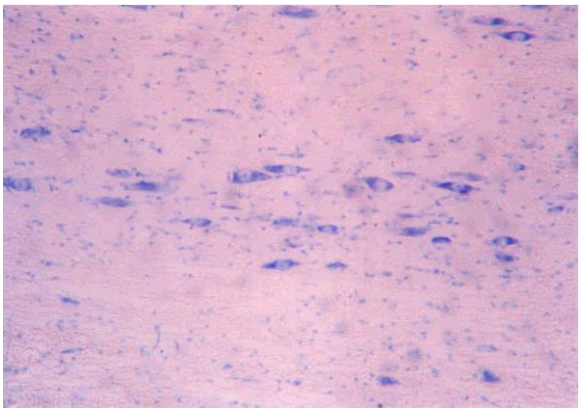

Fig 1: Photomicrograph showing types and distribution of neurons in the parasympathetic nucleus of oculomotor nerve (Toluidine blue- X100)

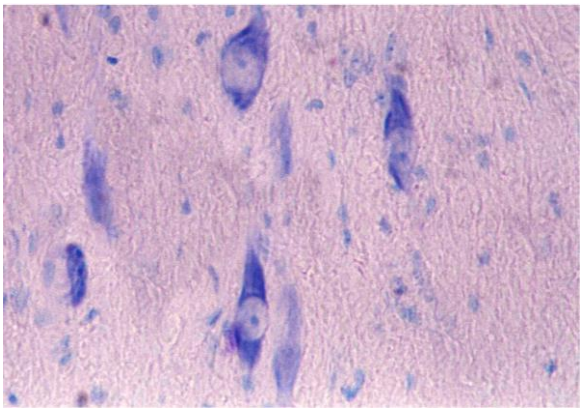

Fig 2: Photomicrograph showing some characteristic neurons in the parasympathetic nucleus of oculomotor nerve (Toluidine blue- X400)

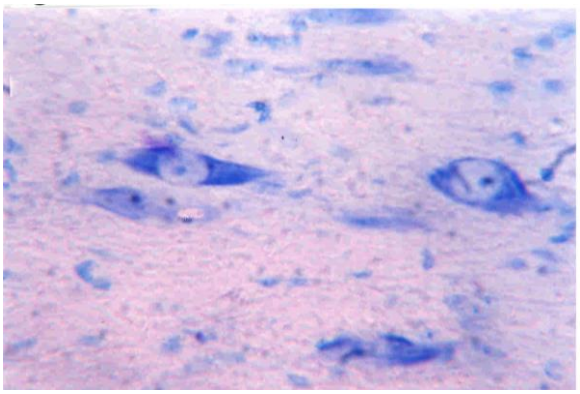

Fig 3: Photomicrograph showing small sized neurons in the parasympathetic nucleus of oculomotor nerve (Toluidine blue- X600)

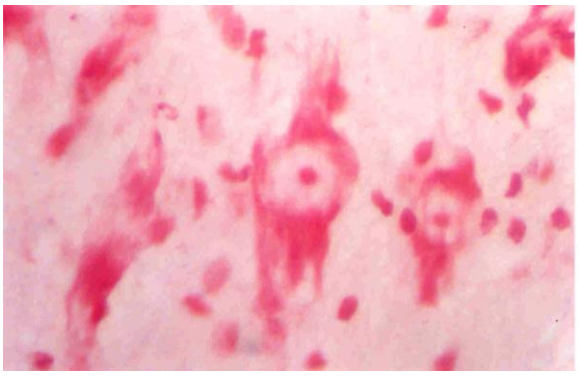

Fig 4: Photomicrograph showing medium sized neurons in the parasympathetic nucleus of oculomotor nerve (Neural red- X600)

Neuron population

The parasympathetic nucleus of oculomotor nerve was unpaired in the buffalo. The total neuron population in the nucleus ranged from 18,210 to 19,450 with a mean of 18,834 ± 193. (Table-1). The mean population of neurons in the parasympathetic nucleus of oculomotor nerve of the buffalo was 18834±193. According to Blinkov and Glezer (1968) [3] the number of neurons in the parasympathetic nucleus of oculomotor nerve in man ranged from 10860 to 15020 with a mean value of 12370. The larger proportion of neurons in the nucleus probably reflects the pupillary reflex in the buffalo.

Table 1: Total neuron population in the parasympathetic nucleus of the Oculomotor nerve

Buffalo number						Mean± SE
B1	**B2**	**B3**	**B4**	**B5**	**B6**	
19450	18875	18210	19270	18440	18760	18834±193

Size of neurons

The neurons were classified into small and medium sized neurons based on their diameter. The mean diameter of the cell body and the nucleus respectively for medium sized neurons in the parasympathetic nucleus of oculomotor nerve, were found to be 29.87 ± 0.41 µm and 14.67 ± 0.34 µm. In small sized neurons the respective diameters were 23.1 ± 0.29 µm and 12.78 ± 0.22 µm. In both the medium and small cells the diameter of the cell body was found to be approximately twice the diameter of the nucleus.

The population of medium sized neurons in the parasympathetic nucleus was 10,736 and the population of the small sized neurons was 8,098. The proportion of medium to small sized neurons in the Parasympathetic nucleus of oculomotor nerve in the buffalo was 10,736: 8,098. The approximate ratio of the two types of cells was 1.35:1. Marinkovic *et al*. (1989) [7] reported that the average diameter of the neurons in man was 25.5 µm. In the one humped camel, the neurons had a mean length of 33±5 µm and mean diameter of 10±2 µm (Adogwa, 1999) [1]. The size of neurons in the buffalo is larger than in man and small compared with the one humped camel.

It is likely that many cytoarchitectural differences have some degree of functional significance (Torvik, 1956) [10]. It has been observed in the present study that the size range of the cells in parasympathetic nucleus in the buffalo varies when compared with the size of neurons other species. Often, cells of a given shape are seen also to vary in number in the same nucleus of different species. These variations in size and shape of the constituent cells may suggestive of functional potential of the nucleus.

Acknowledgements
The authors are thankful to the Indian Council of Agricultural Research (ICAR) for providing the financial assistance through Junior Research Fellowship.

References

1. Adogwa AO. The oculomotor and trochlear nuclei in the one humped camel (*Camelus dromedaries*). Journal of Anatomy. 1999; 74(2):175-182.
2. Blinkov SM, Ponomarev VS. Quantitative determination of neurons and glial cells in the nuclei of facial and vestibular nerves in man, monkey and dog. Journal of Comparative Neurology. 1965; 125:295-302.
3. Blinkov SM, Glezer II. The human brain in figures and tables: A quantitative handbook. Basic books Inc. Publishers, Plenum press, New York, 1968, 116-118.
4. Breazile JE. The cytoarchitecture of brain stem of the domestic pig. Journal of Comparative Neurology. 1967. 129:169-188.
5. Donzelli R, Marinkovic S, Brigante L, Nilodijevic I, Maiuri F, de Divitiis O. The oculomotor nuclear complex in humans: Microanatomy and clinical significance. Surgery Radiology Anatomy. 1998; 20(1):7-12.
6. Keller TG. Manual of histologic and special staining techniques. 2nd Edition, The Blakiston Division, McGraw-Hill Book Co. Inc., New York, 1960.
7. Marinkovic S, Marinkovie Z, Filipovie B. The oculomotor nuclear complex in humans. Microanatomy and clinical significance. Neurologija. 1989. 38(2):135-146.
8. Roste GK, Dietrichs E. The feline oculomotor nucleus: morphological subdivisions and projections to the cerebellar cortex and nuclei. Anatomy Embryology (Berl); 1988. 178(1):67-75.
9. Taber E. The cytoarchitecture of brainstem of cat. I. Brainstem nuclei of cat. Journal of Comparative Neurology. 1961; 116(1):27-69.
10. Torvik A. Afferent connections to the sensory trigeminal nuclei, the nucleus of solitary tract and adjacent structures. An experimental study in the rat. Journal of Comparative Neurology. 1956. 106:51-142.