



ISSN (E): 2277- 7695
ISSN (P): 2349-8242
NAAS Rating: 5.03
TPI 2018; 7(9): 284-286
© 2018 TPI
www.thepharmajournal.com
Received: 17-07-2018
Accepted: 18-08-2018

Guguloth Ramesh
Department of Veterinary
Pathology, P.V.N.R.T.V.U.,
Hyderabad, Telangana, India

D Madhuri
Department of Veterinary
Pathology, P.V.N.R.T.V.U.,
Hyderabad, Telangana, India

M Lakshman
Department of Veterinary
Pathology, P.V.N.R.T.V.U.,
Hyderabad, Telangana, India

Alla Gopal Reddy
Department of Veterinary
Pharmacology and Toxicology,
P.V.N.R.T.V.U, Hyderabad,
Telangana, India

Histopathological changes of pancreas induced by lead and cadmium alone and combined exposure in male Wistar rats

Guguloth Ramesh, D Madhuri, M Lakshman and Alla Gopal Reddy

Abstract

Lead and cadmium are most life threatening and well known central nervous system toxicants. This study was carried out to study histopathological changes in pancreas induced by lead and cadmium alone and in combination in rats. Forty eight male albino Wistar rats were divided into 4 groups 12 rats in each group; group 1(control) was given deionized water, group 2 (lead group) was given water with lead acetate @ 30 mg/kg b.wt, group 3 (cadmium group) was given water with cadmium chloride @15 mg/kg b.wt, group 4 (combined group) was given water with both lead acetate@ 30 mg/kg b.wt and cadmium chloride @15 mg/kg b.wt for 28 days. The histopathological changes in pancreas revealed congested vessels, infiltration of mononuclear cells around blood vessels and interlobular ducts, hyperplasia of intra and interlobular ducts, loss of endocrine portion, vacuolar degenerative changes, focal atrophy of islets of Langerhans was noticed.

Keywords: Albino Wistar rats, lead and cadmium, histopathological changes in pancreas

Introduction

Lead and cadmium are the two most abundant toxic metals in the environment. The common sources of lead and cadmium are diverse in nature including natural and anthropogenic processes such as combustion of coal and mineral oil, smelters, mining and alloy processing units and paint industries. Constantly increasing environmental pollutants due to increased urbanization, industrialization and through the scientific and technical advances have stimulated interest in the study of toxic substances and its consequences to biological system [6]. Lead and cadmium are known potent toxic heavy metals which can induce oxidative stress and membrane disturbances in pancreas, rats exposed to lead and noticed vacuolation, degeneration of certain areas of cerebral cortex. Lead and cadmium enhances the production of free radicals in pancreas [1]. Pancreatic β -cells, which function in insulin biosynthesis/secretion in mammals are at greater risk of apoptosis due to ROS attack than other cell types. The mitochondria of β -cells can generate excessive levels of ROS and are both the major source of ROS and also a primary target for ROS attack. This combined with a failure of the ROS defense system, results in the relatively high vulnerability of β -cells to oxidative stress damage [2]. Lead and cadmium are well known potent toxicants which cause tissue injury creating oxidative stress.

Material and methods

Chemicals

Lead acetate and cadmium chloride were procured from Thermo Fisher Scientific India. Pvt. Ltd. Mumbai.

Experimental animals

Adult male albino rats (Wistar strain) weighing 250-280g were procured from Sanzyme laboratories Ltd., Hyderabad. The experiment was carried out according to the guidelines and prior approval of the Institutional Animal Ethics Committee (IAEC) (No.18-2017 SA).

Experimental design

A total of 48 male albino Wistar rats were randomly divided into 4 groups consisting of 12 in each group. Group 1(control) was given deionized water, group 2(lead group) was given water with lead acetate @30 mg/kg b.wt, group 3(cadmium group) was given water with cadmium

Correspondence

Guguloth Ramesh
Department of Veterinary
Pathology, P.V.N.R.T.V.U,
Hyderabad, Telangana, India

chloride @15 mg/kg b.wt and group 4 (combined group) was given water with both lead acetat @ 30 mg/kg b.wt and cadmium chloride @15 mg/kg b.wt for 28 days respectively.

Methods

To study the histopathology, six rats from each group were sacrificed on 14th and 28th day of experimental period. Detailed necropsy was conducted and gross changes if any recorded. Pancreas was collected in fixative neutral buffer formalin (NBF) for histopathology. Samples were processed, sectioned (5µm), stained with Hematoxylin and Eosin (H&E) for as per the standard protocol given (4).

Results

Section of pancreas of Group 1 on 14th and 28th day of experiment showed normal histological structure of pancreas with lobular exocrine acini and endocrine (islets of Langerhans) and inter and intra lobular ducts.

Section of pancreas of Group 2 rats, on 14th day revealed congested blood vessels and on 28th day, in addition to congested vessels, infiltration of MNCs around blood vessels and inter lobular ducts was noticed (Fig. 1).

Section of pancreas of Group 3 rats on 14th day showed congested vessels and interstitial infiltration of MNCs (Fig. 2). On 28th day in addition to above changes, intra and inter lobular duct hyperplasia (Fig. 3) and mild loss of endocrine portion was noticed.

Section of pancreas of Group 4 rats on 14th day showed vacuolar degenerative changes (Fig. 4), congested blood vessels and infiltration of MNCs (Fig. 5). On 28th day, in addition to above changes there were and focal atrophy of islets of Langerhans was noticed (Fig. 6).

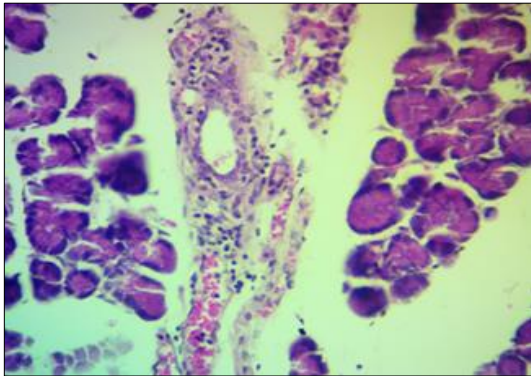


Fig 1: Microphotograph of Group 2 section of pancreas showing congested blood vessel and infiltration of MNCs around inter lobular duct on 28th day.H&E×400.

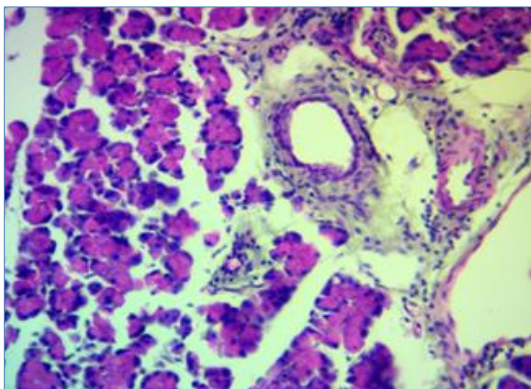


Fig 2: Microphotograph of Group 3 section of pancreas showing infiltration of MNCs around inter lobular duct on 14th day.H&E×400.

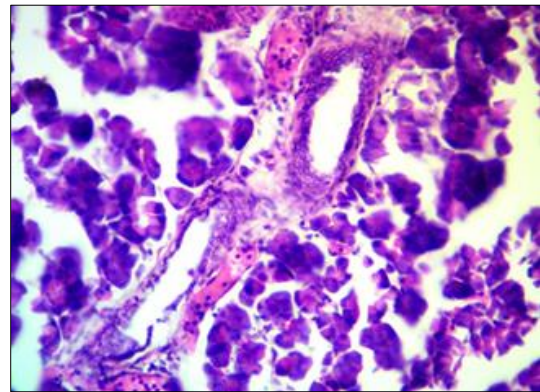


Fig 3: Microphotograph of Group 3 section of pancreas showing hyperplasia of inter lobular duct on 28th day. H&E×400.

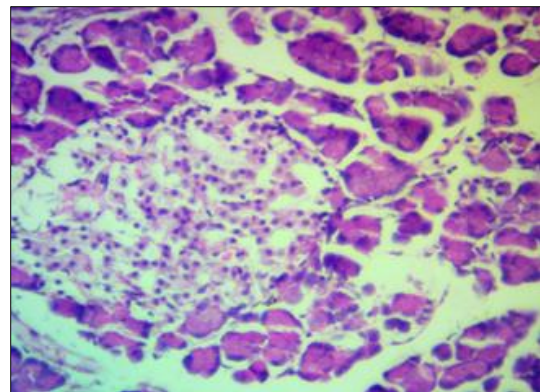


Fig 4: Microphotograph of Group 4 section of pancreas showing vacuolar degenerative changes in islets of langerhans on 14th day. H&E×400.

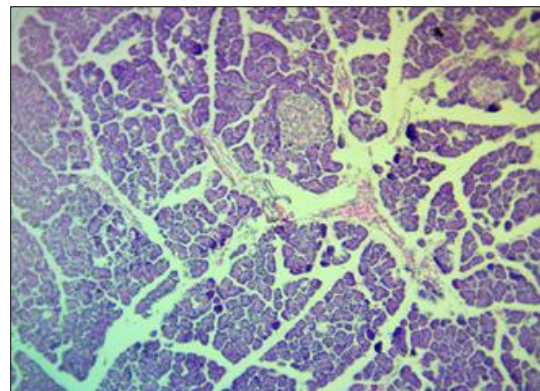


Fig 5: Microphotograph of Group 4 section of pancreas showing congested blood vessel on 28th day. H&E×100.

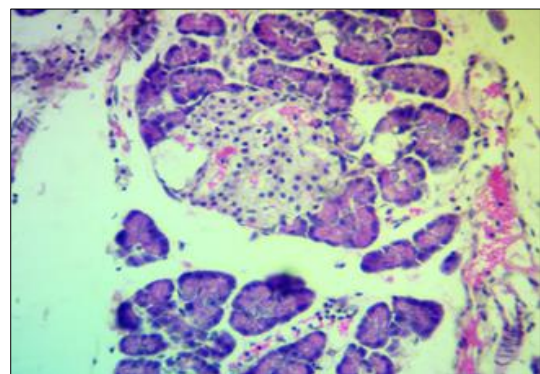


Fig 6: Microphotograph of Group 4 section of pancreas showing congestion, vacuolar degenerative changes and atrophy of islets of langerhans on 28th day. H&E×400.

Discussion

Group 2 rats, section of pancreas on 14th day revealed congested blood vessels and on 28th day, in addition to congested vessels, infiltration of MNCs around blood vessels and inter lobular ducts; these lesions were in agreement with investigation of [1].

Section of pancreas of Group 3 rats on 14th day showed congested vessels and interstitial infiltration of MNCs, intra and inter lobular duct hyperplasia and loss of endocrine portion. These findings were related to [3, 5] and explained that pancreatic β -cells, which function in insulin biosynthesis/secretion in mammals are at greater risk of apoptosis due to ROS attack than other cell types. The mitochondria of β -cells can generate excessive levels of ROS and are both the major source of ROS and also a primary target for ROS attack. This combined with a failure of the ROS defense system, results in the relatively high vulnerability of β -cells to oxidative stress damage [2] investigated and concluded that Cd was capable of inducing oxidative stress damage which causes suppression of insulin secretion and apoptosis in pancreatic islet β -cells.

Section of pancreas of Group 4 rats on 14th day showed congested blood vessels and infiltration of MNCs. On 28th day, in addition to above changes there were vacuolar degenerative changes and focal atrophy of islets of Langerhans was noticed.

Conclusion

In conclusion, this study shows that lead and cadmium are the potent endocrine disruptors which can cause damage of pancreas architecture. Lead and cadmium administered in combination has a potentiated effect. It is also concluded that lead and cadmium are the potent inducers of oxidative damage pancreas. The present study therefore provides investigatory evidence of supporting lead and cadmium toxicity in albino Wistar rats.

Acknowledgement

Authors are thankful to Associate Dean, College of Veterinary Science, Rajendranagar, Hyd. For providing necessary facility to carry out the investigation.

References

1. Al Naimi RA, Abdulhadi D, Zahroon OS, Al-Taae EH. Toxic pathological study of lead acetate poisoning in growing rats and the protective effect of crystien or calicium. Al-Anbar J Vet. Sci. 2011; 4:26-39.
2. Chang KC, Hsu CC, Liu SH, Su CC, Yen CC, Lee MJ *et al.* Cadmium induces apoptosis in pancreatic β -cells through a mitochondria-dependent pathway: the role of oxidative stress-mediated c-Jun N-terminal kinase activation. Plos One Journal, 2013; 8(2):e54374.
3. Kaneto H, Kawamori D, Matsuoka TA, Kajimoto Y, Yamasaki Y. Oxidative stress and pancreatic beta-cell dysfunction. Am. J Ther. 2005; 12:529–533.
4. Luna GLHT. Manual of Histological and Special Staining Techniques, 2nd Edition, 1968, 9-34.
5. Newsholme P, Haber EP, Hirabara SM, Rebelato EL, Procopio J. Diabetes associated cell stress and dysfunction: role of mitochondrial and nonmitochondrial ROS production and activity. J Physiol. 2007; 583:9-24.

6. Pandya C, Pillai P, Nampoothiri LP, Bhatt N, Gupta S. Effect of lead and cadmium co-exposure on testicular steroid metabolism and antioxidant system of adult male rats. Andrologia, 2012; 44(s1):813-822.