



ISSN (E): 2277- 7695  
ISSN (P): 2349-8242  
NAAS Rating: 5.03  
TPI 2018; 7(8): 589-591  
© 2018 TPI  
www.thepharmajournal.com  
Received: 16-06-2018  
Accepted: 18-07-2018

**Ajit Verma**  
Ph.D. Scholar, Dept. of  
Veterinary Gynaecology &  
Obstetrics, COVS, LUVAS,  
Hisar, Haryana, India

**RK Chandolia**  
Professor, Dept. of Veterinary  
Gynaecology & Obstetrics,  
COVS, LUVAS, Hisar, Haryana,  
India

**Rakesh Kumar**  
Veterinary Surgeon, Department  
of Animal Husbandry and  
Dairying, Haryana, India

**Nitin Soni**  
M.V.Sc. Scholar, Dept. of  
Veterinary Gynaecology &  
Obstetrics, COVS, LUVAS,  
Hisar, Haryana, India

**Sandeep Kumar**  
Assistant Professor, Dept. of  
Veterinary Gynaecology &  
Obstetrics, COVS, LUVAS,  
Hisar, Haryana, India

**Anand Kumar Pandey**  
Assistant Professor, Dept. of  
Veterinary Clinical Complex,  
COVS, LUVAS, Hisar, Haryana,  
India

**Sonu Kumari**  
Assistant Professor, Dept. of  
Veterinary Gynaecology &  
Obstetrics, COVS, LUVAS,  
Hisar, Haryana, India

#### Correspondence

**Ajit Verma**  
Ph.D. Scholar, Dept. of  
Veterinary Gynaecology &  
Obstetrics, COVS, LUVAS,  
Hisar, Haryana, India

## Ultrasonographic assessment of buffalo's liver before and after caesarean section in relation to survival rate

**Ajit Verma, RK Chandolia, Rakesh Kumar, Nitin Soni, Sandeep Kumar, Anand Kumar Pandey and Sonu Kumari**

#### Abstract

The present study has been conducted on thirteen buffaloes suffering from dystocia to assess the liver status of dam before and after caesarean section by ultrasonography as liver is the major organ which is affected during stress condition. Significantly higher pixel values of liver were observed in buffaloes which survived following caesarean section.

**Keywords:** Buffalo, caesarean section, ultrasonography, liver pixel value and survival rate

#### Introduction

The process of parturition is a stressful one and dystocia that required caesarean section makes it more stressful process as evidenced by higher basal plasma glucocorticoid concentrations on day 1 postpartum<sup>[1]</sup> in cows with dystocia which required caesarean section. The parturition in buffalo is an inflammatory process also, characterized by higher plasma concentration of a chemo attractant cytokine, interleukin-8 (IL-8) during parturition and postpartum period<sup>[2]</sup> which attracts and activates neutrophils<sup>[3]</sup>. The increased cytokines creates an inflammatory microenvironment in uterus promotes further recruitment of leukocytes in uterine tissues in a feed-forward fashion<sup>[4]</sup>. The stress associated with normal parturition and dystocia; surgery<sup>[5]</sup> as caesarean section and inflammatory response<sup>[6]</sup> can lead to oxidative stress.

Oxidative/nitrosative stress represents imbalance in the production and the elimination of reactive oxygen and nitrogen species and also decreased production of antioxidants by the body. Liver has been described as the major organ which gets attacked by reactive oxygen species (free radicals). Oxidative stress targets parenchymal, Kupffer cells, hepatic stellate cells and endothelial cells of liver. The oxidative stress induces irretrievable alteration of lipids, proteins and DNA contents and causes hepatic damage and it also modulates pathways of liver that control normal biological functions which can result in initiation and progression of various liver diseases<sup>[7]</sup>. However, diagnosis of the liver diseases has been found to be difficult in cattle due to absence of specific signs and moreover the routine laboratory tests may fail to detect liver disorder as long as one-third of the liver parenchyma remains functional and bile flow remains unobstructed<sup>[8, 9]</sup> but the diagnostic ultrasonography may help the clinician to obtain assessment of liver<sup>[10]</sup>.

Therefore, the present study was designed to observe the ultrasonographic changes of liver in dystocia affected buffaloes which underwent caesarean section to assess liver status for predicting their survivability.

#### Materials and Methods

The ultrasonography was performed on 13 buffaloes after taking case history and diagnosis of dystocia before the start of caesarean section (0 h), after 12 and 24 hours of caesarean (24 h). Ultrasonography was conducted using Toshiba Nemio-XG 3D ultrasound machine. The animals were kept in chute. No sedation was given to animals for ultrasonographic studies. The right thoracic area between 12th to 8th intercostals space was shaved for trans-thoracic ultrasonography of liver. Ultrasound gel supplied by Medi cone enterprises (Chennai) were utilized for the study. Sonography image capture and management system (Cutesono, Global softwares, Jaipur) installed in the computer attached to the ultrasound machine was used for the recording purposes and subsequent re-evaluation. The brightness and contrast were adjusted to get clear images. The near and far gains were adjusted according to the requirement to check the details of the images.

Good, clear images were frozen and saved in the machine itself for the offline analysis. Pixel values of liver were measured with the help of adobe photo shop software after obtaining saved image of liver from ultrasound machine. Post caesarean section animals were divided into two groups. First group included animals which survived after caesarean section and second group included the animals which couldn't survive after caesarean section.

**Statistical analysis**

The results are presented as mean ± SE. One way ANOVA and Independent sample t- test was employed to see the difference within group at different time interval and at same time interval between two groups, respectively. All the statistical analysis was carried out by using SPSS 16.0 software program for windows. The 5% ( $P<0.05$ ) difference was considered as significant.

**Result and Discussion**

Pixel values of the liver were assessed to evaluate changes in the liver parenchyma as it was difficult to get full image of liver for its dimensions. The measurements of pixel values of

liver obtained are shown in table 1, figure 1 and 2. The pixel value of liver ranged from 26.82 to 81.65 pixels. The mean pixel values of liver in animals of group 1 (figure 3) were  $63.51\pm5.4$  (before caesarean section),  $58.08\pm6.06$  (12 hour post caesarean operation) and  $57.24\pm6.7$  (24 hour post caesarean section,) and in animals of group 2 (figure 4) were  $52.01\pm4.28$  (before caesarean section),  $46.96\pm3.68$  (12 hour post caesarean operation) and  $43.47\pm5.68$  (24 hour post caesarean section) respectively. A significantly higher ( $p<0.05$ ) mean pixel values of liver was observed in the animals of group 1 in comparison to animals of group 2 in the present study and this variation continued up to 24 hours post caesarean section between two groups. There are no parallel reports in literature to confirm or repute our findings but the mean pixel values of liver reported in current study are in accordance with buffaloes with uterine torsion as reported by Yadav [10].

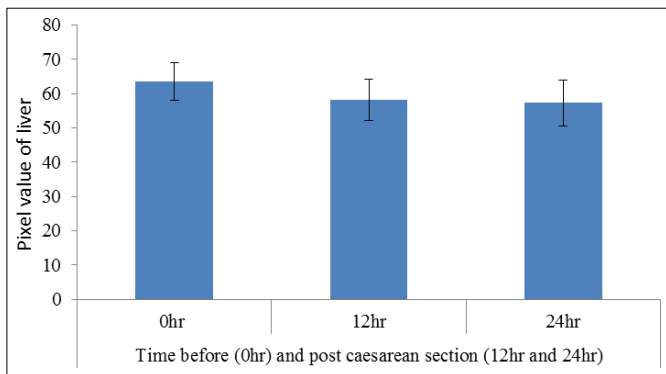
**Conclusion**

Pixel values of liver through ultrasonography could be a parameter to predict the survivability of buffaloes undergoing caesarean section.

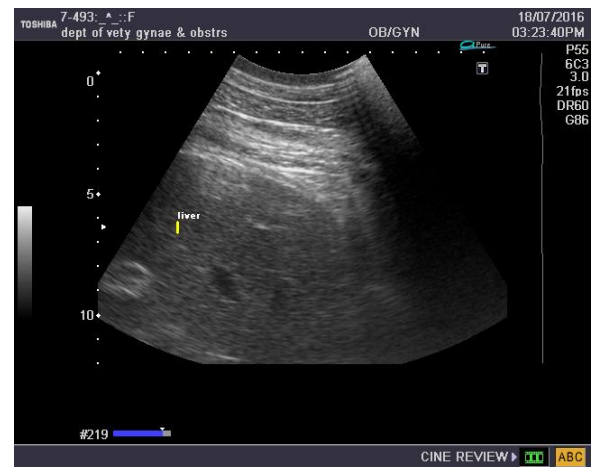
**Table 1:** Measurements of Pixel values of liver (mean ± SE) of animals survived and died

	Time before (0hr) and after caesarean section (12hr and 24hr)		
	0hr	12hr	24hr
Pixel value of liver of animals survived	$63.51\pm5.4^A$	$58.08\pm6.06^A$	$57.24\pm6.7^A$
Pixel value of liver of animals died	$52.01\pm4.28^B$	$46.96\pm3.68^B$	$43.47\pm5.68^B$

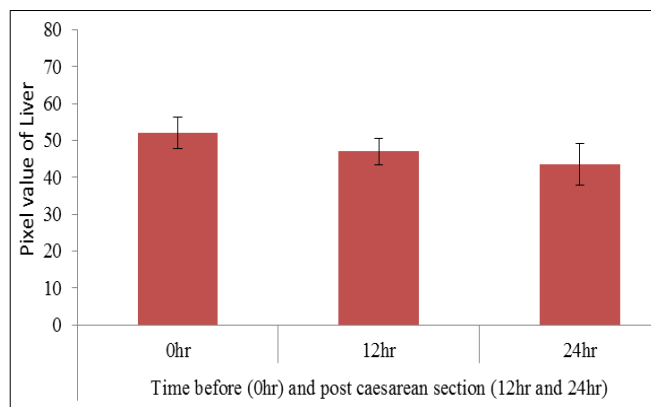
<sup>A, B</sup>different superscript differ significantly ( $P<0.05$ ) between row in a column.



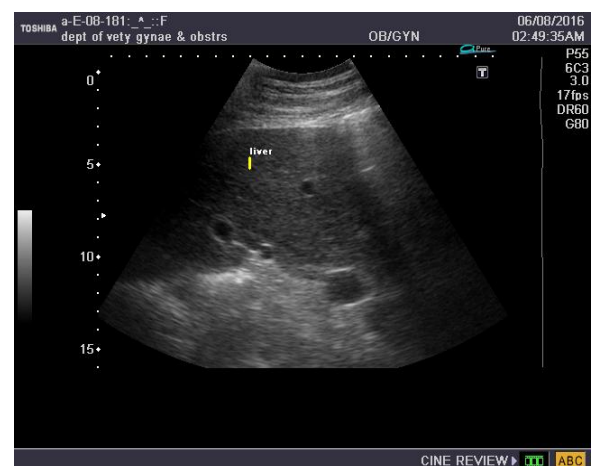
**Fig 1:** Measurements of pixel values (mean ± SE) of liver of group 1 animals (survived)



**Fig 3:** Ultrasonogram of animal from group 1(survived)



**Fig 2:** Measurements of pixel values (mean ± SE) of liver of group 2 animals (died)



**Fig 4:** Ultrasonogram of animal from group 2 (died)

## References

1. Nakao T, Grunert E. Effects of dystocia on postpartum adrenocortical function in dairy cows. *J Dairy Sci.* 1990; 73(10):2801-2806.
2. Kumar V, Kumar P, Mohan K, Sarkar M, Suresh KP, Chauhan MS *et al.* Temporal changes in circulating levels of plasma interleukin-8 during peripartum period in Murrah buffaloes (*Bubalus bubalis*) under subtropical climate. *Trop Anim Health Prod.* 2011; 43(3):669-674.
3. Bickel M. The role of interleukin-8 in inflammation and mechanisms of regulation. *J Periodontol.* 1993; 64(5):456-460.
4. Xu C, Liu W, You X, Leimert K, Popowycz K, Fang X *et al.* PGF2 $\alpha$  modulates the output of chemokines and pro-inflammatory cytokines in myometrial cells from term pregnant women through divergent signaling pathways, *MHR: Basic science of reproductive medicine.* 2015; 21(7):603-614.
5. Sathya A, Prabhakar S, Sangha SP, Ghuman SP. Vitamin E and selenium supplementation reduces plasma cortisol and oxidative stress in dystocia-affected buffaloes. *Vet. Res. Commun.* 2007; 31(7):809-818.
6. Yang FL, Li SX. Role of antioxidant vitamins and trace elements in mastitis in dairy cows. *J Adv. Vet. Anim. Res.* 2015; 2(1):1-9.
7. Li S, Tan HY, Wang N, Zhang ZJ, Lao L, Wong CW, Feng Y. The Role of Oxidative Stress and Antioxidants in Liver Diseases. *International Journal of Molecular Sciences.* 2015; 16(11):26087-26124.
8. Dirksen G. *Clinical Examination of Cattle*, Verlag Paul Parey, Berlin, Germany. 2nd edition, 1979.
9. Imran S, Tyagi SP, Kumar A, Kumar A, Sharma S. Comparative Ultrasonographic Imaging of Spleen and Liver in Healthy Crossbred Cows. *ISRN Veterinary Science* Volume, 2011; doi:10.5402/2011/419591.
10. Yadav V. Ultrasonographic studies of kidney and liver in relation to stress and circulating bio chemicals in buffaloes suffering with uterine torsion. M.V.Sc thesis submitted to LUVAS Hisar, Haryana (India), 2015.