



ISSN (E): 2277- 7695

ISSN (P): 2349-8242

NAAS Rating: 5.03

TPI 2018; 7(4): 290-292

© 2018 TPI

www.thepharmajournal.com

Received: 13-02-2018

Accepted: 14-03-2018

#### Rakesh Adepu

MVSc Surgery, CVSc,  
Rajendranagar, PVNT TVU,  
Hyderabad, Telangana, India

#### Raghavender KBP

Professor and University Head,  
Dept of Surgery and Radiology,  
Rajendranagar, PVNT TVU,  
Hyderabad, Telangana, India

#### Gireesh kumar V

Professor, Dept of Surgery and  
Radiology, Rajendranagar,  
PVNT TVU, Hyderabad,  
Telangana, India

#### Ramesh N

MVSc Veterinary Surgery and  
Radiology, CVSc,  
Rajendranagar, PVNT TVU,  
Hyderabad, Telangana, India

## A clinical study on the incidence of periodontal diseases in dogs and their surgical management

Rakesh Adepu, Raghavender KBP, Gireesh kumar V and Ramesh N

#### Abstract

Periodontal disease is a very common disease seen in canines. The present study on the incidence of dental diseases and their surgical management was conducted in 32 dogs, that were treated by manual and ultrasound scaling, polishing and dental extraction where ever necessary. dogs which had severe periodontal disease and had undergone invasive procedures were advised oral medication with Amoxicillin - Clavulanate at the rate of 20mg/Kg twice a day for ten days and application of metronidazole dental gel.

**Keywords:** Periodontal disease, Dogs, Surgical Management

#### Introduction

It is being realized now a days by the veterinarians and pet owners that oral and dental health and general health of an animal are closely interrelated, hence there is the increasing interest in the field of canine dentistry. Periodontal disease however, is reported to be extremely common with reports stating that as high as about 80% of the dogs and cats being affected (Klein 2000; Kyllar and Witter 2005; Kumar *et al.*, 2008) [9, 11, 10].

Periodontal diseases is a plaque induced pathology of any part of the tissue that holds tooth in mouth, commonly known as periodontium. plaque is an aggregate of bacteria and their by products, salivary components, oral debris and occasional epithelial and inflammatory cells (Cleland, 2000; Gorrel, 2003 and Niemiec, 2013) [3, 7, 12]. The symptoms of periodontal disease are halitosis, discolouration of the teeth, excessive salivation, variable amounts of plaque and calculus, inflamed and bleeding gingiva, gingival ulceration, purulent discharge from periodontal pockets, loss of normal gingival contour, gingival recession, furcation exposure and tooth mobility (Verstraete, 1999; Klein, 2000; Gorrel, 2003; Gioso *et al.*, 2009 and Niemiec, 2013) [9, 7, 6, 12].

Effective treatment of the periodontal disease requires removal of plaque both supragingivally and subgingivally (Cleland, 2001), extraction of affected teeth with mobility more than 1 mm or Root canal therapy for the affected tooth.

The present paper briefs about use of a combination of ultrasonic and hand scaling instruments for plaque and calculi removal along with importance of polishing and its procedure in controlling the periodontal disease and surgical extraction of the severely affected tooth.

#### Materials and Methods

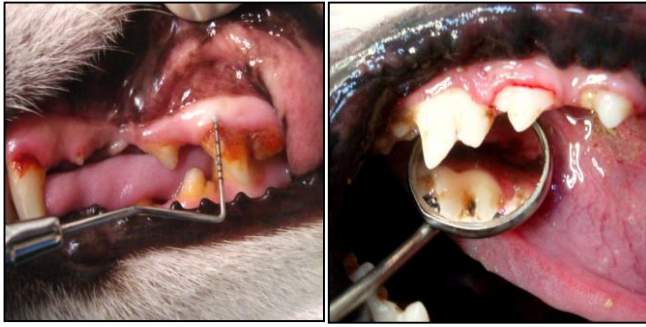The present study on the incidence of dental diseases and their surgical management was conducted in 32 dogs presented for treatment at Campus Veterinary Hospital, College of Veterinary Science, Rajendranagar, Hyderabad, Telangana.

Periodontal disease in 32 dogs was diagnosed based on the history, clinical signs. Instruments like periodontal probe, dental explorer and dental mirror were used in clinical examination of oral cavity (Fig. 1) under general anaesthesia. A clinical finding such as periodontal probing depth for all the teeth was recorded in millimetres. Once the severity of the periodontal diseases was assessed and all these cases were treated by scaling, polishing and dental extractions where ever necessary. Under general anaesthesia, the dogs were intubated and the oral cavity was rinsed with 0.2% chlorhexidine solution. After thorough dental examination, the major calculus was broken using needle holder or extraction forceps.

#### Correspondence

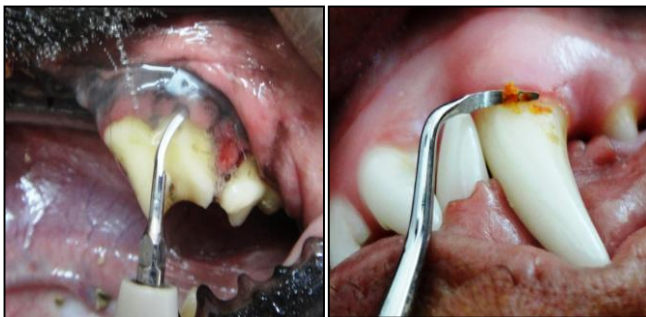##### Rakesh Adepu

MVSc Surgery, CVSc,  
Rajendranagar, PVNT TVU,  
Hyderabad, Telangana, India



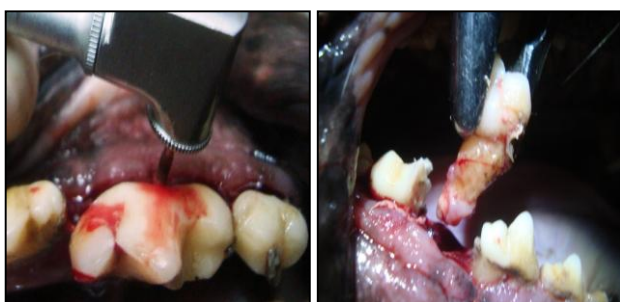
**Fig 1:** Use of Dental probe and Dental Mirror for dental examination

Ultrasound scaler, was used to remove the plaque and calculi. Supra and sub gingival ultrasonic tips were used for scaling (Fig2). Care was taken to ensure that the contact time of the tip with the tooth surface was not more than 15 seconds at a time (Niemic 2013) [12]. Following ultrasonic scaling, the residual calculi deposits if any, were removed by using hand scaling instruments like dental hoe and dental claw. Gingival curette was used subgingivally to remove the remaining calculi. Loosely attached teeth with mobility of more than one millimetre were extracted immediately after scaling (Cleland, 2000 and Gioso *et al.* 2009) [3, 6]. In case of multi rooted teeth, they were split using a cross cut fissure bur attached to a contra angle hand piece and extracted in individual pieces using extraction forceps (fig.3).



**Fig 2:** Use of Ultra sound scaler and Dental Claw for removal Tartar and Plaque.

After extraction, plaque disclosing solution was applied by using cotton swab and was rinsed with normal saline. The solution stained old plaque blue and recent plaque pink. Such identified remnants of calculi were removed by manual scaling and subsequent polishing. The teeth were polished with Medium grain polishing paste using a prophy cup attached to a micro motor contra angle hand piece and was run at a speed of 3000 rpm. Finally gingival sulcus was irrigated with normal saline and then with 0.2% chlorhexidine.

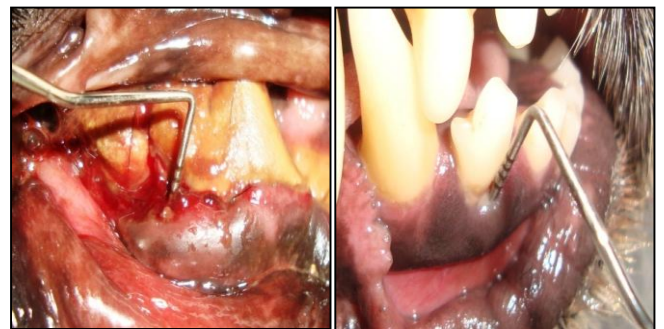


**Fig 3:** Splitting of multirooted tooth using cross cut fissure bur and Extraction

All the dogs which had severe periodontal disease and had undergone invasive procedures were advised oral medication with Amoxicillin - Clavulanate at the rate of 20mg/Kg twice a day for ten days and application of metronidazole dental gel daily till the signs of periodontal disease disappeared.

**Results and Discussion**

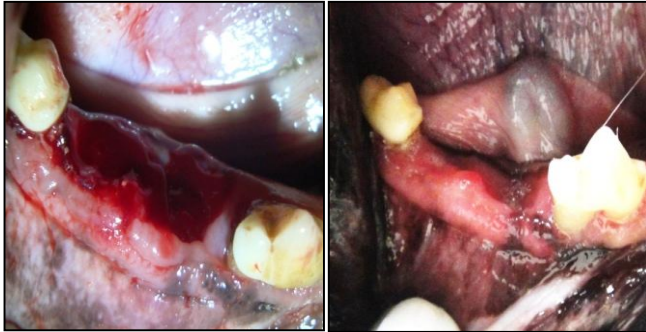
Dental diseases are common in dogs. There have been reports recording that the incidence of dental disease was as high as 60-80% of all the dogs presented for treatment (Klein, 2000; Kyllar and Witter, 2005 and Pieri *et al.*, 2012) [9, 11, 13]. Diagnosis of dental diseases using various diagnostic tests such as dental probing, (Klein, 2000; Thengchaisri *et al.*, 2008; Gioso *et al.*, 2009 and Niemic, 2013) [9, 6, 12] dental radiography (Tsugawa and Verstraete, 2000; Holmstrom *et al.*, 2007; DuPont and DeBowes, 2009 and Woodward, 2009a) [8, 4] etc., have been described in the literature published abroad. Probing the gingival sulcus using the Dental Probe, depicted the severity of the damage to the periodontal structures. Even in the dogs where the gums appeared slightly diseased, the true damage to the periodontal structures could only be gauged by probing. In the present study, in five dogs, the pocket depth was 10mm. In the other dogs, the pocket depth ranged from 3-9mm (Fig.4)



**Fig 4:** Use of periodontal probe for measuring the pocket depth.

The treatment adopted in dogs with periodontal disease in the present study was scaling, polishing and extraction of the teeth with mobility of more than one millimeter (Cleland, 2000 and Gioso *et al.* 2009) [3, 6]. Before initiating treatment, the oral cavity was rinsed with 0.2% chlorhexidine solution. The use of 0.2% chlorhexidine has been reported to reduce the oral bacterial load thereby benefiting both the patient and the operators (Cleland, 2001 and Niemic, 2013) [12] and scaling and polishing resulted in complete removal of the dental plaque and calculi. Use of the ultrasonic scaler produces aerosols loaded with bacteria which are a potential threat of infection to patient and operators. As far as possible, all the dogs were intubated and the cuff was inflated to prevent aspiration of aerosols and the dental calculi (Gibson and Hedlund, 1992) [5]. Hand instruments were also useful in removal of the remnants after ultrasonic scaling. Though the teeth appeared white and clean following dental scaling, the plaque disclosing solution was helpful in revealing the presence of residual plaque. It was observed that the scaling could be accomplished with in about 8-10 minutes. Irrigation of the gingival sulcus with normal saline followed by 0.2% chlorhexidine solution using blunt end canula facilitated removal of calculus debris and polishing paste. The chief complaint of halitosis for periodontal disease was resolved in all the dogs within 2 days. Swelling of the face seen in four cases due to periodontal disease subsided by the

end of 3 days of treatment. It was observed that healing of the bleeding and ulcerated gums was accomplished in 7 days after scaling and the site of extraction of the loose teeth was completely healed in 10 days (fig.5). Purulent discharge observed in 10 cases stopped within one day. The other symptom of loss of gingival contour, gingival recession, furcation exposure and tooth mobility, however persisted even after treatment for periodontal disease.



**Fig 5:** Appearance immediately after extraction of molar tooth and after 10th day post extraction of same dog.

Professional dental cleaning is of little value unless it is followed up by home oral health care as periodontal disease is irreversible. However, it can be controlled well with good oral care (Bonello and Squarzoni, 2008 and Pieri *et al*, 2012) <sup>[1, 13]</sup>. In the present study, only three clients reported that they had started preventive health oral care like tooth brushing after treatment of their pets for periodontal disease. This emphasized the enormous need for client education with regards to dental diseases and the importance of regular oral care of their pets. Caiafa (2007) <sup>[2]</sup>, Gorrel (2003) <sup>[3]</sup> and Niemiec (2013) <sup>[12]</sup> also made similar observations. They further stated that untreated periodontal disease leads to disease of distant organs like renal failure, diabetes mellitus and immunopathies.

The present clinical study showed that scaling and polishing of the teeth along with adequate home care resulted in control of periodontal disease.

## References

1. Bonello D, Squarzoni P. Effect of a mucoadhesive gel and dental scaling on gingivitis in dogs. *Journal of Veterinary Dentistry*. 2008; 25(1):28-32.
2. Caiafa A. Canine infectious, inflammatory and immune-mediated oral conditions. *BSAVA Manual of Canine and Feline Dentistry*. III ed. Edited by Cedric Tutt, Judith Deepprose, and David Crossley. British Small Animal Veterinary Association, 2007, 96-126.
3. Cleland CP. Nonsurgical Periodontal Therapy. *Clinical techniques in Small Animal Practice*. 2000; 15(4):221-225.
4. DuPont G, De Bowes. Periodontal Disease. *Atlas of Dental Radiography in Dogs and Cats*. I ed. Saunders Elsevier, 2009, 134.
5. Gibson KL, Hedlund CS. Aspirated dental calculus in a dog. *Journal of the American Veterinary Medical Association*. 1992; 200(4):514-516.
6. Gioso MA, Fecchio RS, Rossi JL, Nunes ALV, Rassy FB, Moura C. Endodontic Treatment of Canine Tooth of Goeldi's Marmoset (*Callimico goeldii*), 2009.
7. Gorrel C. Periodontal and Oral Inflammatory disease. *Text Book of Small Animal Surgery*. Edited by Slatter D

- H. III ed. Saunders, 2003, 2652.
8. Holmstrom S, Fitch PF, Eisner ER. *Veterinary Dental Techniques for the Small Animal Practitioner*. I ed. Mosby Elsevier, 2007, 39-497.
9. Klein T. Predisposing Factors and Gross Examination Findings in Periodontal Disease. *Clinical techniques in Small Animal Practice*. 2000; 15(4):189-196.
10. Kumar V, Kelawala N, Patil DB, Parikh PV, Barvalia DR. Epidemiological studies on periodontal diseases in dogs. *Indian journals of Veterinary Surgery*. 2008; 29(2):112-13.
11. Kyllar M, Witter K. Prevalence of Dental Disorders in Pet Dogs. *Journal of Veterinary Medicine*. 2005; 50(11):496-505.
12. Niemiec BA. *Veterinary Periodontology*. I ed. Wiley-Blackwell, 2013, 18-289.
13. Pieri FA, Daibert APF, Bourguignon A Maria EB, Moreira MAS. Periodontal Disease in Dogs. *A Bird's - Eye View of Veterinary Medicine* Edited by Dr. Carlos C.Perez-Marin, 2012, 119-140.
14. Verstraete FJM. *Oral Pathology. Text Book of Small Animal Surgery*. Edited by Slatter D H. III ed. Saunders, 2003, 2647-2648.
15. World Small Animal veterinary association. *World Congress Proceedings*, 2009.