The Pharma Innovation Journal 2018; 7(3): 354-358

www.ThePharmaJournal.com

The Pharma Innovation

ISSN (E): 2277- 7695
ISSN (P): 2349-8242
NAAS Rating: 5.03
TPI 2018; 7(3): 354-358

www.thepharmajournal.com
Received: 05-01-2018
Accepted: 06-02-2018

Skrypko VD
Department of Surgery, Faculty of Postgraduate Studies, SHEI Ivano-Frankivsk National Medical University, Ukraine

AYA Pasko
Department of Surgery, Faculty of Postgraduate Studies, SHEI Ivano-Frankivsk National Medical University, Ukraine

Correspondence
Skrypko VD
Skrypko VD
Department of Surgery, Faculty of Postgraduate Studies, SHEI Ivano-Frankivsk National Medical University, Ukraine

The justification of the use of antihypoxant therapy on the basis of study the dynamics of calcium, parathormone, phosphorus and morphological changes of the parathyroid glands in postoperative hypoparathyroidism in the experiment

Skrypko VD and AYA Pasko

Abstract
The purpose of our work was to study the manifestations of early postoperative hypoparathyroidism taking into account of morphological and histochemical changes of parathyroid glands (PTG) after thyroidectomy in the experiment and to substantiate the use of antihypoxant-antioxidant therapy in the postoperative period.
Taking into account the urgency of this complication in endocrine surgery, the severity of the consequences of hypocalcemia in the early postoperative period, especially an important social aspect of the permanent form of postoperative hypoparathyroidism, the issue of postoperative medical correction is urgently needed for the rapid recovery of functional capacity of the injured patients during operation of the parathyroid glands. Therefore, experimental work to determine morphological changes in the parathyroid glands during thyroidectomy was performed and the process of restoration of ischemic parathyroid glands under the influence of antioxidant antihypoxant therapy was demonstrated.
Modeling of hypoparathyroidism was performed according to Lopukhin Yu.M. (1971). The experiment involved 20 animals (rabbits). Animals were divided into 2 groups taking into account the management of post-operative period. Group 1 (9 animals) in the postoperative period for the purpose of analgesia received 50% solution of Analgin intramuscularly at a dose of 2 ml twice a day, for the purpose of detoxification (through the constant catheter) NaCl 0.9% was administered intravenously at a dose of 100 ml per day twice. Group 2 (9 animals), in addition to the above-mentioned treatment, received the medicine Cytoflavin at a dose of 1.5 mg/kg 2 times a day during 7 days intravenously. The control group included 2 rabbits, which were removed PTG, and then their morphology was studied normally.
It has been found by us, that surgical interventions on the thyroid gland are accompanied by laboratory and morphological changes in the parathyroid glands, while degenerative-destructive reactions are intensified until the third day of the experiment and their signs stay at the seventh day. The use of antioxidant-antihypoxant therapy, in particular, medicine Cytoflavin, reduces the manifestations of negative laboratory and pathologic morphological changes during the third day and up to the seventh day there are compensatory-reconstructive manifestations in the structural organization of PTG.

Keywords: postoperative hypoparathyroidism, thyroidectomy, antihypoxants, cytoflavin

Introduction

Operations on the thyroid gland belong to the technically complex surgical interventions. This is due to the anatomical relationship of the thyroid with neck organs [8]. Despite the widespread use of modern technical means, in particular optical devices and detailed development of techniques for thyroid gland operations, postoperative complications remain a serious problem [5].

The existing disturbing statistics on the development of complications associated with replacement therapy with calcium and vitamin D become a motivation to develop and improvement of the methods of prevention and adequate treatment of PHPT. Often the problem of postoperative hypoparathyroidism (PHPT) is not considered at the proper level, it is believed that postoperative hypocalcemia is easily corrected by the preparations of Ca and vitamin D and there are no side effects [7]. However, the results of a long-term study, which included 120 patients with chronic HPT, confirm the high risk of kidney pathology against the background of a long-term therapy with active metabolites of vitamin D and Ca medicines [5]. The existing disturbing statistics on the development of complications associated with

replacement therapy with calcium and vitamin D with antihypoxant-antioxidant action in order to reduce the ischemic lesions of PTG in the postoperative period has defined the purpose of our study.

Purpose of the study

To investigate the laboratory, morphological and histochemical changes of PTG after thyroidectomy in the experiment and to substantiate the use of antihypoxant-antioxidant therapy in the postoperative period.

Materials and Methods

Experimental animals (20 rabbits) during a period of study were kept on a standard diet; light regimen was natural, in conditions of free access to water and food.

All stages of the animal experiment were performed in compliance with the rules of the European Convention on the supervision of laboratory and other experiments involving experimental animals of different species. Animals were kept in vivarium in accordance with GLP international rules. Feeding of animals was performed 2 times a day according to the norms established by the Order of the Ministry of Health of the USSR № 1179 of October 10, 1983, "On Approval of Norms for the Costs of Feeding-Stuffs for the Laboratory Animals in Health Care Institutions". The maintenance, care of animals and all manipulations were carried out in accordance with the GLP international rules of the "European Convention on the Protection of Vertebrate Animals Used for Experimental and Other Scientific Purposes" (Strasbourg, 1985) [4, 6, 10], "Rules of the performance of works using experimental animals", approved by the Order of the Ministry of Health of Ukraine № 755 dated August 12, 1997 "On Measures for the Further Improvement of the Organization of Forms of Work with the Use of Experimental Animals" and the policy directive "General Ethical Principles of the animal experiments", approved by the First National Congress on Bioethics.

Before the experiment, animals were kept in vivarium of the Ivano-Frankivsk National Medical University for at least 10 days. In the arrival into vivarium, the animals were examined by a veterinarian.

Modeling of HPT was performed according to Lopukhin Yu.M. (1971) [3] as follows: premedication was carried out: atropine 0.25 mg/kg, dimedrolum 0.5 mg/kg – intramuscularly, anesthesia: ketamine hydrochloride 70- 100 mg/kg – intramuscularly.

The operation started with a longitudinal section on the neck, length up to 3 cm, along the midline. By the blunt dissection, the fasciae of the neck were spread, along the median line; the sternal-sublingual muscles were spread out. There were imposed two nodular skin-muscular sutures, for which the edges of the surgical wound were diverged by the clamps. Solution of Novocaine 0.5% at a dose of 0.2 ml was injected under the capsule of TG with an insulin syringe.

The glandular isthmus was prepared along the midline using thermocoagulator, the cranial and caudal vessels of both lobes of the gland were coagulated. With two anatomical tweezers, beginning from the corresponding part of the isthmus, each lobe of the thyroid gland was separated in the caudo-cranial direction, separating the recurrent nerve and parathyroid glands from the parenchyma of the thyroid gland. Hemostasis was controlled. The open muscles were taken together with the help of the figure-of-eight suture, the surface of which was irrigated with a solution of bicillin-5, to prevent purulent complications. Nodular sutures were applied to the skin.

On the day of the operation and during the first three days of the postoperative period, animals were given 50% solution of Analgin at a dose of 2 ml twice a day for the purpose of anesthesia.

After 3 and 7 days, two groups of animals were reoperated on. After the appropriate premedication and anesthesia, similar surgical access to the PTG was performed, after which the glands were removed for histological and cytological examination. Sections were made from the taken PTG which were stained with hematoxylin-eosin. Euthanasia of animals was performed after premedication by the intravenous administration of a solution of sodium thiopental in a dose that is three times greater than that one required for anesthesia.

All animals in both groups, having undergone surgical intervention before suturing the surgical wound, received intraperitoneally 1 g of ceftriaxone diluted in 10 ml of 0.25% solution of novocaine.

Depending on the management of post-operative period, all animals were divided into 2 groups. Group 1 (9 animals) in the postoperative period for the purpose of analgesia received 50% solution of Analgin at a dose of 2 ml twice a day. For the purpose of detoxification (through a constant catheter) NaCl 0.9% was injected intravenously – at a dose of 100 ml per day twice. Group 2 (9 animals), in addition to the above-mentioned treatment received medicine Cytoflavin during 7 days, firm Polisan, at a dose of 1.5 mg/kg 2 times a day intravenously. The control group included 2 rabbits, which were removed PTG, and then their morphology was studied normally.

Taking into account that Cytoflavin is a balanced complex medicine consisting of natural metabolites of the organism and coenzyme-vitamins that have antihypoxic and antioxidant effects, giving a positive effect on the processes of energy formation in the cell, reducing the production of free radicals and restoring the activity of antioxidant enzymes, it was suggested that this medicine may be effective in the treatment of postoperative hypoparathyroidism, namely, to reduce the ischemic and hypoxic lesions of the PTG after surgery on the thyroid gland [1].

Presence of central activity in this medicine further extends the range of its use in clinical practice [2].

Results of the research and their discussion

In the histologic structure of PTG of the animals of the control group, there is a clear trabecular order of parathyrocytes. The main dark cells with basophilic nucleus and cytoplasm dominate. The parathyrocyte teniae are separated by layers of loose connective tissue, as well as there are numerous blood vessels (Fig. 1).

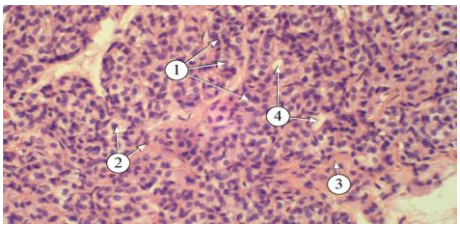

Fig 1: Histologic structure of the parathyroid gland of animals in the control group. 1 – trabecula, 2 – nuclei of parathyrocytes, 3 – layers of loose connective tissue, 4 – intraorganic blood vessels. Staining: hematoxylin and eosin. Magnification: x400.

In electronic microscopic examination there are the main dark parathyrocytes in the vast majority. Their nuclei are oval with uniformly distributed lumps of chromatin. Cisterns and sacs of granular endoplasmic reticulum, rounded mitochondria with well-ordered crests, as well as secretory granules and fat droplets are well contoured in the cytoplasm. Hemocapillaries are of visceral type. The fenestrated endothelium is located on a thin basal membrane (Fig. 2).

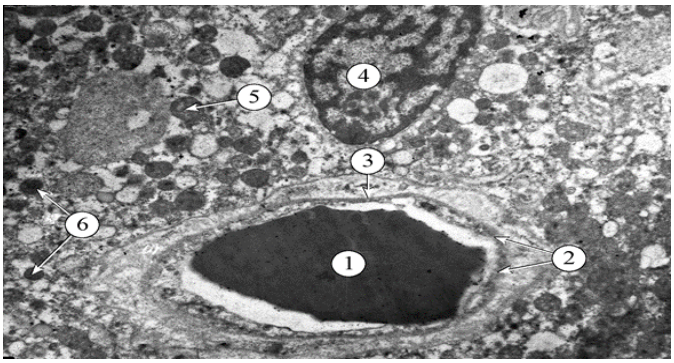

Fig 2: Ultrastructure of the thyroid gland of animals in the control group.

Markings

1. Erythrocyte in the lumen of the vessel,
2. Fenestra in the endothelium,
3. Basal membrane,
4. Nucleus of the main dark parathyrocyte,
5. Mitochondria
6. Secretory granules.

Electronic microphotography. Magnification: 6400.

In the study of PTG during the first day after the surgical intervention, there is a marked violation of their histologic structure (Fig. 3). In the field of vision, there are loci of hemorrhages and edema of the connective tissue framework, resulting in a change of architectonics; parathyrocytes are located loculiform and rosette-shaped, sometimes diffusely. Cytoplasm and nuclei of endocrine cells are light-basophilic.

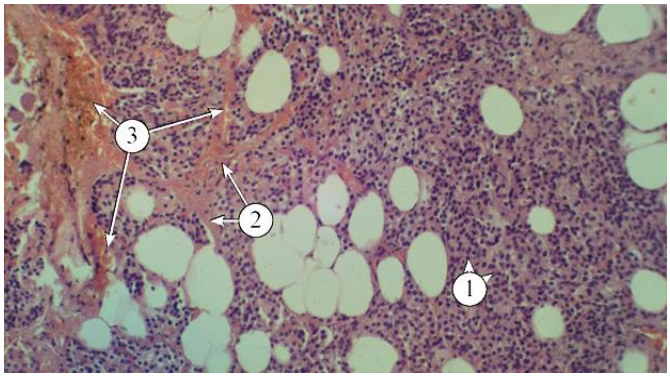

Fig 3: Histologic structure of the parathyroid gland of animals during the 1st day of postoperative period. 1 – nuclei of parathyrocytes, 2 – layers of loose connective tissue, 3 – hemorrhagic islets. Staining: hematoxylin and eosin. Magnification: x200.

Edema-dystrophic changes are also confirmed ultrastructurally. Nuclear membrane of endothelial cells is with numerous invaginations, condensed heterochromatin is concentrated under it. The cytoplasm is vacuolated; there are marked heteromorphous protrusions into the lumen of the haemocapillary. Perivascular spaces are swollen, thickened. The same swelling of the main substance and disorganization of collagen fibers are observed in the environment of parathyrocytes. Their cytoplasm is electronically lumenized, membrane organelles are expanded. During the third day of the experiment, dystrophic changes are intensified. Architectonics of PTG is violated. Parathyrocytes are grouped in an islet surrounded by swollen connective tissue stroma, which in the fields of view is hemorrhagic. The arteriole wall is swollen; the nuclei of the endothelial cells are bulged into the lumen, which is hardly visualized.

In hemocapillaries endothelial detachment is observed, its cytoplasm is electronically lumenized, basal membrane, not in all fields of view, is contoured. Perivascularly there is the sharply pronounced edema, the fibrous component is not visualized. Fibroblasts are with numerous elongated processes. At this stage of the study the macrophage-leukocyte infiltration is revealed.

During the seventh day after the surgical intervention light-optically there is the lumenized cytoplasm and nuclei of parathyrocytes which are grouped in obscure marked teniae. Connective tissue layers remain swollen. Intraorganic blood vessels are dilated; sludge of erythrocytes is pronounced (Fig. 4).

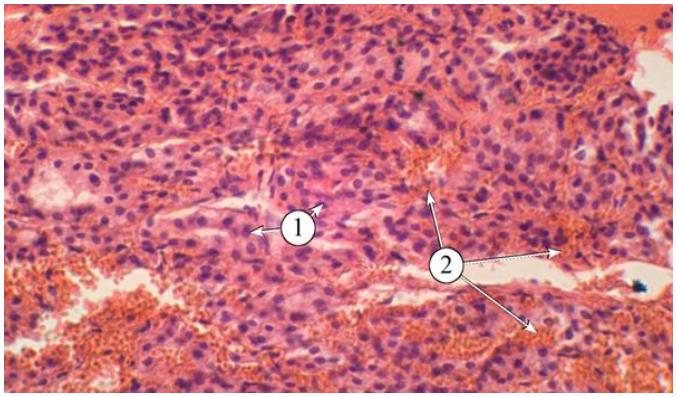

Fig 4: Histologic structure of PTG of animals during the 7th day of experimental study. 1 – nuclei of parathyrocytes, 2 – dilated blood vessels with sludge of red blood cells. Staining: hematoxylin and eosin. Magnification: x400.

Ultrastructurally in the PTG there is a vacuolation of organelles of the synthetic apparatus, several secretory granules, however, there are fat droplets. There are pronounced edematic changes in the connective tissue component of the gland. The hemovascular wall is burned-out; it is surrounded by edematosis (Fig. 5).

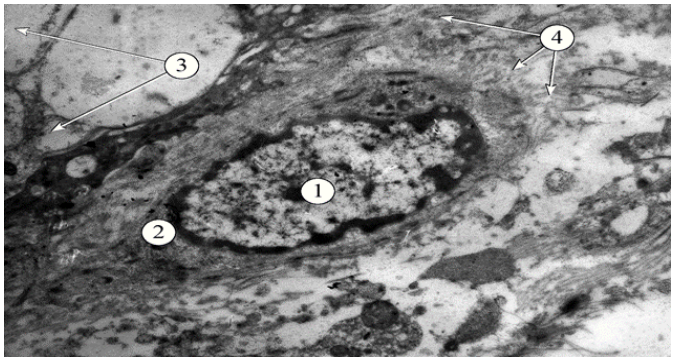

Fig 5: Ultrastructure of the parathyroid gland during the 7th day of the postoperative period.

Markings
1. Nucleus of the fibroblast,
2. Fibroblast cytoplasm,
3. Vacuoles,
4. Disorganized swollen collagen fibers.

Electronic microphotography. Magnification: 8000.
During the first day of the experiment, with the application of Cytoflavin at the light-optical level, there is the disorganization of the trabecular structure of the PTG. There is a slight edema of connective tissue framework. The wall of the blood vessels is veiled, the nuclei of the endothelial cells are poorly observed. Arterioles are spasmodic (Fig. 6).

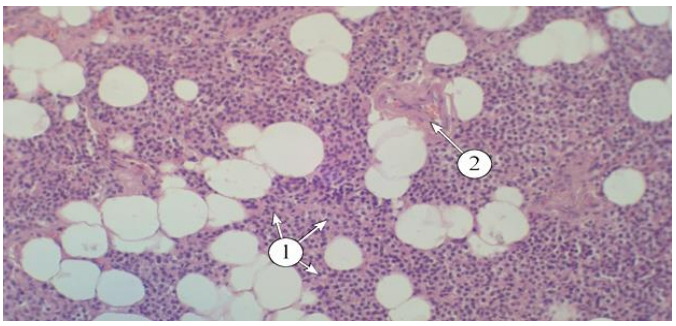

Fig 6: Histologic structure of the parathyroid gland of animals in conditions of the 1-day correction with Cytoflavin. 1 – nuclei of parathyrocytes, 2 – spasmodic arteriole. Staining: hematoxylin and eosin. Magnification: x200.

Ultrastructurally the results of light-optical research are confirmed. Parathyrocyte nuclei are round-shaped with uniformly dispersed chromatin. There is a well-developed granular endoplasmic reticulum, which at this stage of the experiment is represented by sufficiently extended cisterns and sacs. Mitochondria are round, somewhere the crests are discompleted. Secretory granules are visualized.
Hemocapillaries are dystrophically altered. Their nuclei are deformed due to the invagination of the nuclear membrane. The cytoplasm is vacuolated, forming a variety of protrusions. Organelles are hardly visualized. In the lumen it is the sludge of red blood cells.
During the third day of Cytoflavin correction, edema changes in PTG remain. This is more pronounced in the connective tissue component. Eosinophilically stained layers of fibers penetrate the gland, separating teniae of parathyrocytes. The basophilically stained nuclei and cytoplasm of the endocrine cells are well visualized in all fields of view.
Quite often, in an electronic microscopic study, lymphocytes are detected at this stage of the experiment.
Cytoplasm of parathyrocytes is sometimes electronically transparent through the loci of the extended components of the endoplasmic reticulum and the Golgi apparatus. Mitochondria are round; crests are not always clearly traceable. There are parathyrocytes with deformed nuclei. In all fields of view, secretory granules and drops of fat are detected.
During the seventh day of Cytoflavin correction there is a positive dynamics. The trabeculae of parathyrocytes are clearly differentiated, the basophilic color of their nuclei and cytoplasm dominate. Intraorganic blood vessels are found in all fields of view (Fig. 7).

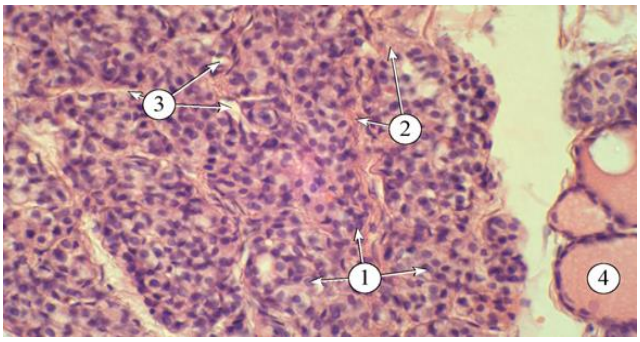

Fig 7: Histologic structure of the parathyroid gland of animals during the 7th day of Cytoflavin correction. 1 – nuclei of parathyrocytes, 2 – layers of loose connective tissue, 3 – intraorganic blood vessels, 4 – follicles of the thyroid gland. Staining: hematoxylin and eosin. Magnification: x400

In electronic microscopic examination, at this stage of the experiment, there are still signs of edema in the main substance of the connective tissue framework, however, bundles of collagen fibers are already well-organized and active fibroblasts with well-developed synthetic apparatus are detected (Fig. 8).

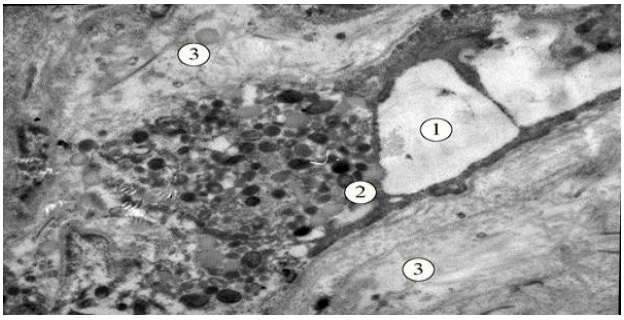

Fig 8: Ultrastructure of the parathyroid gland under conditions of 7-day correction with Cytoflavin.

Markings
1. Hemocapillary,
2. Parathyrocyte,
3. Swelling of the fibers of the connective tissue.

Electronic microphotography. Magnification: 9600
Submicroscopically parathyrocyte nuclei are rounded with evenly distributed euchromatin. The endoplasmic reticulum is represented by tubes and cisterns with fixed ribostomes. Mitochondria are with well-contoured, ordered crests. Secretory granules are well-visualized (Fig. 9).

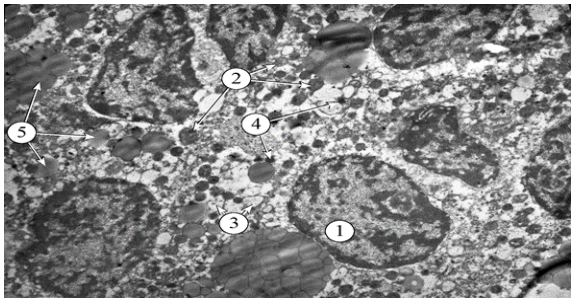

Fig 9: Ultrastructure of parathyrocytes in conditions of 7-day correction with Cytoflavin.

Markings:
1. Nucleus with euchromatin,
2. Mitochondria,
3. Granular endoplasmic reticulum,
4. Secretory granules,
5. Drops of fat.

Electronic microphotography. Magnification: 4800.

Table 1: Postoperative dynamics of laboratory changes in rabbits with simulated HPT depending on treatment

Indeces	Group 1			Group 2		
	1s day	3r day	7th day	1s day	3r day	7th day
Ca common,3.46 (3.21; 3.68) mmol/l	3.29 (3.19; 3.38)	3.27 (3.15; 3.48) P>0.0	3.26 (3.19; 3.39) P>0.05 p_1>0.05 p_3>0.05	3.27 (3.18; 3.37)	3.25 (3.12; 3.28) P>0.05	3.23 (3.11; 3.31) P>0.05 p_1>0.05 p_2>0.05 p_3>0.05
Ca ionized, 2.23 (2.08; 2.36) mmol/l	1.32 (1.23; 1.42)	1.35 (1.28; 1.49) P>0.05	1.36 (1.27; 1.53) P>0.05 p_1>0.05 p_3<0.05	1.26 (1.11; 1.35)	1.78 (1.56; 1.98) p<0.05	2.08 (1.97; 2.17) p<0.05 p_1<0.05 p_2>0.05 p_3>0.05
Phosphorus, 2.09 (1.86; 2.36) mmol/l	2.87 (2.48; 3.37)	2.75 (2.32; 3.23) P>0.05	2.35 (2.03; 2.68) p<0.05 p_1>0.05 p_3<0.05	2.86 (2.57; 3.23)	2.37 (2.08; 2.56) p<0.05	2.18 (1.91; 2.43) p<0.05 p_1<0.05 p_2<0.05 p_3>0.05
Parathormone, 38.5 (27.3; 52.8) pg/ml	11.7 (7.81; 13.93)	17.45 (12.82; 23.4) p<0.05	24.33 (16.31; 28.57) p<0.05 p_1<0.05 p_3<0.05	12.32 (8.24; 14.73)	28.41 (21.42; 31.18) p<0.05	33.37 (28.64; 45.63) p<0.05 p_1<0.05 p_2<0.05 p_3>0.05

Notes:
p – the reliability of the difference in the indices during the 3rd and 7th day in comparison with the indices of the 1st day;
p_1 – the reliability of the difference in indices during the 7th day compared to the 3rd day of treatment;
p_2 – the reliability of the difference of indices during the 7th day in group 1 of patients compared with group 2;
p_3 – the reliability of the difference of indices during the 7th day in comparison with the group of norm.

Analyzing the dynamics of laboratory parameters, depending on the treatment, we noted a faster movement towards the normalization of ionized calcium, phosphorus and parathormone in group 2 of patients compared with group 1. In group 2 of patients already during the 7th day, all indices were not significantly different from those of the norm group, whereas in group 1 we observed significant deviations in some animals. Consequently, the use of Cytoflavin contributed to the faster rehabilitation of PTG functioning and normalization of calcium-phosphorus metabolism.

Conclusions
The surgical intervention on the thyroid gland is accompanied by laboratory and morphological changes in the parathyroid gland, while the degenerative-destructive reactions are intensified until the third day of the experiment and their signs stay during the seventh day. The use of Cytoflavin reduces the manifestations of hypocalcemia, hyperphosphatemia and morphological dystrophy during the third day and up to the seventh day there are compensatory-reconstructive manifestations in laboratory parameters and structural organization of PTG.

References

1. Afanasyev VV. Cytoflavin in intensive care: a manual for physicians. SPb: St. Petersburg. 2005, 36.
2. Bulion VV. Correction of the effects of post-ischemic reperfusion injury of the brain with Cytoflavin. Bull. experiment. biologii i meditsiny. 2010; 129(2):149-151.
3. Lopukhin YuM. Experimental surgery. M. 1971; 346.
4. Khryschanovich VYa, Tretyak SI, Goranov VA *et al*. Experimental model of hypothyroidism. Med. zhurn. 2008; 4:80-82.
5. Stack B, Bimstone D, Bodenneretal D. American association of clinical endocrinologist and American college of endocrinology disease state clinical review: postoperative hypoparathyroidism – definitions and management. Endocr Pract. 2015; 21(6):675-684.
6. Park HS, Jung SY, Kimetal HY. Development of hypoparathyroid in minimal model and the feasibility of small intestinal submucosa application on the parathyroid autotransplantation. Eur Arch Otorhinolaryngol. 2015; 272(10):2969-2977.
7. Bollerslev J, Rejnmark L, Marcoccietal C. European Society of Endocrinology clinical guideline: treatment of chronic hypoparathyroid is minadults. Eur J Endocrinol. 2015; 173(2):1-20.
8. Bures C, Klatte T, Friedrichetal G. Guidelines for complication safter thyroidsurgery: pitfallsin diagnosis and advices for continuous quality improvement. Eur Surg. 2014; 46:38-47.
9. Ritter K, Elfenbein D, Schneideretal D. Hypoparathyroid is maftertotal thyroidectomy: incidence and resolution. J SurgRes. 2015; 197(2):348-353.
10. Fukui S, Endo Y, Hirayamaetal K. Identification and preservation of theparathyroid glandduring total thyroidectomy in dogs with bilateral thyroidcarcinoma: a reportofsixcases. J Vet Med Sci. 2015; 77(6):747-751.