



ISSN (E): 2277- 7695
ISSN (P): 2349-8242
NAAS Rating: 5.03
TPI 2018; 7(11): 504-508
© 2018 TPI
www.thepharmajournal.com
Received: 08-09-2018
Accepted: 09-10-2018

V Ravikanth

Veterinary Assistant Surgeon,
Animal Husbandry Department,
Telangana, India

M Lakshman

Professor and Head, Officer-in-
Charge, RUSKA Labs,
Department of Veterinary
Pathology, College of Veterinary
Science, Rajendranagar
Hyderabad, Telangana, India

D Madhuri

Professor and University Head,
Department of Veterinary
Pathology College of Veterinary
Science, Korutla, Jagtial Dist.
Telangana, India

B Kalakumar

Professor and Head, Department
of Veterinary Pharmacology and
Toxicology, College of Veterinary
Science, Rajendranagar
Hyderabad, Telangana, India

Correspondence

M Lakshman

Professor and Head, Officer-in-
Charge, RUSKA Labs,
Department of Veterinary
Pathology, College of Veterinary
Science, Rajendranagar
Hyderabad Telangana, India

Imidacloprid, spinosad and mixed toxicity induced histopathological and ultrastructural alterations in liver in broilers and its amelioration with vitamin E and silymarin

V Ravikanth, M Lakshman, D Madhuri and B Kalakumar

Abstract

The present study was designed to know the histopathological and ultrastructural alteration due to imidacloprid and spinosad (neonicotinoid and bacterial insecticide respectively) and their amelioration with vitamin E and silymarin in male Cobb broiler chicken. The experiment was carried out for 28 days. Histopathologically, group 2 liver section revealed congestion of central vein. In group 3 birds, the lesions found in liver sections were varied degrees of degeneration in hepatocytes. Histopathological changes of liver in group 4 were severe congestion of central vein and sinusoidal spaces. The microscopic changes in group 5 liver were mild vacuolar degeneration and group 6 liver sections revealed moderate to severe vacuolar degeneration. Ultrastructurally, group 2 liver revealed altered shape and size of nucleus and mitochondria. Group 3 liver section revealed mild hypertrophy of Kupffer cells and condensed mitochondria. Group 4 liver revealed swollen hepatocyte, disrupted and discontinuous rough endoplasmic reticulum. Group 5 liver was characterized by vacuolation in cytoplasm and variation in shape and size of nucleus. Group 6 liver showed mild to moderate vacuolar degeneration in cytoplasm.

Keywords: Spinosad, imidacloprid, Vit E, silymarin, histopathology, electron microscopy

Introduction

The ancient history reveals that livestock and poultry are co-existing species with human culture evolution by playing an important role in economy in addition to food security. Indian peasants especially small and marginal farmers of Telangana State dependents on backyard poultry as a source of livelihood. In pre independent India poultry farming was restricted to households, in post independent India due to technological advancement and nutritional consciousness together put a massive demand on poultry for its products like chicken and eggs. Due to various reasons the poultry farming in India has grown into an industry status and contributing considerable share in nations GSDP. Due to advancement in molecular technology in poultry industry an average production has alarmingly increased intern helped in increased usage of different feed ingredients. As per NRC (1994) ^[1] recommendations major portion of feed should contain grains like maize and sorghum as a source of energy. Soya bean, groundnut and cotton seed cakes as a source of vegetable protein. Under the light of success of green revolution indiscriminate use of insecticides and pesticides has been increased enormously in grain crop cultivation. However, their use lead to widespread concern because of their potential adverse effect on animal and human health (Al-saleh, 1994) ^[2].

Among all available insecticides spinosad (SPD is a bacterial origin and introduced in market in 1997 due its unique feature like high efficacy, broad spectrum, low mammalian toxicity and good environmental profile (Hertlein *et al.*, 2011) ^[5]. Imidacloprid (IM) is a potent and most widely used insecticide introduced in 1991 (Yamamoto and Casida. 1999) ^[17].

Materials and Methods

In the present experiment, total of 120 day old male broiler chicks (*Cobb* strain) weighing between 32 - 34 g were procured from a commercial hatchery. On arrival, the chicks were individually weighed, wing banded and divided into six groups of 20 each. The chicks were housed in battery brooders located at poultry experimental station (PES) and maintained under identical conditions throughout the course of experiment. The experiment was conducted with prior approval of the Institutional Animal Ethics Committee (IAEC).The experimental design adopted for the present study is shown in Table 1.

Table 1: Showing experimental design.

Group	No. of birds	Treatment
1	20	Control
2	20	Imidacloprid @ 50 PPM in feed
3	20	Spinosad @ 1000 PPM in feed
4	20	Imidacloprid @ 50 PPM + Spinosad @ 1000 PPM in feed
5	20	Imidacloprid @ 50 PPM + Spinosad @ 1000 PPM + Vitamin E @ 20 PPM in feed
6	20	Imidacloprid @ 50 PPM + Spinosad @ 1000 PPM + Silymarin @ 1000 PPM in feed

All birds have free access to fresh feed and water *ad libitum* throughout the experimental period.

Growth Rate

Individual body weights of all the birds were recorded by using electronic balance on day one and subsequently on 7th, 14th, 21st and 28th day of experiment to study the body weight gains.

Histopathology

The tissue samples of liver (1×1 Cm³) were collected and fixed in 10% neutral buffer formalin (NBF) soon after sacrifice. The samples were processed, sectioned (5µm) and stained with Hematoxylin and Eosin (H&E) for histopathological examination as per the standard procedure (Luna, 1968) [8].

Ultra Structural Pathology

The samples of liver (1×1 mm³) were collected and preserved in 2.5% glutaraldehyde (PBS based EM grade) and processed for transmission electron microscopic (TEM) study as per the standard protocol (Lakshman, 2014) [9] given below.

Soon after sacrifice thin slices of liver tissues were dissected into 2.5% glutaraldehyde (Sigma Aldrich, USA) in 0.1M phosphate buffer (pH 7.3 stored at 4 °C), washed in buffer, post fixed in 1% osmium tetroxide (Sigma Aldrich, USA) in 0.1M phosphate buffer, dehydrated in ascending grades of acetone (Qualigens fine chemicals, Mumbai), embedded in Spurr's (Spurr, 1969) [16] resin (SPI-supplies, araldite 6005 Embedding Kit, USA) and were incubated (universal incubator-NSW-151) 72 hours at 60 °C for complete polymerization of the tissue. Semi thin (700-800 nm) sections

were made with ultra-microtome (Leica ultra-cut UCT-GA-D/E-100, Germany), stained with 1% toluidine blue (Qualigens fine chemicals, Mumbai) and observed under light microscope (Olympus -AX 70, USA) to locate exact area, to remove extra resin if any for making ultra-thin sections (50 nm thickness). Suitable ultra-thin sections were mounted on copper grids (SPI supplies, USA) allowed to air dry for overnight and were stained with saturated Urenyl Acetate (UA) and 1% Reynold's Lead Citrate (LC) as per Bozzala and Russels (1998) [3]. All grids were dried at room temperature and observed under TEM (H-7500, Hitachi, Japan).

Statistical Analysis

Data obtained were subjected to statistical analysis by applying one way ANOVA using statistical package for social sciences (SPSS) version 16.0. Differences between means were tested by using Duncan's multiple comparison tests and significance level was set at P < 0.05 (Snedecor and Cochran, 1994) [14].

Results and Discussion

Body weight

There is a significant reduction in body weight in group 2, 3 and 4 when compared to control. This decrease in body weight gain is due to decreased feed and water intake as a result of hepato, renal toxicity. The findings in group 2 are in accordance with the earlier reports of Koshlukova (2006) [7] and Sasidhar babu *et al.* (2014) [13] and the findings in group 3 were in agreement with Yano *et al.* (2002) [18] Mansour *et al.* (2007). In amelioration groups i.e. group 5 and 6 showed a significant improvement in comparison with group 4 indicating the protective action of ameliorating agents.

Table 2: Weekly body weight gain (g) in different groups.

Group	Day 7	Day 14	Day 21	Day 28
Group 1	110.88±1.28 ^a	156.6±8.72 ^a	367.68±16.17 ^a	366.28±31.55 ^a
Group 2	100.9±1.96 ^b	126.27±8.33 ^b	312.61±17.64 ^b	264.34±6.85 ^b
Group 3	100.05±2.19 ^b	125.15±2.85 ^b	297.66±7.37 ^b	264.11±2.96 ^b
Group 4	87.53±4.78 ^c	100.6±10.54 ^c	202.62±18.91 ^c	204.86±4.04 ^c
Group 5	99.03±1.02 ^b	123.72±3.49 ^b	256.55±25.66 ^b	276.70±28.53 ^b
Group 6	97.55±2.79 ^b	123±5.25 ^b	264.76±14.99 ^b	273.51±15.38 ^b
P value	*	*	*	*

Values are Mean ± SE (n=6); one way ANOVA

Means with different superscripts in a column differ slightly at P<0.05 (*).

Histopathology and ultrastructural pathology

Liver section from group 2 showed mild to moderate dilation of sinusoids, dilation and mild congestion of central vein (Fig. 1) which are in agreement with the observations of Sasidhar Babu *et al.* (2014) [13] in layer birds, Omiaama (2004) [12] in male Japanese quails and Kammon *et al.* (2010) [6] in layer chicken. In group 3 of 28th day liver sections revealed severe dilation of sinusoids and degeneration of hepatocytes (Fig. 3), similar observations were recorded in male rats by Aboul-Enein *et al.* (2012) [11] on oral administration of SPD @ 347.49 mg/Kg b. wt. In group 4 there was severe dilation of central

vein, complete loss of architecture and focal area of lymphocytic infiltration (Fig. 5). The severity of lesions from mild to severe might be due to prolonged and cumulative accumulation of metabolites of IM and SPD and its combination. The liver is the principal target organ for detoxification of any intoxicants. In the course of degenerative changes, repair and regeneration few cells might undergo the process of necrosis due to covalent binding of reactive electrophilic metabolites to liver macromolecules (Gardner and Cluff, 1970) [4]. In group 5 birds of 28th day revealed mild to moderate congestion in central vein and

moderate to severe dilation of sinusoids and degenerating hepatocytes (Fig. 7). In group 6 moderate to severe degeneration of hepatocytes with severe dilation of central vein and sinusoids on 28th day of the experiment (Fig. 9). On perusal of literature research on mixed toxicity of IM+SPD and its amelioration with Vit E and Silymarin is not documented. The vacuolation of hepatocytes might be due to retention of fluid inside the cell resulting in cloudy swelling which might be due to reduction of energy necessary for regulation of ion concentration of the cells/hypoxia/oxidative stress (Omiamma, 2004) [12].

Ultra-thin sections of liver in group 2 revealed altered shape and size of hepatocyte and mitochondria, pyknotic nucleus with mild margination of chromatin (Fig. 2), these findings were in accordance with Sasidhar Babu *et al.* (2014) [13] in layer birds and Soujanya *et al.* (2013) [15] in male rats, reveals the toxic effect of intoxicants at this level. Group 3 liver revealed disintegrating nucleus, condensed mitochondria, altered shape and size of hepatocyte and mitochondria (Fig. 4). Group 4 liver revealed swollen hepatocyte, disrupted and discontinuous rough endoplasmic reticulum and swollen nucleus (Fig. 6). Group 5 liver was characterized by the presence of condensed mitochondria, vacuolation in cytoplasm and variation in nucleus (Fig. 8). In group 6 liver there was congestion and dilation of sinusoids and mild to moderate vacuolar degeneration in cytoplasm on day 28 of the experiment (Fig. 10), Vacuolation was due to the intralysosomal accumulation of lamellar bodies and is consistent with the effects induced by a cationic amphiphilic drug i.e. SPD (Yano *et al.*, 2002) [18].

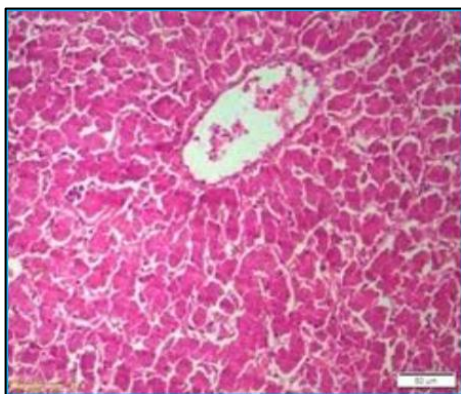


Fig 1: Liver showing mild congestion of central vein (H&E 50µm) (Group 2 day 28)

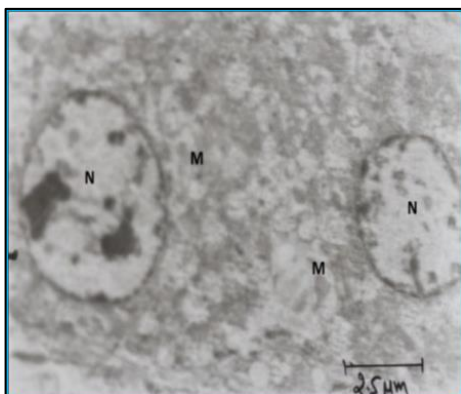


Fig 2: TEM of liver showing moderate swelling of nucleus (N) and altered shape and size of mitochondria (M): UA & LC 7720x (Group 2, day 28)

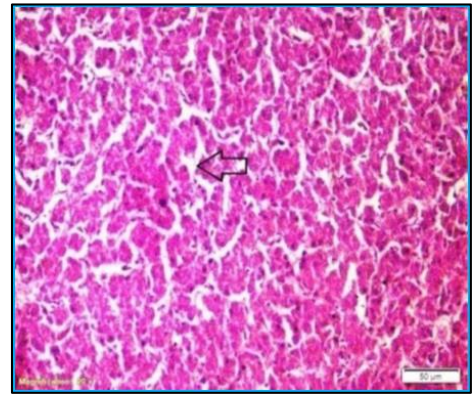


Fig 3: Liver showing degeneration of hepatocytes (H&E 50µm) (Group 3 day 28)

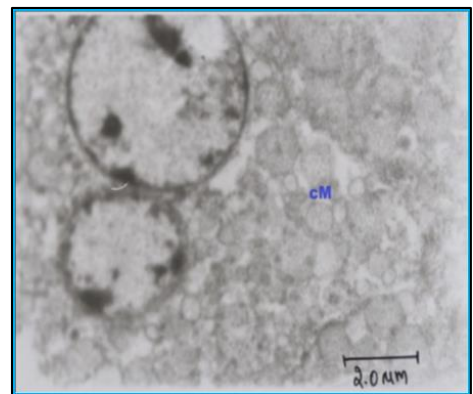


Fig 4: TEM of liver showing disintegration of nucleus and condensed mitochondria (cM). UA & LC 9650x (Group 3, day 28)

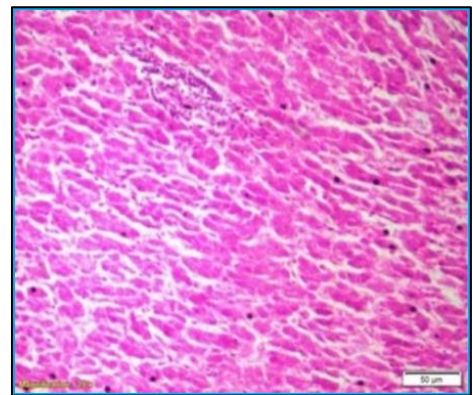


Fig 5: Liver showing necrosis of hepatocytes and focal infiltration of lymphocytic infiltration (H&E 50µm) (Group 4 day 28)

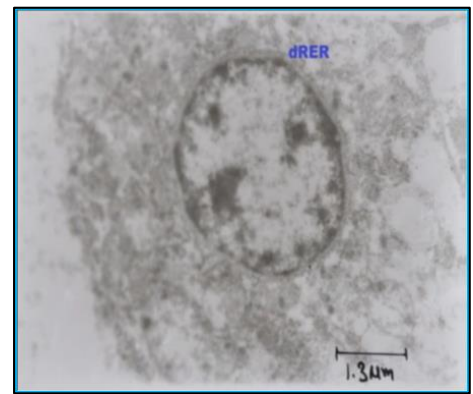


Fig 6: TEM of liver showing disrupted rough endoplasmic reticulum (dRER) and indistinct nuclear membrane. UA & LC 15440x (Group 4, day 28)

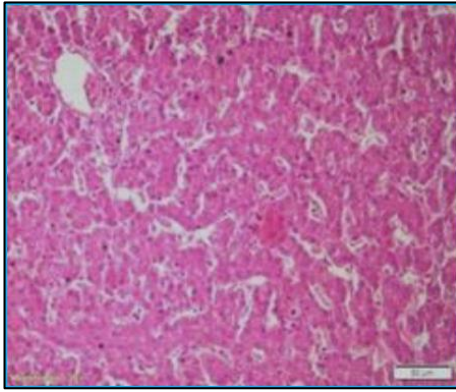


Fig 7: liver showing degenerating hepatocytes (H&E 50µm) (Group 5 day 28)

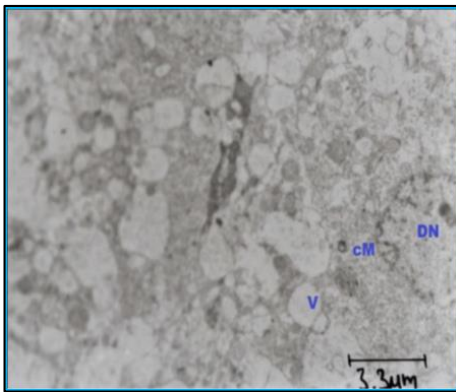


Fig 8: TEM of liver showing vacuolar degeneration (V) in cytoplasm, condensed mitochondria (cm) and disintegrating nucleus (DN). UA & LC 5790x (Group 5, day 28)

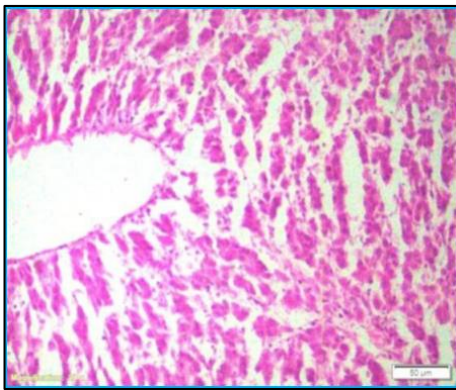


Fig 9: Liver showing dilatation of central vein (H&E 50µm) (Group 6 day 28)

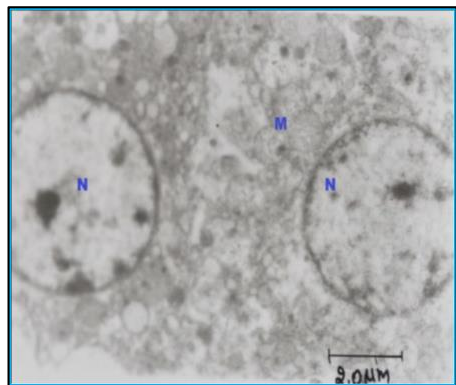


Fig 10: TEM of liver showing vacuolar degeneration of mitochondria (M) with variation in shape and size of nucleus (N). UA & LC 9650x (Group 6, day 28)

Conclusion

Based on the results obtained in the present study, it can be concluded as:

1. IM, SPD and its combination resulted in mild, marked and severe histopathological and ultrastructural changes. The present dose levels (IM @ 50 ppm and SPD @ 1000ppm) were found to be hepatotoxic in nature.
2. The co-administration of vitamin E and silymarin @ 20 and 1000 ppm revealed mild improvement in all the above parameters as a part of initiation in repair and regeneration.
3. Based on the observations in the present experiment there was a need to study the toxic effects of these insecticides in food animals as they are potential in causing hepatotoxicity.

References

1. Aboul-Enein AM, Aboul-Soud MAM, Hamed KS, Hanaa FMA, Zeinab YA, Aman MM, John PG. Hepatoprotective effects of anti-oxidants against non-target toxicity of the bio-insecticide spinosad in rats. *African Journal of Pharmacy and Pharmacology*. 2012; 6(8):550-559.
2. Al-saleh IA. Pesticides: A review article. *Journal of Environmental Pathology, Toxicology and Oncology*. 1994; 13:151-161.
3. Bozzala JJ, Russel LD. *Electron Microscopy Principles Techniques for Biologists*. 2nd ed., Jones and Barlett Publishers, Sudbury, Massachusetts. 1998; 19-45 and 72-144.
4. Gardner P, Cluff LE. The epidemiology of adverse drug reactions: A review and prespective. *Johns Hopkins Med. J*. 1970; 126:77.
5. Hertlein M, Gary DT, Bhadriraju S, Christos GA. "Spinosad: A new natural product for stored grain protection". *Stored products*. 2011; 47:131-146.
6. Kammon AM, Brar RS, Banga HS, Sodhi S. Patho-Biochemical studies on hepatotoxicity and nephrotoxicity on exposure to chlorpyrifos and imidacloprid in layer chickens. *Veterinarskiarhiv*. 2010; 80(5):663-672.
7. Koshlukova SE, Reed R, Moore TB. Imidacloprid: risk characterization document dietary and drinking water exposure. Health Assessment Section, Medical Toxicology Branch, Department of Pesticide Regulation, California Environmental Protection Agency, 2006.
8. Luna GLHT. *Manual of histological and special staining techniques*. 2nd ed., The Blakistone Division McGraw-Hill Book Company, Inc. New York, Toronto London. 1968; 1-5 and 9-34.
9. Lakshman M. *Electron Microscopy as a tool in research and disease diagnosis*, Lead paper compendium published in presented in IAVP annual conference XXXI, held at Ananad, Gujarat, India. 13th to 15th Nov, 2014, 139-160.
10. Mansour SA, Mossa AH, Heikal TM. Haemotoxicity of a new natural insecticide Spinosad on male albino rats. *International Journal of Agriculture and Biology*. 2007; 9(2):342-346.
11. NRC. *Nutrient Requirements of poultry*. National Academy press, Washington, DC, 1994.
12. Omiaia SE. Protective effect of vitamin C and glutathione against the histopathological changes induced by imidacloprid in the liver and testis of Japanese quail. *Egyptian journal of Hospital Medicine*. 2004; 16:39-54.
13. Sasidhar Babu N, Kumar AA, Reddy AG, Amaravathi P,

Hemanth I. Chronic experimental feeding of imidacloprid induced oxidative stress and amelioration with vitamin C and *Withania somnifera* in layer birds. International Journal of Science, Environment ISSN and Technology. 2014; 3(5):1679-1684.

14. Snedecor GW, Cochran G. Statistical methods, 8th ed., IOWA State University Press, Amer, IOWA, USA, 1994.
15. Soujanya S, Lakshman M, Kumar AA, Reddy AG. Evaluation of the protective role of vitamin C in imidacloprid-induced hepatotoxicity in male Albino rats. Journal of Natural Science, Biology and Medicine. 2013; 4(1):67.
16. Spurr AR. A low viscosity epoxy resin embedding medium for electron microscopy. Journal of Ultrastructural Research. 1969; 26:31-43.
17. Yamamoto I, Casida J. Nicotinoid Insecticides and the Nicotinic Acetylcholine Receptor. Springer-Verlag, 1999, 3-27.
18. Yano BL, Bond DM, Novilla MN, McFadden LG, Reasor MJ. Spinosad insecticide: Sub-chronic and chronic toxicity and lack of carcinogenicity in Fischer 344 rats. Toxicological Sciences. 2002; 65(2):288-298.