



ISSN (E): 2277- 7695
ISSN (P): 2349-8242
NAAS Rating 2017: 5.03
TPI 2017; 6(7): 337-338
© 2017 TPI
www.thepharmajournal.com
Received: 06-05-2017
Accepted: 07-06-2017

Pottabathula Mallesh
Veterinary Assistant Surgeon,
Veterinary Dispensary, Koppole
(K), Kethepally mandal,
Nalgonda District, Telangana

Kontham Sampath
M.V.Sc Scholar, Department of
Animal Genetics and Breeding,
College of Veterinary Science,
Rajendranagar, PVNR TVU,
Hyderabad, Telangana

Gouru Raju
M.V.Sc Scholar, Department of
Gynaecology and Obstetrics,
College of Veterinary Science,
Rajendranagar, PVNR TVU,
Hyderabad, Telangana

Successful management of atresia ANI (congenital defect) in non-descript calf: A case report

Pottabathula Mallesh, Kontham Sampath and Gouru Raju

Abstract

A case of perineal congenital defect (atresia ani) has been reported in non-descript calf and its successful management through surgical intervention.

Keywords: Atresia ani, congenital defect, Calf

1. Introduction

Atresia is the most commonly reported anomaly of the anus and rectum [9]. Anal atresia is the failure of the anal membrane to break down to make an anal orifice and it has been reported as the most frequently encountered anomaly in calves [2]. Congenital malformation sometimes leads to perinatal mortality, and it may also decrease maternal productivity and reduce the value of the defective neonates. Severe defects result in abortion of the calf or a return to service of the calf and cow. Congenital anomalies have been estimated to occur in 0.2%–5% of calves [1]. Atresia ani, (imperforate anus) is a congenital abnormality characterized by persistence of the anal membrane resulting in a thin membrane covering the normal anal canal or is the failure of the anal membrane to break down [7]. Most of congenital malformations was atresia ani and most frequently encountered in male calves and pigs [6].

Case History and Clinical Observations

A three day old female, non-descript cattle calf was presented at Veterinary Dispensary, Koppole, Nalgonda District, Telangana (India) with the history of non-passage of faeces since birth. After birth, calf was stand and suckle normally but weak. On clinical observation, closely find with principal clinical signs of dull, depression, anorexia, attempt of defecation and mild abdominal distention. Also the signs of tenesmus and abdominal pain were observed but does not voided out the faeces. The case was diagnosed as atresia ani and handover for surgical intervention.

Treatment and Discussion

The perineal region below the base of the tail was prepared for aseptic surgery. The calf was controlled in sternal recumbency and local infiltration was achieved with 2% lignocaine hydrochloride. A cruciate incision was made over the bulging of the anus and ends of the incision were united to dissect out a circular piece of skin. The rectum was exposed after separation of the perineal muscles and the blind end of the rectum was brought to the level of anal sphincter and fixed to the perineum after duly snipping the tip of the blind end of the rectum. The circumference of the rectal opening was sutured by application of interrupted sutures using braided black silk No. 1 between rectal mucosa and skin to make a permanent anal orifice (Figure 1). Post-operatively, amoxicillin-cloxacillin @ 1 g for 5 days and meloxicam @ 3 ml for 3 days were administered intramuscularly followed by routine dressing with povidone iodine ointment and application of topicure spray as a fly repellent. The calf showed normal in defecation with minimum tenesmus and active in nature on the 3rd post-operative day and the sutures were removed on 11th post-operative day.

Atresia ani has been reported to be a heritable condition in pigs and calves [4]. Some authors reported that the most congenital anomalies of digestive system observed in calves were atresia ani and atresia recti [3, 5, 8]. Besides, the anomalies of urinary system such as renal agenesis, polycystic kidney and skeleton system such as coccygeal or sacral vertebral agenesis were observed at the same time in calves.

It could be concluded that anal reconstruction is the only treatment for atresia ani in newborn animals.

Correspondence

Pottabathula Mallesh
Veterinary Assistant Surgeon,
Veterinary Dispensary, Koppole
(K), Kethepally mandal,
Nalgonda District, Telangana

It is recommended in ruminants as it saves life of animal, improves body weight gain and reduces herd economical loss.

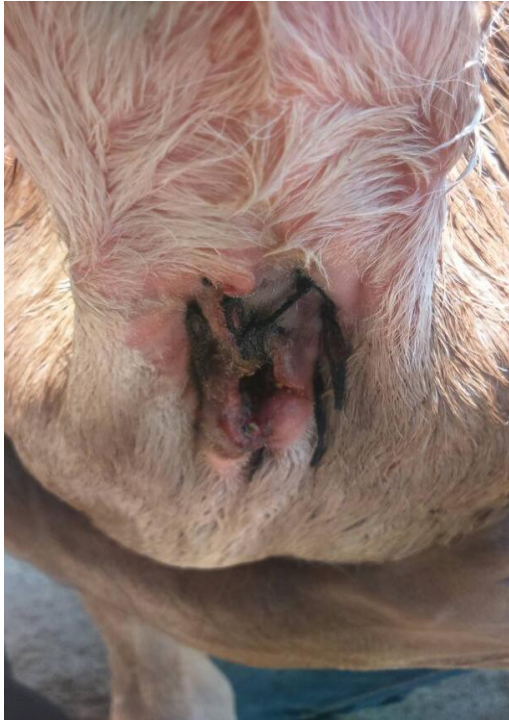


Fig 1: Photograph showing the calf with permanent anal orifice after surgery.

References

1. Bademkiran S, Icen H, Kurt D. Congenital rectovaginal fistula with atresia ani in a heifer: A case report. *Yuzuncu Yil Universitesi Veteriner Fakultesi Dergisi*. 2009; 20(1):61-64.
2. Das BR, Hashim MA. Studies of surgical affections in calves. *Bangladesh Veterinary Journal*. 1996; 30:26-33.
3. Johnson R, Ames NK, Coy C. Congenital Intestinal Atresia of Calves. *Journal of the American Veterinary Medical Association*. 1983; 182:1387-1389.
4. Kilic N, Sarierler M. Congenital Intestinal Atresia in Calves: 61 Cases (1999–2003). *Revue de Medicine Veterinaire*. 2004; 155(7):381-384.
5. Leipold HW. Neonatal Disease and Disease Management. Congenital Defects in Cattle. In: *Current Veterinary Therapy 2. Food Animal Practice*. 1986; 89-99.
6. Merei J, Batiha A, Hani IB. Renal anomalies in the Vater animals. *Journal of Pediatric Surgery*. 2001; 36(11):1693-1697.
7. Noden DM, Lahunta A. The embryology of domestic animals, developmental mechanisms and malformations, Williams & Wilkins, London. 1985; 306-315.
8. Noh DH, Jeong WI, Lee CS, Jung CY, Chung JY, Jee YH, Do SH, Ann MY, Kwon OD, Williams BH, Jeong KS. Multiple Congenital Malformations in a Holstein Calf. *Journal of Comparative Pathology*. 2003; 129(4):313-315.
9. Roberts SJ. *Veterinary obstetrics and genital diseases*. 6th Ed. Published by Ithaca, New York. 1986, 29-43.