



ISSN: 2277- 7695

TPI 2016; 5(4): 01-03

© 2015 TPI

www.thepharmajournal.com

Received: 12-02-2016

Accepted: 15-03-2016

Ruslana Denina

State Higher Educational Establishment, Department of Internal Medicine №2 and nursing "Ivano-Frankivsk National Medical University", 2, Halytska Str., 76000 Ukraine

The clinical case: Myocardial infarction and pregnancy

Ruslana Denina

Abstract

Cardiovascular diseases are still a major cause of maternal mortality in developed countries. The most common problems that complicate pregnancy are obesity, lipid metabolism, diabetes mellitus, arterial hypertension, smoking.

Myocardial infarction in pregnant woman is quite rare today. However, in recent years there has been a significant frequency increase of risk factors for cardiovascular diseases in pregnant women, increasing age of women planning pregnancy. The article presents the clinical case, namely the myocardial infarction in pregnant woman with concomitant diabetes mellitus.

Keywords: myocardial infarction, pregnancy, clinical case, diagnosis, treatment

Introduction

Cardiovascular diseases remain a major cause of maternal mortality. Among them, myocardial infarction (MI) is of special focus. There is enough evidence on the etiologic factors of MI in pregnant women, the most significant of which include age over 40 years, diabetes mellitus (DM), arterial hypertension (AH), obesity, antiphospholipid syndrome, inherited thrombophilia, as well as hypercoagulation that in combination with genetic predisposition may lead to thromboses [2, 6-8].

MI of pregnancy was first described by Katr H. (1922). In recent decades the MI incidence has increased from 3 to 10 cases per 100 thousand births [6, 8]. It was also established that the prevalence of MI among pregnant women was 5 times higher, thus increasing from 1.3 to 6.2 cases per 100 thousand women, in the period from 1991 to 2003. Myocardial infarction is most commonly confirmed either in antenatal period or during labour (59%), and less frequently in postpartum period (41%). The mortality rate due to MI constitutes 0.35 cases per 100 thousand births [3, 5].

Diagnosis of MI in pregnancy is specific, because such symptoms as chest discomfort, shortness of breath, and tachycardia may be observed even in the normal gestation course. Their cause may be associated with the use of β -adrenoceptor agonists, magnesium sulfate, and sedatives [1, 2, 10]. The increase of creatine kinase-MB fraction (CK-MB) may be present during the normal course of pregnancy. However, the increase of cardiac I and T troponins' levels is the gold standard of MI diagnosis in pregnancy [9].

MI in pregnancy is often complicated by acute heart failure – AHF (Killip I-IV, Forrester I-IV), that is one of the major causes of maternal mortality. The development of acute coronary syndrome (ACS) in pregnancy is also induced by preeclampsia, tocolytic therapy, amniotic fluid embolism, toxic shock syndrome, massive infusion therapy [2, 4].

Treatment of myocardial infarction during pregnancy includes the use of drug therapy in combination with myocardial revascularization (thrombolysis, percutaneous coronary intervention – PCI with the stenting of the infarct-related coronary artery, coronary artery bypass graft surgery).

However, it has been proved that thrombolytic therapy (TLT) in pregnant women is dangerous in terms of spontaneous miscarriages, vaginal and uterine hemorrhages, and premature separation of placenta [1, 2, 10]. According to Jamesetal (2006) preference in MI treatment of pregnant women should be given to percutaneous coronary intervention with angioplasty and stenting. Though, in some specific cases (left main coronary artery thrombosis, multivessel disease) coronary artery bypass graft surgery may be used.

Let us study the medical case of MI development in a pregnant woman. Patient D., born in 1990, internship doctor, pregnant (secundigravida, 8 weeks), was urgently hospitalized on the 28 of December 2014 to the Department of Invasive diagnostics and treatment of Central city clinical hospital in Ivano-Frankivsk. The patient complained of retrosternal squeezing and burning pain that appeared suddenly at 9⁰⁰ a.m. soon after psychoemotional stress.

Correspondence

Ruslana Denina

State Higher Educational Establishment, Department of Internal Medicine №2 and nursing "Ivano-Frankivsk National Medical University", 2, Halytska Str., 76000 Ukraine

Nitroglycerin administration turned out to be ineffective. The pain was accompanied by shortness of breath, decrease of blood pressure to 80/60 mm Hg, general weakness.

The patient applied to the time-urgent hospital, where she was examined by the therapist, and was instantly transferred to the Department of Anesthesiology with the Intensive Care Unit of the Regional clinical cardiological dispensary. Past medical history: the patient has been suffering from diabetes mellitus for 12 years, insulin-dependent, primipregnancy ended in caesarian section (2010), has been operated for cataract (implanted with intraocular lens).

Physical examination: patient's condition was severe; the skin was pale, wet and cold (Forrester-III-IV). AT 80/60 mm Hg, suppressed vesicular breathing was heard in the lungs, with moist small bubbling rales in lower parts; impaired heart tones, heart rate – 110 bpm, regular rhythm (Killip IIA class). The ECG showed – sinus rhythm, regular, elevation (3-4 mm) of ST segment in I, II, aVL, V₁-V₃- leads, reciprocating changes (ST-segment depression) in II, III aVF, V₆ - leads.

The level of cardiac troponin I was 2.14 ng/mL (December 28, 2014 at 10³⁰a.m.).

Taking into consideration the characteristic pain syndrome, ST-segment elevation showed by ECG, the increase of cardiac troponin I level, dyskinesia of anterior, anterior-septal segments of basal and middle parts of the left ventricle (as evidenced by transthoracic EchoCG), duration of the interval «primary medical contact-to-device time» 90 min (I A level of evidence) – the decision of urgent coronarography and percutaneous coronary intervention was made. At 10³⁰ a.m. (having obtained the written informed consent for PCI) coronarography was performed: it showed the right type of cardiac blood supply; the right coronary artery (RCA) and left circumflex coronary artery (LCCA) were without hemodynamically relevant constrictions (TIMI-3); 100% occlusion was observed on the edge of proximal and medial segment of the anterior interventricular branch of left coronary artery (AIVB LCA) – TIMI-0 (Figure 1).

The patient was performed urgent AIVB LCA stenting with BMS Integrity 3.5x26.0 mm stent system, TIMI-3 (Figure 2).

The absorbed radiation dose made up ED- 496.53mGy, current fetal exposure – 99.306 mGy, 19.9 rad.

After the PCI chest pain has completely ceased; by means of ECG examination the ST-segment resolution was defined as 80%. The patient's general condition was satisfactory with regular pulse of 96 bpm, clear heart tones and respiratory rate of 17/min.

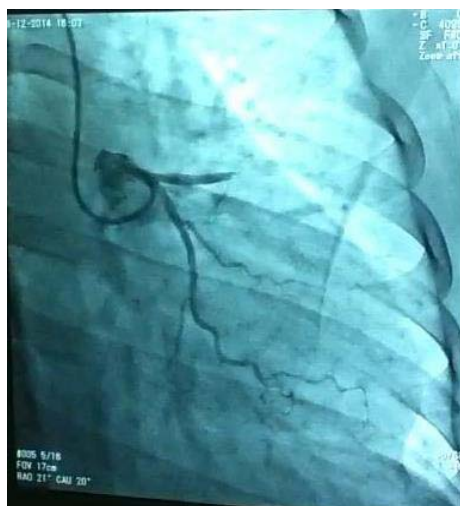

Fig 1: Coronarography of the patient D. before stenting.

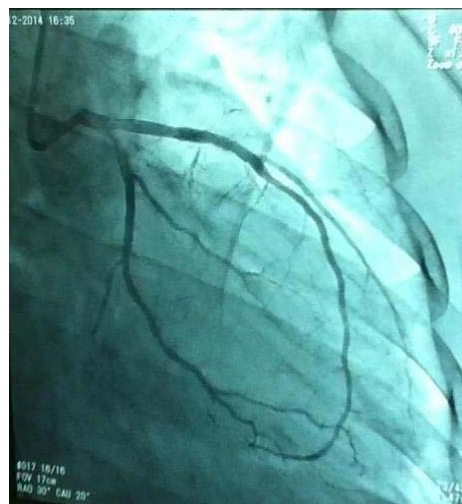


Fig 2: Coronarography of the patient D. after PCI.

Diagnostic findings: Complete blood count (December 28, 2014): WBC –13.5-10⁹/L; ESR –10 mm/hour; band neutrophils – 5%; segmented neutrophils – 69%; lymphocytes– 22%; monocytes – 4%. Clinical conclusion: signs of resorption-necrotic syndrome.

Biochemical blood assay (December 28, 2014): protein – 58 g/L; urea – 3.1 mmol/L; creatinine – 57.8 mmol /hour; glucose– 8.4 mmol/L; K⁺– 4.16 mmol/L; Na⁺– 142.3 mmol/L; Ca²⁺– 1.01 mmol/L; CL–107.5 mmol/L. Clinical conclusion: moderate hypoproteinemia, hyperglycemia.

Coagulogram (December 28, 2014): international normalized ratio (INR) = 2.44 units; prothrombin ratio – 53.7%; fibrinogen – 1.54 g/L; aPTT – 270 seconds; hematocrit – 0.39 units. Clinical conclusion: hypocoagulation.

Lipid panel (December 28, 2014): total cholesterol (TC) – 5.0 mmol/L; triglycerides (TG) – 1.54 mmol/L; low-density lipoproteins (LDL) – 3.17 mmol/L; high-density lipoproteins (HDL) – 1.13 mmol/L; very low-density lipoproteins (VLDL)– 0.7 mmol/L; atherogenic index = 3.42 units. Clinical conclusion: IIA type dyslipidemia by Frederixon.

Glycemic profile (blood glucose levels) = 6.4–9.9–4.8 mmol/L.

Common urine test (December 29, 2014): light yellow, clear, urine specific gravity – 1027; pH – 5.0; protein – 0.13 g/L; glucose – 2.0%; red blood cells – 1-2 per field of view; white blood cells – 10-15 per field of view; oxalates – in small amounts.

ECG (90 minutes after PCI): ST-segment resolution – 80%.

Echocardiogram: ejection fraction (EF) – 45%; dyskinesia of anterior, anterior-septal segments of basal and middle parts of the left ventricle [paradoxical enlargement (bulging) of the circumscribed portion of the myocardium during systole].

Ultrasound investigation of the uterus: gestational sac of 37 mm in diameter is visualized in the uterine cavity; fetus –11 mm, heartbeat remained constant; pregnancy – 7-8 weeks.

Diagnosis: Ischemic heart disease, acute myocardial infarction with ST-segment elevation (AMIEST), localized in anterior and anterior-septal segments of basal and middle parts of the left ventricle, complicated by acute left-ventricular heart failure – Killip IIA class, Forrester IV (December 28, 2014, 9⁰⁰a.m.). Urgent coronarography: 100% occlusion on the edge of proximal and medial segments of the anterior interventricular branch of left coronary artery (AIVB LCA), TIMI-0. Urgent stenting of the AIVB LCA, TIMI -3 (December 28, 2014).

Type I diabetes mellitus, sub compensated, insulin dependent.
Secundigravida, 7- 8 weeks.

Patient D. was prescribed the following treatment after stenting:

- diabetic diet;
- antiplatelet agents (aspirin – 75 mg/day, ticagrelor/brilinta), anticoagulants (enoxaparin in the dose of 1mg/kg twice daily during the first 4 days changing over to rivaroxaban in the dose of 2.5 mg twice daily);
- anti-ischemic agents (selective β -adrenoblocker bisoprolol – 1.25 mg/day); trimetazidine –140 mg/day for the first 3 days, and then – 70 mg/day;
- Omacor (omega -3- PUFAs) – 1 g/day.
- Insulin therapy (according to the recommendations of endocrinologist).

Patient D. was performed caesarian section on the 14 of July 2015 at 9⁴⁰ a.m. and thus delivered a full-term female-infant with the body weight of 3620 g, and 53 cm long. The newborn's condition was evaluated with a score of 7.7 by Apgar scale.

Conclusions: Myocardial infarction of pregnancy with the concomitant diabetes mellitus is a topical problem as it is a potentially dangerous comorbid condition for the pregnant woman and future mother, as well as newborn baby. MI diagnostics in pregnant women must be based on the evaluation of pain syndrome (typical, atypical, nonanginal), changes in ECG (ST-segment elevation over 2 mm and in at least two neighboring chest leads or newly occurred left His bundle-branch block), cardiac troponins' levels (I, T), echocardiogram (zones of hypo-, akinesia, dyskinesia).

References

1. Bowater SE, Thorne SA. Management of pregnancy in women with acquired and congenital heart disease. *Postgrad Med J.* 2010; 86:100-105.
2. Regitz-Zagrosek V, Blomstrom Lundqvist C, Borghi C. ESC Guidelines on the management of cardiovascular diseases during pregnancy: the Task Force on the Management of Cardiovascular Diseases during Pregnancy of the European Society of Cardiology. *Eur. Heart J.* 2011; 32:3147-3197.
3. James AH, Jamison MG, Biswas MS. Acute myocardial infarction in pregnancy: a United States population-based study. *Circulation.* 2006; 113(12):1564-1571.
4. Ladner H, Danielsen B, Gilbert W. Acute myocardial infarction in pregnancy and the puerperium: a population based study. *Obstet Gynecol.* 2005; 105(3):480-84.
5. Janion- Sadowska A, Sadowski M, Kurzawski J. Pregnancy after acute coronary syndrome: a proposal for patients' management and a literature review. *BioMed Res. Intern.* 2013, 1-7.
6. Roos-Hesselink JW, Duvekot JJ, Thorne SA. Pregnancy in high risk cardiac conditions. *Heart.* 2009; 95:680-686.
7. Roth A, Elkayam U. Acute myocardial infarction associated with pregnancy. *J Amer Coll Cardiol.* 2008; 52:171-180.
8. Sciscione AT, Ivester T. Acute Pulmonary Edema in Pregnancy. *Obstetrics & Gynecology.* 2003; 101:511-15.
9. Shivers S, Wians S, Keffer H. Maternal cardiac troponin I levels during normal labor and delivery. *Am J Obstet Gynecol.* 1999; 180:122-27.
10. Bates SM, Greer IA, Middeldorp S. VTE, thrombophilia,

antithrombotic therapy, and pregnancy: antithrombotic therapy and prevention of thrombosis, 9th ed. American College of Chest Physicians EvidenceBased Clinical Practice Guidelines. *Chest* 2012; 141:691-736.