



ISSN: 2277- 7695

TPI 2016; 5(12): 26-28

© 2016 TPI

www.thepharmajournal.com

Received: 07-10-2016

Accepted: 08-11-2016

Zaharko VPDanylo Halytsky Lviv Medical
University, Ukraine**Nakonechnyy AY**Danylo Halytsky Lviv Medical
University, Ukraine**Fedus VR**Danylo Halytsky Lviv Medical
University, Ukraine

The significance of qualitative compressive elastography in boys with hernia inguinale

Zaharko VP, Nakonechnyy AY and Fedus VR

Abstract

Qualitative compressive elastography (QCE) is a newly developed method which can obtain the stiffness of tissues and organs. Several studies have demonstrated its potential in the differentiation between diseased and normal tissue in clinical practices, however the applicability to hernia inguinale and testicular disease has not been well elucidated. We investigated the feasibility and reproducibility of qualitative elastography in the detection of the influence of hernia inguinale and its surgical treatment on the structure-functional state of testis.

Keywords: Hernia inguinale, testis, qualitative compressive elastography

1. Introduction

Hernia inguinale in children (HI) is a frequent disease. This pathology is more common in boys 78-96% [1, 7]. There are intraoperative and early postoperative complications of traditional method of surgical treatment: swelling of the testicles and scrotum, ischemic orchitis and testicular atrophy. We used clinical significance of the testicular tissue elasticity measured by qualitative compressive elastography as a predictor of testicular ischemia and atrophy [5, 6, 10]. We are not aware of the usefulness of (QCE) for the diagnosis of ischemic orchitis and testicular atrophy. We report the (QCE) features in a case report and discuss the role of this diagnostic modality in the differential diagnosis of postoperative complications. Elastography is a modern noninvasive diagnostic method, which reflects the stiffness of healthy tissue and the damaged area of a particular organ. The real-time display allows you to quickly assess the degree of tissue damage and to confirm a preliminary diagnosis of ischemia, atrophy, fibrosis. Spatial resolution compression elastography, = 1 mm, depends on a number of factors, including the duration and frequency of the ultrasonic pulse and the size of the plots of comparison. Elastogram, which reflects the relative elasticity of the tissues, was created as a color map, where tissues with a higher hardness are depicted in red and tissues with less rigidity are blue. Lighter shades of the base color to reflect different degrees of deformation and correlated with the dynamic range of the analytical system. Some types of ultrasound settings allow you to generate a picture in one color with fabric with less rigidity is encoded in a lighter color, and with high rigidity – in a dark color. Compression elastography has historically been used for the differentiation of benign and malignant tumors of the prostate, testis, thyroid, breast, liver [2-4, 8, 9]. Regardless of the type of apparatus, the elasticity may change depending on the type of tissue which is examined plots of the comparison and applied pressure. Ultrasonic elastography was firstly proposed by Ophir *et al* [9], which has abstracted more attention by clinicians in recent years and developed rapidly. Elastography enables differentiation of tissues on the basis of their stiffness [2-4, 9]. This adds a new choice of detecting any pathologic abnormality that could otherwise be missed by conventional ultrasound. Kantarci successfully used elastography to identify segmental infarction of the testis, ischemia of the testicular tissue and testicular torsion [6]. Itoh *et al.* have proposed a scale from 1 to 5, depending on the degree of deformation. 1 indicates that the entire lesion elastic (deforms), 2 – most of the lesion elastic, less rigid, 3 – elastic lesion at the periphery with a rigid center 4 – that all the hard tumors, 5 tumor and surrounding tissue hard. If the damage is estimated between 1-3 is favorable (benign) for, if elastogram estimated 4-5, this corresponds to the atrophic process or a malignant process [4]. During the multicenter Italian study, it was proposed another classification, which characterizes how dense (solid) and cystic neoplasms. This system also has 5 levels, 1 type three – layer structure (blue, green and red colors on electrogram), typical of the cysts, type 2 is mostly elastic tumors, type 3 lesion with multiple zones of hardness, type 4 – a large part of tumors is not deformed, dense, 5 type –

Correspondence**Zaharko VP**Danylo Halytsky Lviv Medical
University, Ukraine

dense lesion with a rigid degeneration of the surrounding tissues, which are visualized in blue on elastogram [3].

2. Materials and Methods

On the base of the Surgery Department of Lviv City Community Children’s Hospital the 98 boys with inguinal hernias, aged from 6 months to 12 years were operated for the period 2013 - 2016 gg. The 30 were children operated by laparoscopic technique by PIRS (Percutaneous Internal Ring Suturing) and 68 boys – operated by the traditional method by Duhamel. By type conducted surgery patients were divided into subgroups: A - operated by laparoscopic (n = 30), B -by the traditional method (n = 68). High-quality compression method of elastography conducted by us on the ultrasound machine, Samsung Medison Co., LTD., The Republic of Korea before surgery, on the 7th, 14th, 30th postoperative day. On the basis of the obtained data was determined with further tactics of conservative treatment. All patients were examined by the method of qualitative compressive elastography. It was conducted on the ultrasound machine Samsung Medison Co., LTD., The Republic of Korea, on 7, 14, 30 days and 6 months after surgery. We researched the elasticity of the testicular tissue and determine the type of elastogram at the beginning and in dynamics of postoperative observations, depending on the type of surgical intervention.

2. Case report

Child, S., 24.04.2012 A.(3 years 7 months) enrolled in the surgical Department of Lviv City Community Children’s Hospital 16.11.2015 with a diagnosis of Right inguinal hernia. Conducted compression quality elastography before surgery (Fig.1). Herniotomy was performed according to the method of Duhamel I. On the 14th postoperative day testing and revealed: the right testicle is typical. The contours of his clear, smooth. Size 17mm x 8mm x 10 mm. a Volume of 0.7 ml. the Structure is homogeneous, fine-grained. The echogenicity of the normal testis. Elastogram type II (non-standard). Determined by the swelling of the wall of the scrotum to 7 mm. Mediastinum without features. Appendage: size within normal limits. The contours of his clear, smooth. Not structurally changed. Purse the usual amount of free fluid. The veins of the spermatic cord: is not extended. Left testicle is typical. The contours of his clear, smooth. Size 17 mm x 8 mm x 9.3 mm. with a Volume of 0.6 ml. The echogenicity of the normal testis. Elastogram type I (normal). Mediastinum without features. Appendage: size within normal limits. The contours of his clear, smooth. Not structurally changed. Purse the usual amount of free fluid. The veins of the spermatic cord: is not extended. The width of the inguinal canal to 7 mm.

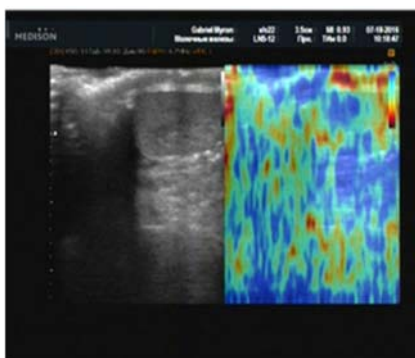


Fig 1: Child, S., 3 years 7 months with a diagnosis: inguinal hernia in right side. Elastogram of the right testis before surgical treatment,

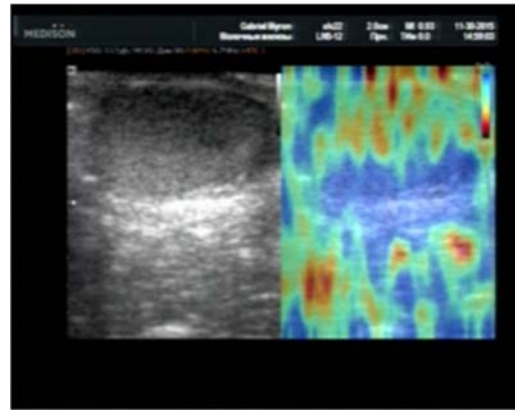


Fig 2: Child, S., 3 years 7 months with a diagnosis: inguinal hernia in right side. Elastogram of the right testis on the 14th postoperative day after traditional surgical treatment.

Elastogram (Fig.2) with the advantage of tissue with high elasticity, which indicates a swelling of an inflammatory nature. If there is inflammation, it increases the flexibility due to the presence of exudation. For the recovery of elastogram acquires mosaic nature of the formed layer, the zone of low elasticity along the back wall, indicating a positive trend: a reduction of the inflammatory process and swelling of the testicular tissue. This case is demonstrated how elastography enables the assessment of the dynamics of transient edema of the scrotum and testicles to determine the need and effectiveness of conservative treatment of early postoperative complications in boys operated by the traditional method. This child must get antismelling therapy and consultation of urology.

On the basis of the study we created a rating scale elasticity of the testicular tissue.

Elastogram type I: high elasticity approaching uniformity, no mosaic.

Elastogram type II: medium elasticity approaching high formation of patchiness.

Elastogram type III: advantage of tissue with an average elasticity approaching low and severe mosaic.

Elastogram type IV: low and medium elasticity as you get closer to uniformity, low mosaicity.

Elastogram type V: low elasticity, the mosaicity is absent.

3. Conclusions

1. Compression elastography is useful in the assessment of tissue density due to the fact that the image is reproduced in real time, which allows immediately to interpret the data obtained for the availability of adequate diagnostic criteria. The cost of this study is not high enough, which led to broad use of it in clinical practice.
2. Elastography-a convenient, easy in use, available method that can serve as an additional tool for the diagnosis and monitoring of the dynamics or the progression of the ischemic testes in addition to ultrasound with Doppler effect. Further developments in the field of QCE elastography technology, as well as prospective studies with blinded examiners and adequate statistical power will probably establish more clearly the clinical impact of dynamic elasticity imaging, and just how pressed we will be to adopt elastography as a standard adjunct to QCE will undoubtedly depend upon the firmness of future elastography technology, as well as prospective studies with blinded examiners and adequate statistical power will probably establish more clearly the clinical impact of

dynamic elasticity imaging, and just how pressed we will be to adopt elastography as a standard adjunct to QCE will undoubtedly depend upon the firmness of future data.

3. Elastography enables noninvasive visualization of the condition of the tissues of the testis in nonoperated patients with inguinal hernias and track the dynamics of tissue changes in early and late postoperative periods, to detect risk in relation to fibrosis testicle for carrying out medical treatment.

4. References

1. Fettle A, Hollwarth M. Surg. Childh. Int. 2000; 4:273-277.
2. Gao L, Parker KJ, Lerner RM, Levinson SF. Imaging of the elastic properties of tissue: a review. Ultrasound Med Biol. 1996; 22:959-977.
3. Garra BS. Imaging and estimation of tissue elasticity by ultrasound. Ultrasound Q. 2007; 23:255-268.
4. Itoh A, Ueno E, Tohno E, Kamma H, Takahashi H, Shiina T *et al.* Clinical application of US elastography for diagnosis. Radiology. 2006; 239:341-350.
5. Kadish HA, Bolte RG. A retrospective review of pediatric patients with epididymitis, testicular torsion, and torsion of testicular appendages. Pediatrics. 1998; 102:73-76.
6. Kantarci F, Cebi Olgun D, Mihmanli I. Shear-wave elastography of segmental infarction of the testis. Korean J Radiol. 2012; 13:820-822.
7. Marulaian M, Atkinson J, Kukkady A *et al.* // J. Pediatr. Surg. 2008; V.41(11):2004-2007.
8. Nordez A, Hug F. Muscle shear elastic modulus measured using supersonic shear imaging is highly related to muscle activity level. J Appl Physiol. 2010; 108:1389-1394.
9. Ophir J, Alam SK, Garra BS. Elastography: imaging the elastic properties of soft tissues with ultrasound. J Med Ultrasonics. 2002; 29:155-171.
10. Xiao YK, Wen GC. The advance of diagnosis and treatment in testicular torsion. Journal of Dali University. 2013; 12:53-55.