



ISSN: 2277- 7695

TPI 2015; 3(11): 43-46

© 2015 TPI

www.thepharmajournal.com

Received: 05-11-2014

Accepted: 15-12-2014

Lembryk I.S.

SHEI "Ivano-Frankivsk
National Medical University"
Ukraine.

Clinical "Masks" of helminthiases and parasitic invasion in children with pathology of digestive tract

Lembryk I.S.

Abstract

In the article peculiarities of the most common helminthiasis (giardiasis, ascariidosis, trichuriasis) in 50 school-aged children with chronic gastroduodenitis, cholecystitis and sphincter of Oddi dysfunction, pancreatic type, are described. It was estimated that diseases at the basis of helminth invasions have more severe course and significantly worsens quality of life of the sick child.

Keywords: Children, clinic, gastroenterological pathology, helminthiasis.

1. Introduction

By the data of the Committee on parasitosis of WHO, the third place in the structure of infectious morbidity takes intestinal helminthiasis [1, 2, 3, 5, 6]. Approximately one third of the tellurians are infected with parasites and helminths and over 100 millions of children in the world in the result of this infection suffer from the arrest of physical and mental development [5, 6, 9, 10, 12].

Usually, a helminth takes an effect upon a host in different ways. First of all, it is a mechanical (trauma and damage of tissues in case of attachment of helminths and migration of larvae, break, obstruction, squeeze); toxic (poisoning of an organism with waste products and a helminth destruction); metabolic and immunosuppressive influences. The latter consists in nervous system depression with further development of secondary immunodeficiency (decrease of T-helper cells level, disorder of immunoregulatory index – correlation of T-helper cells and regulatory T cells). Formation of chronic allergic process takes place that, therefore, provides favorable conditions for a parasite survival [7, 9, 10, 11, 12].

The actuality of the issue emphasizes also the fact that helminthiases "wear" the so-called "clinical masks" very often and become similar by their course to other somatic and, first of all, gastroenterological diseases which considerably complicates diagnostics especially on early stages [1, 3, 6, 7, 12].

2. Material and methods of diagnostics

We have examined 50 children aged from 7 to 15 years that received hospital treatment at OCCCH in the city of Ivano-Frankivsk. In the structure of gastroenterological pathology in the examined by us patients prevailed chronic cholecystitis (60.0%), chronic gastroduodenitis (20.0%) and sphincter of Oddi's dysfunction, pancreatic type (20.0%). A diagnosis of an underlying disease was verified in accordance with modern protocols of diagnostics and treatment. A diagnosis of helminth invasion (giardiasis, trichocephalosis) was proved by anamnestic data as well as detection of vegetative forms of protozoal infection or helminth eggs in native faeces during 5 days of examination. Faeces sampling for examination was made three times from 5 different places. One third of the patients with ascariidosis additionally underwent radiography of chest organs in frontal view with the presence of relative clinical symptoms.

3. Results of examination and their discussion

Clinical symptoms of helminthiases are known to be nonspecific, still there were established some peculiarities of their course on the background of an underlying pathology (fig.1).

As it can be seen from the provided data, children with chronic cholecystitis in combination with giardiasis more often have colicky abdominal pains without clear localization, ptyalism, more rarely – nausea and absence of appetite. In patients with chronic gastroduodenitis dyspeptic phenomena (nausea, absence of appetite, ptyalism) come to the front. Rashes on skin

Correspondence:

Lembryk I.S.

SHEI "Ivano-Frankivsk
National Medical University"
Ukraine.

can be found more rarely. At sphincter of Oddi's dysfunction, pancreatic type, in combination with giardiasis there can be observed domination of a stomachache often not connected with having any meal as well as the dyspeptic phenomena.

Clinical picture of ascariasis at diseases of upper part of a digestive tract is conditioned by a process phases. Yes, in the early phase induced by migration of ascarid larvae we observed the following clinical symptoms (fig. 2).

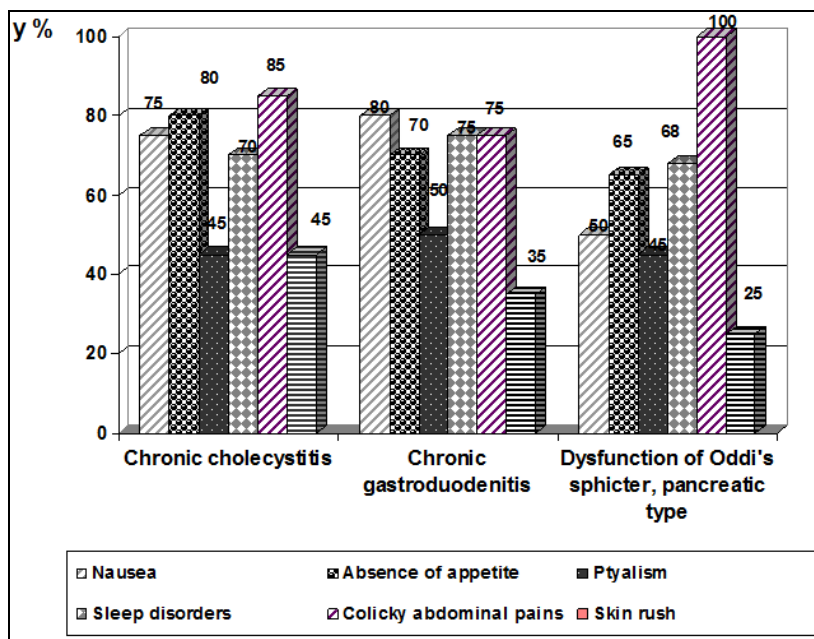


Fig 1: Peculiarities of the clinical picture of giardiasis on the background of gastroenterologic pathology.

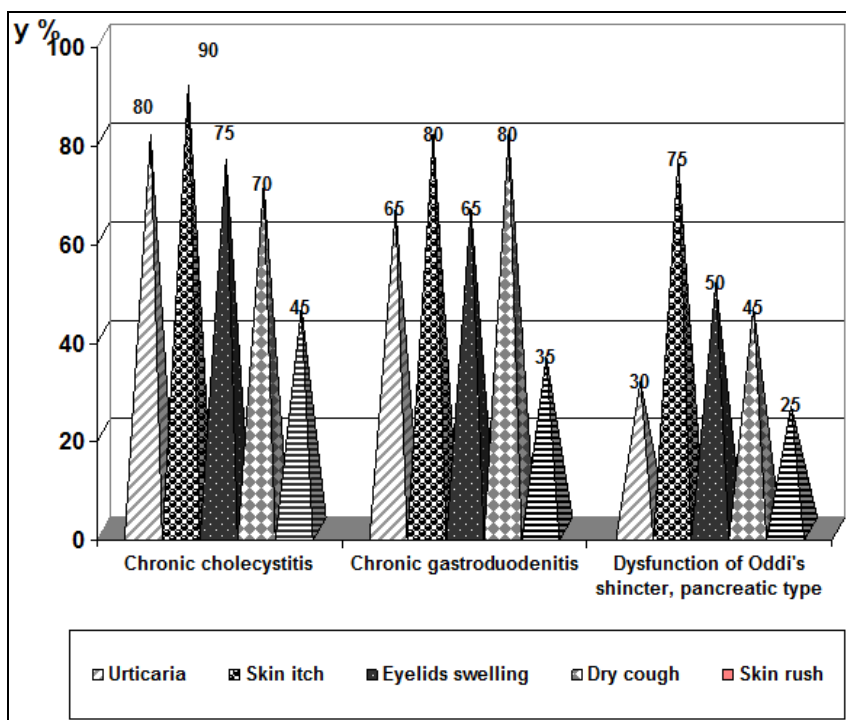


Fig 2: Peculiarities of the clinical picture of ascariasis (early phase) on the background of gastroenterologic pathology.

Results of the above examinations certify the domination of a skin-allergic component at ascariasis in combination with lesion of upper parts of a digestive tract as well as the presence of a dry cough, sometimes with asthmatic component especially noticeable at chronic cholecystitis.

In the late phase of ascariasis, which already had a chronic character, the leading place takes the dyspeptic syndrome that dominates at all diseases in the examined by us children (fig.3).

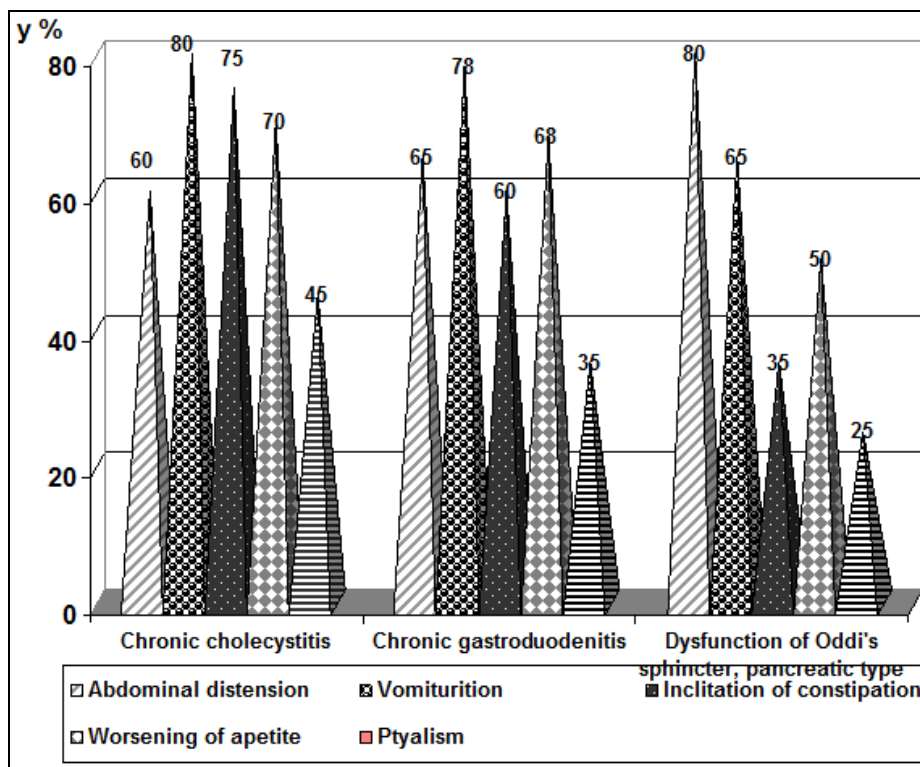


Fig 3: Peculiarities of the clinical picture of ascaridiasis (late intestinal phase) on the background of gastroenterologic pathology.

As it can be seen from the above data, the abdominal distension dominated only in patients with reactive pancreatitis. Vomiturition, which often is accompanied by a bitter or sour eructation, is observed more often in patients with chronic gastroduodenitis and cholecystitis. Certain age-related peculiarities of the course of ascaridiasis on the background of gastroenterologic pathology were established.

In the clinical picture of ascaridiasis of 7-9-year-old patients dominated abdominal distension, food vomiting, and inclination to constipations. Quite often children had complaints about abdominal pain with localization in a perumbilical area (68.0%). Especially it was peculiar to the patients with chronic cholecystitis and sphincter of Oddi dysfunction, pancreatic type. Unlike patients of primary school age, teenagers with ascaridiasis on the late stage of development of a pathologic process could accurately detect localization and intensity of symptoms. Yes, the most frequent were: distortion of an appetite (decrease as well as increase) (70.0 %), more rarely – ptyalism (68.0%), alternation of diarrhea and constipation (50.0%).

During examining of children with pathology of upper part of a digestive tract in combination with helminthiases the attention was paid to the state of skin and its derivatives. In particular, for girardiases rather characteristic were the following: dryness of skin on bends of the arm and the knee (80.0%), presence of grey-blue tint of the nasolabial triangle (70.0%), swelling of eyelids without visible causal relationship to allergic factors (65.0%), skin itch (45.0 %).

At this children complained about bad general state, melancholic mood, general fatigability (90.0%).

General condition of patients with ascaridiasis was little disturbed, however in one third of the cases, except cough, it was observed pain in chest and body temperature rise to subfebrile figures (37-38 °C). In this group of patients the helminth intermediaries, antihistamines and sorbates, it was prescribed a diet with low content of fats, the cultured milk

attention is drawn to more noticeable skin lesions: except the mentioned urticarial, it was observed the mottled palms (50.0%), sweating of the hairy part of a head (30.0%).

There were observed signs of vegetative dysbalance almost in all patients of this group in the first phase of ascaridiasis development: palms hyperhidrosis (90.0 %), giddiness (78. %), disorders of basic sleep phases (70.0%), disorder of the heart rhythm of functional character (60.0 %).

In the late intestinal phase the patients (mostly with chronic gastroduodenitis and sphincter of Oddi dysfunction, pancreatic type) observed the decrease of mental and physical activity, a headache, irritability (98.5%). Arrest of physical development was stated in 5.0% of patients of 7-9 years old with chronic cholecystitis and gastroduodenitis.

In children with trichocephaliasis on the background of gastroenterological diseases there were observed the following clinical symptoms (Fig. 3).

The results of the researches showed more severe course of trichocephaliasis on the background of the underlying pathology, in particular in children with chronic gastroduodenitis and sphincter of Oddi dysfunction, pancreatic type. Except intensive pain syndrome in the zone of epigastrium and/or along intestine duct that is accompanied by emptying disorders, thick sweating, general weakness, the following dyspeptic phenomena took place – nausea and food vomiting with additions of bile and blood as well as sharp paleness of cutaneous covering and visible mucous membranes. In this group of patients the asthenic syndrome was more significant as well as vegetative disorders, more often the disorders of basic sleep phases could be observed.

The diagnosis of ascaridiasis at the early stage was confirmed also by the presence of “light” eosinophylic infiltrations in pulmonary parenchyma [2, 3, 5, 9, 12].

Treatment of helminth invasions is conducted in three stages according to a standard scheme [4, 7, 10]. Except specific anti-foods. The effectiveness of the therapy we assessed in 2-3 weeks. If necessary, the treatment course was repeated.

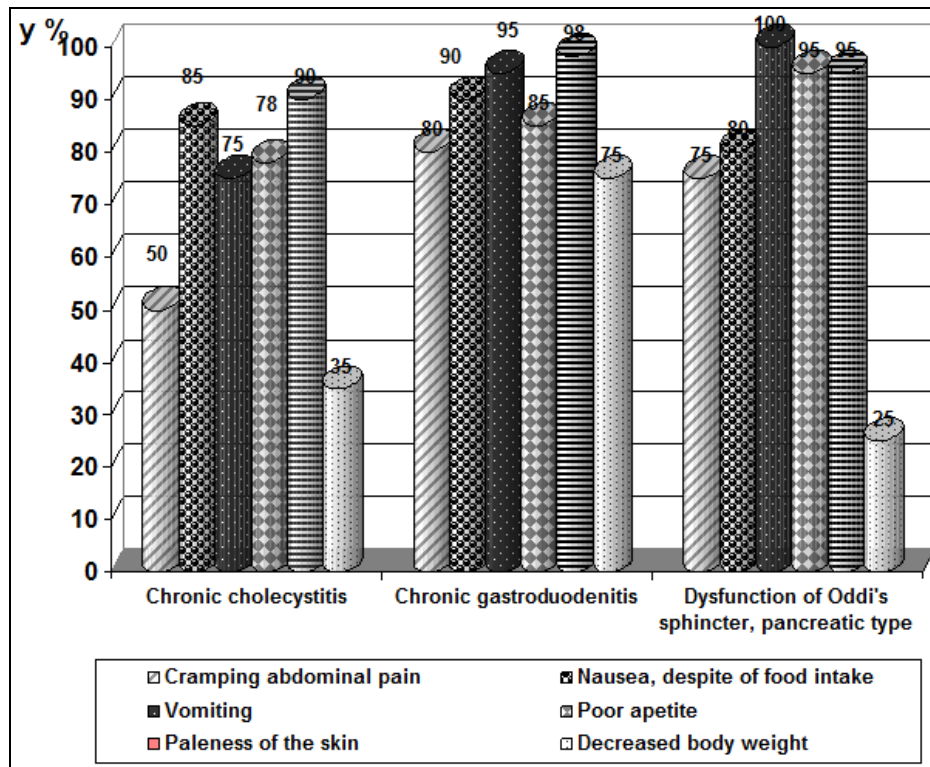


Fig 4: Peculiarities of the clinical picture of trichocephaliasis on the background of gastroenterologic pathology.

4. Conclusion

Therefore, we can make a conclusion that helminthiasis in childhood age on the background of pathology of a digestive tract can have gastrointestinal, dermatological and vegetative “masks” that impel to search new approved methods of diagnostics on early stages, involvement of a wide circle of specialists and, maybe, even an examination of such patients in specialized centers.

5. References

- Maidannyk VG. Ascariasis in children. Health of Ukraine, 2012, 14-16.
- Marushko Yu.V, Grachova MG. Helminthiasis in children: the problem condition, peculiarities of diagnostics and therapy. Modern pediatrics 2011; 6(40):58-62.
- AAP. Hookworm infections. In: Red Book 2009: Report of the Committee on Infectious Diseases. Edn 28, American Academy of Pediatrics, 2009, 375-6.
- Vercruysse MJ, Jerzy MB, Albonico M, Shaali MA, Angebault C, Bethony JM *et al.* Assessment of the anthelmintic efficacy of albendazole in school children in seven countries where soil-transmitted helminths are endemic. PLoS Negl Trop Dis 2011; 5(3):948.
- Brooker S, Bundy DAP. Soil-transmitted Helminths (Geohelminths). In: Cook GC, Zumla AI, eds. *Manson's Tropical Diseases*. 22nd ed. Philadelphia, PA: WB Saunders, 2009, 1515-48.
- Centers for Disease Control and Prevention. Hookworm. CDC DPDx: Laboratory Identification of Parasites of Public Health Concern. Available at <http://www.dpd.cdc.gov/DPDx/HTML/Hookworm.htm>. Accessed April 22, 2012.
- Kathrin Ziegelbauer, Benjamin Speich, Daniel Mäusezahl, Robert Bos, Jennifer Keiser, Jürg Utzinger. Effect of

- sanitation on soil-transmitted helminth infection: systematic review and meta-analysis. PLoS Med 2012; 9(1):1001-162.
- Hotez PJ, Bethony J, Bottazzi ME *et al.* Hookworm: "the great infection of mankind". PLoS Med 2005; 2(3):67.
- Quinnell RJ, Bethony J, Pritchard DI. The immunoepidemiology of human hookworm infection. Parasite Immunol 2004; 26(11-12):443-54.
- Soukhathammavong PA, Sayasone S, Phongluxa K *et al.* Low efficacy of single-dose albendazole and mebendazole against hookworm and effect on concomitant helminth infection in Lao PDR. PLoS Negl Trop Dis 2012; 6(1):1417.
- Bethony J, Brooker S, Albonico M *et al.* Soil-transmitted helminth infections: ascariasis, trichuriasis, and hookworm. Lancet 2006; 367(9521): 1521-32.
- World Health Organization. Parasitic Diseases. WHO. Available at http://www.who.int/vaccine_research/diseases/soa_parasitic/en/index2.html. Accessed April 22, 2012.