

THE PHARMA INNOVATION - JOURNAL

Chemoprotective effect of ethanolic extract of *Morinda citrifolia* against Cisplatin induced nephrotoxicity

Seshachary Anusha Karamcheti ^{1*}, D. Satyavati ², N.Siva Subramanian ³, Pradeep H.A ⁴, C. Pradeep kumar ⁵, G.Deepika Sri Prashanthi ⁶

1. Department of Pharmacology, Teegala Krishna Reddy College of Pharmacy, Medbowli, Meerpet, Saroornagar, Hyderabad, Andhra Pradesh, India- 500097.
[Email: karamchetianusha@gmail.com, Tel: +91-9000072194]
2. Principal, Senior Professor, Department of Pharmacology, Sree Dattha Institute of Pharmacy, Sheriguda, Ibrahimpatnam, Ranga Reddy, Andhra Pradesh, India.
[Email: satyavati.dhulipala@gmail.com, Tel: +91-9966430580]
3. Principal, Senior Professor, Department of Chemistry, Teegala Krishna Reddy College of Pharmacy, Medbowli, Meerpet, Saroornagar, Hyderabad, Andhra Pradesh, India..
[Email: thambisiva@yahoo.com]
4. Department of Pharmacology, NISHKA Labs, Uppal, Hyderabad, A.P, India
5. Assistant Professor, Department of pharmacology, Teegala Krishna Reddy College of Pharmacy, Medbowli, Meerpet, Saroornagar, Hyderabad, Andhra Pradesh, India.
[Email: pharmacologypradeep@gmail.com, Tel: +91-9493515797]
6. Department of Pharmacology, Teegala Krishna Reddy College of Pharmacy, Medbowli, Meerpet, Saroornagar, Hyderabad, Andhra Pradesh, India.
[Email: deepika.gundrathi@gmail.com].

The present study was aimed to evaluate the ethanolic extract of *Morinda citrifolia* (EEMC) fruits for chemoprotective effect in Cisplatin-induced nephrotoxicity in rats. Nephrotoxicity was induced in Wistar rats by intraperitoneal administration of Cisplatin 5 mg/kg. Effect of concurrent administration of ethanolic extract of *Morinda citrifolia* fruits at dose of 100 and 200 mg/kg b.w. were given for respective animal groups by oral route was determined using serum creatinine, serum protein and serum urea as indicators of kidney damage. Both the doses produced significant ($P<0.01$) protective activity in Cisplatin induced nephrotoxicity models as evident by decrease in serum creatinine, serum urea, serum protein in extract treated groups which was elevated by Cisplatin, which was further confirmed by histopathological study. Cisplatin induced glomerular atrophy, infiltration of cells and tubular congestion of the kidney cells were found to be reduced in the groups receiving EEMC along with cisplatin.

Keyword: Chemoprotective, *Morinda citrifolia*, Cisplatin.

1. Introduction

Nephrotoxicity is one of the most common kidney problems and occurs when body is exposed to a drug or toxin. When kidney damage occurs, body unable to rid of excess urine and wastes from the body and blood electrolytes will

all become elevated. A number of therapeutic agents can adversely affect the kidney resulting in acute renal failure, chronic interstitial nephritis and nephritic syndrome because increasing number of potent therapeutic drugs like aminoglycoside antibiotics, chemotherapeutic

agents and NSAIDS. *Morinda citrifolia* (Family: Rubiaceae) is a bush or small tree, 3–10 m tall, with abundant wide elliptical leaves 5–17 cm length, 10–40 cm width. It has many biological activities like anti-microbial, anti-cancer, anti-oxidant, anti-inflammatory, analgesic, cardiovascular, anthelmintic, hepatoprotective, anti-obesity, hypoglycemic, anxiolytic, wound healing, hypotensive, estrogenic, immunological activities. The present study was carried out to determine the chemoprotective effect of ethanolic extract of *Morinda citrifolia* against cisplatin induced nephrotoxicity.

2. Material and Methods

2.1. Collection and extraction of plant material

The fruits of *Morinda citrifolia* were collected from Thuthukudu District, Tamil Nadu, India and authenticated by botanist V. Chelladuri. The fruits of *Morinda citrifolia* were dried under shade and then powdered with a mechanical grinder and stored in an airtight container for further use. The coarse powder was extracted with ethyl alcohol by using Soxhlet apparatus. The solvent was evaporated to dryness and the dried crude extract was stored in air tight bottle.

2.2. Phytochemical screening

The phytochemical constituents present in the ethanolic extract of *Morinda citrifolia* fruits are steroids, glycosides, phenols, tannins, terpenoids, alkaloids, carbohydrates, flavonoids, reducing sugars, proteins, lipids and fats, acidic compounds.

2.3. Animals

Healthy male Wistar Albino Rats weighing between 150–200 gm were taken for the study from Nishka Scientific and Reference Laboratories, Uppal, Hyderabad. They were housed under controlled conditions of temperature (23 ± 2 °C), humidity ($55\pm 5\%$) and 12 hrs light and 12 hrs dark cycles. The animals were fed with standard pellet diet and water. Food intake was monitored daily. The rats were maintained as per the Indian guidelines (National Institute of Nutrition, Hyderabad, and Indian

Council of Medical Research) for the care and use of laboratory animals.

2.4. Acute Toxicity Studies

Acute toxicity studies for ethanolic extract of *Morinda citrifolia* (EEMC) were conducted as per OECD guidelines 423 using Wistar Albino Rats. Each animal was administered with the 2000 mg/kg b.w of aqueous solution of the extract by oral route. The animals were observed for any changes continuously for the first 2 hrs and up to 14 days for mortality. There was no mortality in EEMC treated group upto a dose of 2000 mg/kg body weight. Hence 1/10th and 1/20th of this dose i.e. 200 mg/kg and 100 mg/kg body weight was used for evaluating the nephroprotective activity. No abnormal CNS, ANS signs were noticed in the animals.

2.5. Experimental Design

The dose limits were selected on the basis of oral acute toxicity studies in mice, in accordance with the OECD guidelines. Total 30 male wistar rats were divided randomly into five groups of six animals each. Group I received oral dose of normal saline only for 14 days served as normal control. Group II received single dose of cisplatin (5 mg/kg of body weight; i.p.) on day 1 treated as control. Group III and IV received *Morinda citrifolia* fruits extract at the dose levels of 200 and 100 mg/kg b.w. once in a day for 14 days after single dose of cisplatin on day 1. Group V served as standard received cysteine (500 mg/kg; p.o.) once in a day for 14 days after single dose of cisplatin on day 1. On the 15th day, blood samples were collected by Retro orbital puncture. Blood samples were allowed to clot. Serum was separated by centrifuging at 2500 rpm (REMI micro centrifuge RM-12C) for 15 min and Serum creatinine, Serum protein, Serum Urea levels were estimated using auto analyzer (Merck AUTOLAB-200). Anti-oxidant property i.e., Lipid peroxidation was also estimated spectrophotometrically (JASCO V-530, Japan). At the end of the experiment, animals were sacrificed by cervical dislocation, kidneys were dissected and preserved in formalin until

histopathological and lipid peroxidation studies were carried out.

2.6 Estimation of Lipidperoxidation

500 mg of rat kidney was homogenized with 5ml of normal saline. The 10% homogenate was centrifuged at 4000 rpm for 10mins. The supernatant haemolysate was used for estimation of lipid peroxidation.

1 ml of supernatant was added to 2 ml of reaction mixture. The reaction solution was kept in water bath for 15minutes at 80 °C, cool it a centrifuged at 1500 rpm for 10 minutes. The resultant pink colour was measured at 535nm against a reagent blank. 1,1,3,3 tetra methoxy propane was used as external standard. The amounts of TBARS were expresses as nmoles/mL for plasma or nmoles/mg for haemolysate.

2.7 Statistical Analysis:

The Statistical analysis were carried out using one way analysis variation (ANOVA) followed by student 't' test, p values <0.05 will be considered as significant.

3. Results and Discussion:

In cisplatin treated groups of animals the serum creatinine, protein and urea levels were considerably increased ($P<0.01$) than the normal animals (group 1) which induced nephrotoxicity. Treatment group (3 & 4) with ethanolic extracts

of *Morinda citrifolia* shows a significantly reduction in serum creatinine, protein and urea levels. 200 mg/kg EEMC was the most effective in normalizing the alterations the effect was similar to standard cystone at 500 mg/kg was also found to exert favorable effect significantly. The results are presented in Table 1 and Figure 1.

Lipid peroxidation mediated tissue damage has been observed in the development of nephrotoxicity. Increased lipid peroxidation under nephrotoxicity conditions can be due to increased oxidative stress in cells as a result of depletion of antioxidant scavenger systems. There was a significant elevation of TBAR content in nephrotoxic controls when compared with normal rats ($P<0.01$). Administration of ethanolic extracts showed significant results when compared with toxicant control ($P<0.05$), the effect was similar to standard drug cystone which showed significance of ($P<0.01$). The Histopathological studies of administration of ethanolic extract of *Morinda citrifolia* reveal reduced renal injury induced by cisplatin. In histopathological slides of control rat kidney showed normal tubular epithelial cells and glomeruli, whereas cisplatin treated rats showing glomerular atrophy, infiltration of cells, tubular congestion. The treatment with EEMC at 200 mg/kg & 100 mg/kg showed regenerative changes in glomeruli and tubules, normally regaining of tubular epithelial cells, as well as in renal corpuscles/parietal epithelial.

Table 1: Effect of 5 mg/kg of cisplatin intraperitoneal and graded oral *Morinda citrifolia* on serum creatinine, serum protein and serum urea in treated rats.

Group	Serum creatinine (mg/dl)	Serum protein (mg/dl)	Serum Urea (mg/dl)	Lipid peroxidation
Normal	0.69±0.48	4.26±0.94	37.4±0.43	2.69±0.04
Toxicant- cisplatin	1.62±1.21 ^b	7.80±1.10 ^a	51.8±11.6 ^b	4.39±0.51 ^b
Ethanolic extract- 200 mg/kg	0.91±0.46*	5.90±2.63**	42.5±0.94**	3.20±0.06**
Ethanolic extract - 100mg/kg	1.45±0.44*	6.9±8.1*	41.28±2.22*	3.8±0.06*
Std-Cystone (500 mg/kg)	0.89±1.50**	5.78±3.02**	40.3±10.5**	2.9±0.06**

Data are expressed as mean ± SEM; *Values significantly different compared to normal group $P^a<0.05$; **Values high significantly different compared to normal group $P^b<0.01$, *Values significantly different compared to cisplatin group $P^*<0.05$; **Values high significantly different compared cisplatin group $P^{**}<0.01$.

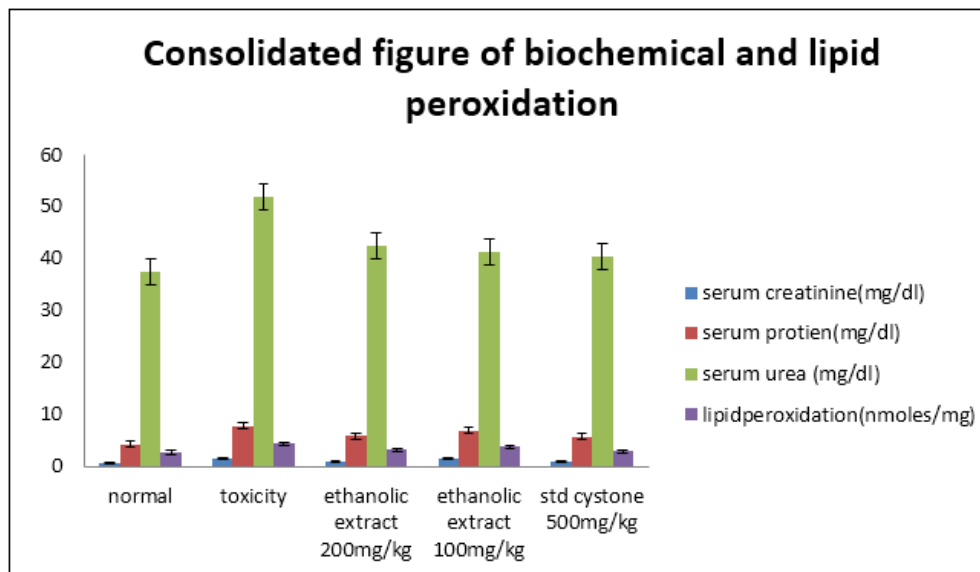


Fig 1: Effect of *Morinda citrifolia* on serum creatinine, serum protein, serum urea and lipidperoxidation

Histopathological Results:

- 1) Normal rats' kidney tubular epithelial cells and glomeruli by a section through kidney. (fig. 2)

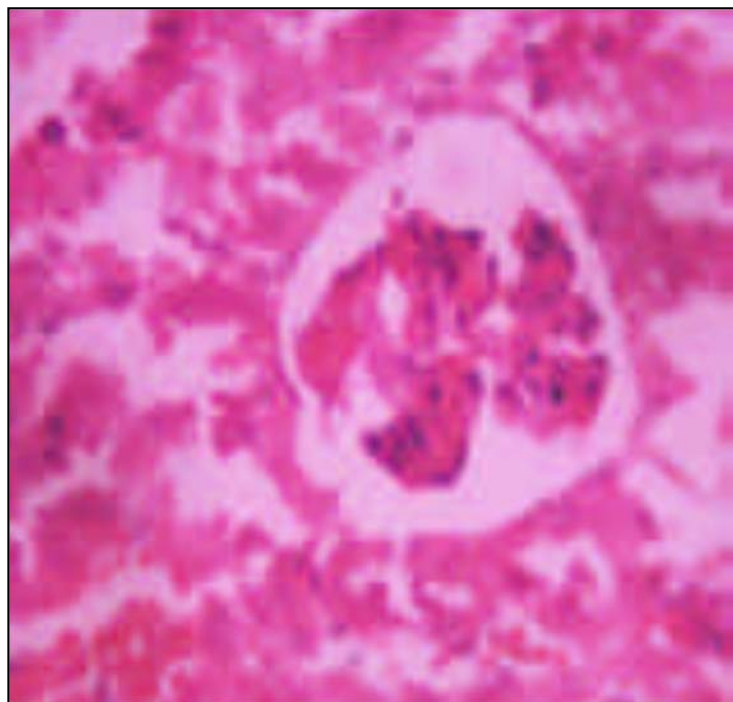


Fig 2: Normal

2) Treated with cisplatin showed glomerular atrophy, infiltration of cells, tubular congestion. (fig. 3)

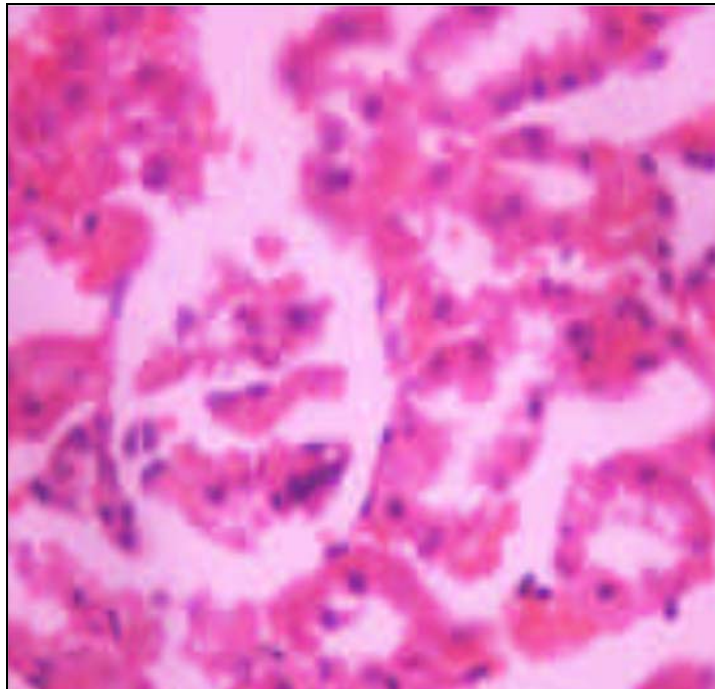


Fig 3: Toxicant Control

3) Treated with cisplatin and ethanolic extract of *Morinda citrifolia* fruits (100 mg/kg) Showed regenerative changes in glomeruli and tubules. (fig 4)

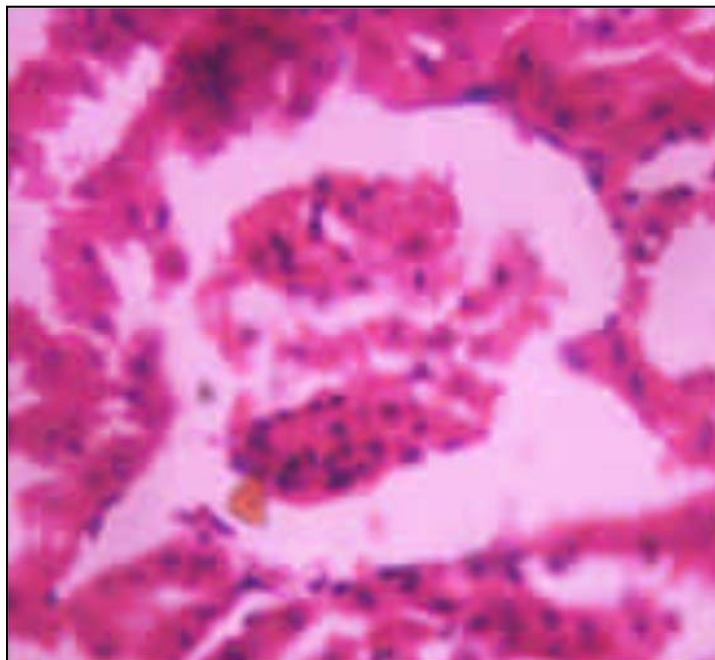


Fig 4: Test 100 mg/kg

- 4) Treated with cisplatin and ethanol extract of *Morinda citrifolia* fruits (200 mg/kg) showed regenerative changes in glomeruli and tubules. (fig. 5)

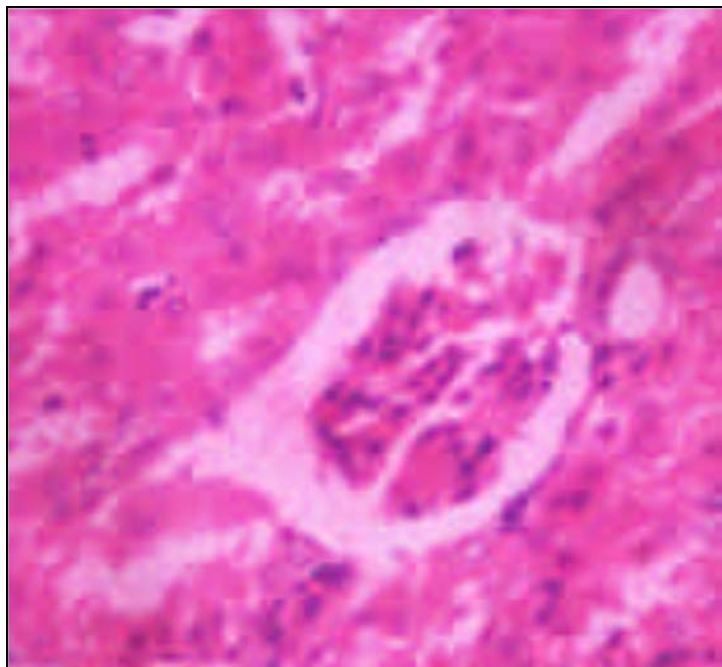


Fig 5: Test 200 mg/kg

5. Treated with cisplatin and Cystone 500 mg/kg showing renal corpuscles, parietal epithelial normality regaining by a section through kidney. (Fig. 6)

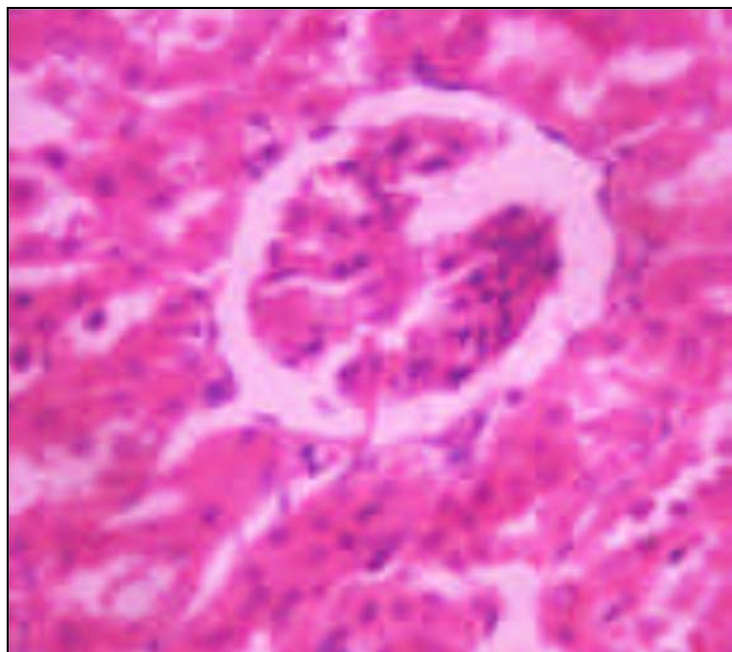


Fig 6: Std Cystone 500 mg/kg

4. Summary and Conclusion

Drug induced nephrotoxicity are often associated with marked elevation in blood urea, blood protein and blood creatinine. So these biochemical parameters have been used to investigate drug induced nephrotoxicity in animal and man. In the present study induced nephrotoxicity were established by intraperitoneal injection of cisplatin on day 1. This toxicity characterized by marked elevation in the circulating levels of blood urea, serum creatinine, serum protein and histological features of glomerular atrophy, infiltration of cells, tubular congestion in the model control (group 2) rats when compared to untreated (group 1) rats. However, these changes were attributed by treatment with single daily graded doses of *Morinda citrifolia* extract for 14 days after single dose of cisplatin on day 1 significantly decreased the urea, creatinine, protein levels in treatment group compare to toxicant group.

Lipid peroxidation mediated tissue damage has been observed in the development of nephrotoxicity. Increased lipid peroxidation under nephrotoxicity conditions can be due to increased oxidative stress in cells as a result of depletion of antioxidant scavenger systems. There was a significant elevation of TBAR content in nephrotoxic controls when compared with normal rats. Administration of ethanolic extract significantly decreased the levels of TBAR content in the kidney tissue when compared with toxicant control.

In histopathological study of saline treated group showing tubular epithelial cells and glomeruli. Cisplatin treated group showing glomerular atrophy, infiltration of cells, tubular congestion. Group III animals treated with cisplatin and EEMC (200 mg/kg) showing regenerative changes in glomeruli and tubules. Group IV animals treated with cisplatin and extract (100 mg/kg) showing regenerative changes in glomeruli and tubules. Cisplatin and Cystone 500 mg/kg showing renal corpuscles, parietal epithelial normally regaining by a section through kidney.

The findings suggested the potential use of ethanol extract of *Morinda citrifolia* as a

therapeutically useful nephroprotective agent. Therefore further studies to explain their mechanisms of actions should be conducted to aid the discovery of new therapeutic agent for the treatment of renal diseases.

5. Acknowledgement:

The authors are thankful to Management and staff of NISHKA Labs (www.nishkalabs.com) and Teegala Krishna Reddy College of Pharmacy, Hyderabad for providing the necessary facilities to carry out the present research work and for the preparation of the article.

6. References

1. Kanchan G, Pradeep D, Pushpalata C, Joshi YM, Vilasrao K. A Review on Some Nephroprotective Medicinal Plants. International Journal of Pharmaceutical Sciences and Research 2012; 3(8):2451-2454.
2. Nancy A. Antibacterial activity of dried Australian plants by rapid direct plate test. Australian Journal of Experimental Biology 1955; 34:17-26.
3. Hiramatsu T, Imoto M, Koyano T, Umezawa K. Induction of normal phenotypes in RAS transformed cells by damnacanthol from *Morinda citrifolia*. Cancer Letters 1993; 73:161-166.
4. Sridevi N, Sheela SC, Kotturarathu MC. Extraction and Preliminary Phytochemical Screening of Active compounds in *Morinda citrifolia* Fruit. Asian Journal of Pharmaceutical and Clinical Research 2012; 5:179-181.
5. Priyadarsini G *et al.* Nephroprotective activity of decoction of *Indigofera tinctoria* (avuri kudineer) against cisplatin-induced nephropathy in rats. International Journal of Life science & Pharma Research 2012:56-62.
6. Naidu MU *et al.* *Ginkgo biloba* extract ameliorates GM induced nephrotoxicity in rats. Phytomedicine Journal 2000; 7(3):191-7.
7. Shirwaikar A *et al.* Protective Effect of *P. pinnata* flowers against cisplatin & GM

- induced nephrotoxicity in rats. Indian Journal of Experimental Biology 2002; 41(1):58-62.
8. Annie S, Rajgopal PL, Malini S. Effect of *C. auriculata* root extract on cisplatin & GM induced renal injury. Phytomedicine Journal 2005; 12(8):555-60.
 9. Fawcett JK, Scott JE. A Rapid and precise method for the determination of urea. Journal of clinical pathology 1960; 13(2):156-159.
 10. Chaney AL, Marbach EP. Modified reagents for determination of urea and ammonia. Clin Chem 1962; 8:130-132.
 11. Crocker H, Shephard MD. Evaluation of an enzymatic method for determining creatinine in plasma. Journal of clinical pathology 1988; 41(5):576-581.
 12. Bowers LD, Wong ET. Kinetic serum creatinine assays. II. A critical evaluation and review. Clin Chem 1980; 26:555-561.
 13. Roscoe MH. The estimation of creatinine in serum. Journal of clinical pathology 1953; 6(3):201-207.