

THE PHARMA INNOVATION - JOURNAL

Peculiarities Of Surgical Treatment Of Recurrent Inguinal Hernia In Elderly And Senile Patients

Sergey M. Vasulyuk *¹, Olexandr V. Prudnikov ¹

1. Department of Surgery № 1, Ivano-Frankivsk National Medical University, Ivano-Frankivsk, Ukraine
[Email: Surifnmu@gmail.com]

Analysis of surgical treatment of 21 elderly and senile patients with hernias of IVA and IVB - types by Nyhus was performed. In 2 of them the relapse has occurred after preperitoneal transabdominal hernioplasty, in 14 - after various types of hernioplasty by own tissues, and in 5 - after hernioplasty by Lichtenstein. In 7 examined patients plastic of the recurrent hernia was performed by the method of Postempskyi, in 9 - by Lichtenstein and in 5 - by our original method. It was determined that hernioplasty by Postempskyi should be refused in patients with recurrent inguinal hernias. Operation by Lichtenstein is the method of choice for recurrent hernias after tense hernioplasty, and our original method must be applied in the case of recurrent hernia after plastics by Lichtenstein.

Keyword: Inguinal Hernia, Elderly Age, Hernia Repair, Recurrent Inguinal Hernia.

1. Introduction

Inguinal hernias occur in 3-4% of the adult population. Planned surgery about this disease ranks the first place. In developed countries around the world each year hundreds of thousands of surgical interventions for inguinal hernia are performed: in the USA - more than 700000, in Russia - 200000, in France - 110000, in the UK - 80000. In Ukraine, annually approximately 90000 routine inguinal hernioplastic operations are performed ^[1].

The peak of morbidity occurs in people over 50 years, the number of these patients is 60-65% of all hernias ^[2]. According to the UN (2009), the number of elderly and senile people in the world is 743 million (11% of the total population), and in 2050 it will be about 2 billion (22%) persons. In Ukraine around 38% of elderly and senile patients is expected up to 2050 ^[3].

The relapse rate according to various authors in Ukraine and CIS countries is between 10-14% in primary hernioplasty, and 30-65% in repeated operations for recurrent disease ^[4,5]. Each 8-10th

patient who was operated on uncomplicated inguinal hernia, the relapse of the disease occurs ^[6].

Especially great number of relapses in elderly and senile patients, where only in primary hernioplasty they constitute 15-20%, and in operations of recurrent inguinal hernia - 35-46% ^[7,8].

2. Materials and methods.

We have performed clinical, instrumental and laboratory examination, followed by surgical treatment, of 21 elderly and senile patients with recurrent inguinal hernias and IVA- IVB- types by Nyhus. Age of all patients ranged from 61 to 89 years. There were no women among examined patients. Among all the patients there were two after transabdominal preperitoneal hernioplasty, 14 - after various types of hernioplasty by own tissues, and 5 - after hernioplasty by Lichtenstein. Analyzing the contingent of patients, we have noted that the main type of plastic procedure, which caused the recurrence, remained plastic

operation of the front wall of the inguinal canal by own tissues.

3. Results of the study and their discussion

In 7 patients, who were performed urgent hernioplasty because of the inability to differentiate irreducible inguinal hernia from strangulated one, the autoplasty by Postempskyi was also performed. Hernioplasty by Lichtenstein, which is more pathologically grounded in the recurrent hernias in elderly and senile patients, was performed in 9 patients.

In many publications the choice of hernioplasty in recurrence hernia after performed surgery by Liechtenstein is still being discussed. As a rule, recurrent inguinal hernia in this case occurs in two anatomical areas: in place of spermatic cord (artificial internal inguinal ring) and in the place of a mesh prosthesis fixation to the inguinal ligament. In 5 patients operated by us hernial ring was the place of internal inguinal ring. Placed implant was dense, moderately elastic plate, which was covered by connective tissue, with no signs of inflammatory reaction. Removing of the old implant in such cases is impractical due to the high injury of the inguinal triangle structures.

In these patients, we performed our proposed original method of hernioplasty^[9]. The technique of this method is as follows: after the identification of the hernia sac, which went through the internal inguinal ring, mesh dissection was performed in the upper lateral

direction, to expand the hernial gate and better access to the “neck” of hernia sac and technical facilitation of the spermatic cord mobilization. The hernia sac opening with its subsequent processing by the conventional method was performed. If the hernia sac was small in size, it was invaginated into the abdominal cavity, without disclosure. Stump of hernia sac was pierced in the base, tied and moved under the mesh implant aloft, where fixed to the grid by the same threads.

The next stage of the operation was stitching of the dissected mesh implant by individual monofilament polypropylene threads with the formation of a new internal inguinal ring. Formed opening outlet the tip of the little finger.

The circular patch of diameter not less than 2 cm was cut from the mesh material. In the center of this patch with scissors the identical hole to the basic one was carved, through which the spermatic cord is outlet. Above the grid in the place of the internal inguinal ring around the spermatic cord the Ω - similar patch was set, by the cut line directed in the opposite direction to the main section of the grid. Patch was fixed by some circular stitches of insoluble material (Fig. 1). Aponeurosis of the external oblique muscle of abdomen was sewed over the spermatic cord. The wound was tightly sewed layer-by-layer.

The above method allows us to keep the old mesh implant and minimize injury while operating in short terms of surgery.

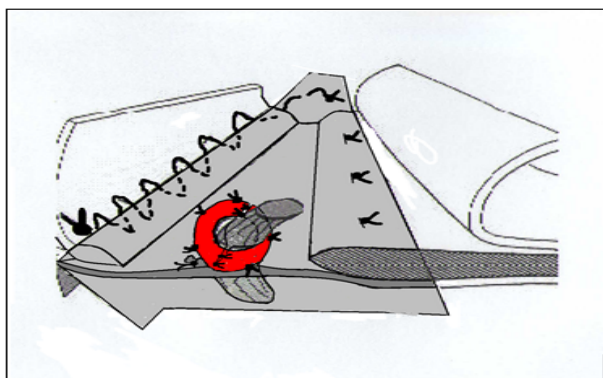


Fig 1: The Ω -shaped patch was set around the spermatic cord.

Analyzing the postoperative period, we have observed that the pain syndrome stayed longer in

patients after stretch hernioplasty. Their complete physical activity was renewed only from the

second postoperative day. Given the high prevalence of concomitant cardiopulmonary disease in patients of this age group it might cause exacerbation of chronic bronchitis, congestive pneumonitis manifestations, cardiovascular problems.

We have not seen significant difference in the postoperative period after hernioplasty by Lichtenstein and by our original method. All the patients were active in terms of 12-24 hours after surgery, requiring a single injection of pain-killer, and were discharged from the surgical department on the 3-4th postoperative day.

4. Conclusions

(i) One should refuse from the performance of the stretch hernioplasty in elderly and senile patients with hernias of IVA and IVB - types by Nyhus. Weakened and garnetted tissue of the inguinal triangle do not allow efficiently perform plastic procedure of the posterior wall of the inguinal canal. After hernioplasty by Postempskyi patients have the pain syndrome longer and the opportunity for faster physical rehabilitation disappears.

(ii) Hernioplasty by Lichtenstein may be considered the operation of choice in elderly and senile patients with hernias of IVA and IVB - types by Nyhus.

(iii) Patients with recurrent hernias after plastic procedure by Lichtenstein, in case when a relapse is caused by the failure of the internal inguinal ring in the implant, the chosen operation should be considered our proposed original method.

5. References

1. Lototskyy MI, Pavlovskyy MP. Sliding inguinal hernia. Lviv 2003; 6-11.
2. Turkina NV. Modern variants of inguinal hernioplasty in elderly and senile patients. Gerniology 2007; 3:32-34.
3. Lihonenko OV, Dihtyar II. Use of combined estrogenoliposomal therapy in complex treatment of inflammatory and suppurative lesions of the soft tissues in elderly and senile patients. Ukrainian Journal of Surgery 2009; 1:81-84.
4. Nychytaylo ME, Bulyk II. Modern aspects of endovideosurgical treatment of complicated and relapsing inguinal hernias. Clinical Surgery 2010; 3: 10-16.

5. Ghrubnik VV, Bayazitov MR, Parfentyev RS, Pashenko AV. Plastic surgery of inguinal hernias by Liechtenstein. Hospital Surgery 2004; 3:27-30.
6. Bilyanskyy LS, Manojlo NV. Modern technologies and methodology of plastic procedures of inguinal and femoral hernias. Galician drug messenger 2002; 3(9):25-27.
7. Palamarchuck VI, Hvozdyak NN, Shulyarenko OV *et al.* Surgical treatment of the relapsing inguinal hernia in elderly and senile patients. Ukraine Surgery 2011; 4:55-58.
8. Tsyhykalo OV, Tetirko IV. Plastic operation of inguinal canal in elderly and senile people. Clinical Anatomy and Operative Surgery 2002; 1(1):79-81.
9. Prudnikov O, Vasulyuk S, Fedorchenko V. Method of surgical treatment of recurrent inguinal hernia after hernioplasty by Liechtenstein, Ukraine Patent UA 66844; 2012.