

## THE PHARMA INNOVATION

# Diabetic Retinopathy- Symptoms, Causes, Risk Factors and Treatment

K. P. Sampath Kumar<sup>1\*</sup>, Debjit Bhowmik<sup>2</sup>, G.Harish<sup>3</sup>, S.Duraivel<sup>3</sup>, B. Pragathi kumar<sup>3</sup>

1. Department of Pharmaceutical Sciences, Coimbatore medical college, Coimbatore, India.

2. Karpagam University, Coimbatore, India.

3. Nimra College of Pharmacy, Vijayawada, Andhra Pradesh, India.

---

Diabetic retinopathy is a condition occurring in persons with diabetes, which causes progressive damage to the retina, the light sensitive lining at the back of the eye. It is a serious sight-threatening complication of diabetes. Diabetes is a disease that interferes with the body's ability to use and store sugar, which can cause many health problems. Too much sugar in the blood can cause damage throughout the body, including the eyes. Over time, diabetes affects the circulatory system of the retina. Diabetic retinopathy is the result of damage caused by diabetes to the small blood vessels located in the retina. Blood vessels damaged from diabetic retinopathy can cause vision loss: Fluid can leak into the macula, the area of the retina which is responsible for clear central vision. Although small, the macula is the part of the retina that allows us to see colors and fine detail. The fluid causes the macula to swell, resulting in blurred vision. In an attempt to improve blood circulation in the retina, new blood vessels may form on its surface. These fragile, abnormal blood vessels can leak blood into the back of the eye and block vision. Diabetic retinopathy is the result of damage to the tiny blood vessels that nourish the retina. They leak blood and other fluids that cause swelling of retinal tissue and clouding of vision. The condition usually affects both eyes. The longer a person has diabetes, the more likely they will develop diabetic retinopathy. If left untreated, diabetic retinopathy can cause blindness.

---

*Keyword:* Diabetic Retinopathy, Blood Vessels, Photocoagulation, Blindness.

---

**INTRODUCTION:** Diabetes is a disease that occurs when the pancreas does not secrete enough insulin or the body is unable to process it

properly. When your blood sugar gets too high, it can damage the blood vessels in your eyes. This damage may lead to diabetic retinopathy. In fact, the longer someone has diabetes, the more likely he is to have Retinopathy. Retinopathy is the medical term for damage to the tiny blood vessels (capillaries) that nourish the retina, the tissue at

---

Corresponding Author's Contact information:

K. P. Sampath Kumar\*

Department of Pharmaceutical Sciences, Coimbatore medical college, Coimbatore, India.

E-mail: [debjit\\_cr@yahoo.com](mailto:debjit_cr@yahoo.com)

---

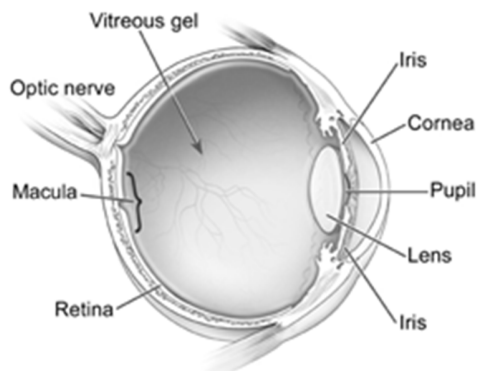
the back of your eye that captures light and relays information to your brain. These blood vessels are often affected by the high blood sugar levels associated with diabetes. Unfortunately, these delicate vessels hemorrhage easily. Blood may leak into the retina and vitreous, causing spots or floaters, along with decreased vision. Diabetic retinopathy is the most common diabetic eye disease and a leading cause of blindness in American adults. It is caused by changes in the blood vessels of the retina. In some people with diabetic retinopathy, blood vessels may swell and leak fluid. In other people, abnormal new blood vessels grow on the surface of the retina. The retina is the light-sensitive tissue at the back of the eye. A healthy retina is necessary for good vision. If you have diabetic retinopathy, at first you may not notice changes to your vision. But over time, diabetic retinopathy can get worse and cause vision loss. Diabetic retinopathy usually affects both eyes. Diabetic retinopathy, the most common diabetic eye disease, occurs when blood vessels in the retina change. Sometimes these vessels swell and leak fluid or even close off completely. In other cases, abnormal new blood vessels grow on the surface of the retina. Treatment for diabetic retinopathy depends on the stage of the disease and is directed at trying to slow or stop the progression of the disease. In the early stages of Non-proliferative Diabetic Retinopathy, treatment other than regular monitoring may not be required. Following your doctor's advice for diet and exercise and keeping blood sugar levels well-controlled can help control the progression of the disease. If the disease advances, leakage of fluid from blood vessels can lead to macular edema. Laser treatment (photocoagulation) is used to stop the leakage of blood and fluid into the retina. A laser beam of light can be used to create small burns in areas of the retina with abnormal blood vessels to try to seal the leaks. When blood vessel growth is more widespread throughout the retina, as in proliferative diabetic retinopathy, a pattern of scattered laser burns is created across the retina. This causes abnormal blood vessels to shrink and disappear. With this procedure, some side vision may be lost in order to safeguard central vision.

Some bleeding into the vitreous gel may clear up on its own. However, if significant amounts of blood leak into the vitreous fluid in the eye, it will cloud vision and can prevent laser photocoagulation from being used. A surgical procedure called a vitrectomy may be used to remove the blood-filled vitreous and replace it with a clear fluid to maintain the normal shape and health of the eye. Persons with diabetic retinopathy can suffer significant vision loss. Special low vision devices such as telescopic and microscopic lenses, hand and stand magnifiers, and video magnification systems can be prescribed to make the most of remaining vision.

## STAGES OF DIABETIC RETINOPATHY

Diabetic retinopathy has four stages:

- 1. Mild Nonproliferative Retinopathy**  
At this earliest stage, microaneurysms occur. They are small areas of balloon-like swelling in the retina's tiny blood vessels.
- 2. Moderate Nonproliferative Retinopathy**  
As the disease progresses, some blood vessels that nourish the retina are blocked.
- 3. Severe Nonproliferative Retinopathy**  
Many more blood vessels are blocked, depriving several areas of the retina with their blood supply. These areas of the retina send signals to the body to grow new blood vessels for nourishment.
- 4. Proliferative Retinopathy**  
At this advanced stage, the signals sent by the retina for nourishment trigger the growth of new blood vessels. This condition is called proliferative retinopathy. These new blood vessels are abnormal and fragile. They grow along the retina and along the surface of the clear, vitreous gel that fills the inside of the eye. By themselves, these blood vessels do not cause symptoms or vision loss. However, they have thin, fragile walls. If they leak blood, severe vision loss and even blindness can result.



Diabetic eye disease refers to a group of eye problems that people with diabetes may face as a complication of diabetes. All can cause severe vision loss or even blindness.

Diabetic eye disease may include:

- Diabetic retinopathy—damage to the blood vessels in the retina.
- Cataract—clouding of the eye's lens. Cataracts develop at an earlier age in people with diabetes.
- Glaucoma—increase in fluid pressure inside the eye that leads to optic nerve damage and loss of vision. A person with diabetes is nearly twice as likely to get glaucoma as other adults.

## CLASSIFICATION OF DIABETIC RETINOPATHY

Diabetic retinopathy is classified into two types:

1. **Non-proliferative diabetic retinopathy** (NPDR) is the early state of the disease in which symptoms will be mild or non-existent. In NPDR, the blood vessels in

the retina are weakened causing tiny bulges called microaneurysms to protrude from their walls. The microaneurysms may leak fluid into the retina, which may lead to swelling of the macula.

2. **Proliferative diabetic retinopathy** (PDR) is the more advanced form of the disease. At this stage, circulation problems cause the retina to become oxygen deprived. As a result new fragile blood vessels can begin to grow in the retina and into the vitreous, the gel-like fluid that fills the back of the eye. The new blood vessel may leak blood into the vitreous, clouding vision. Other complications of PDR include detachment of the retina due to scar tissue formation and the development of glaucoma. Glaucoma is an eye disease defined as progressive damage to the optic nerve. In cases of proliferative diabetic retinopathy, the cause of this nerve damage is due to extremely high pressure in the eye. If left untreated, proliferative diabetic retinopathy can cause severe vision loss and even blindness.

## RISK FACTORS FOR DIABETIC RETINOPATHY

Risk factors for diabetic retinopathy include:

- **Diabetes** — people with Type 1 or Type 2 diabetes are at risk for the development of diabetic retinopathy. The longer a person has diabetes, the more likely they are to develop diabetic retinopathy, particularly if the diabetes is poorly controlled.
- **Race** — Hispanic and African Americans are at greater risk for developing diabetic retinopathy.
- **Medical conditions** — persons with other medical conditions such as high blood pressure and high cholesterol are at greater risk.

- **Pregnancy** — pregnant women face a higher risk for developing diabetes and diabetic retinopathy. If gestational diabetes develops, the patient is at much higher risk of developing diabetes as they age.

## DIAGNOSIS OF DIABETIC RETINOPATHY

Diabetic retinopathy can be diagnosed through a comprehensive eye examination. Testing, with special emphasis on evaluation of the retina and macula, may include:

- **Patient history** to determine vision difficulties experienced by the patient, presence of diabetes, and other general health concerns that may be affecting vision
- **Visual acuity measurements** to determine the extent to which central vision has been affected
- **Refraction** to determine the need for changes in an eyeglass prescription
- **Evaluation of the ocular structures, including the evaluation of the retina** through a dilated pupil
- **Measurement of the pressure** within the eye

Supplemental testing may include:

- **Retinal photography** or tomography to document current status of the retina
- **Fluorescein angiography** to evaluate abnormal blood vessel growth

It's possible to have diabetic retinopathy and not know it. In fact, it's uncommon to have symptoms in the early stages of diabetic retinopathy.

## SYMPTOMS OF DIABETIC RETINOPATHY

As the condition progresses, diabetic retinopathy symptoms may include:

- Spots or dark strings floating in your vision (floaters)
- Blurred vision
- Fluctuating vision
- Dark or empty areas in your vision
- Vision loss
- Difficulty with color perception
- Diabetic retinopathy usually affects both eyes.

Diabetic retinopathy may be classified as early or advanced, depending on your signs and symptoms.

**Early diabetic retinopathy.** This type of diabetic retinopathy is called nonproliferative diabetic retinopathy (NPDR). It's called that because at this point, new blood vessels aren't growing (proliferating). NPDR can be described as mild, moderate or severe. When you have NPDR, the walls of the blood vessels in your retina weaken. Tiny bulges (called microaneurysms) protrude from the vessel walls, sometimes leaking or oozing fluid and blood into the retina. As the condition progresses, the smaller vessels may close and the larger retinal vessels may begin to dilate and become irregular in diameter. Nerve fibers in the retina may begin to swell. Sometimes the central part of the retina (macula) begins to swell, too. This is known as macular edema.

- **Advanced diabetic retinopathy.** Proliferative diabetic retinopathy (PDR) is the most severe type of diabetic retinopathy. It's called proliferative because at this stage, new blood vessels begin to grow in the retina. These new blood vessels are abnormal. They may grow or

leak into the clear, jelly-like substance that fills the center of your eye (vitreous). Eventually, scar tissue stimulated by the growth of new blood vessels may cause the retina to detach from the back of your eye. If the new blood vessels interfere with the normal flow of fluid out of the eye, pressure may build up in the eyeball, causing glaucoma. This can damage the nerve that carries images from your eye to your brain (optic nerve).

Diabetic retinopathy can happen to anyone who has diabetes. These factors can increase your risk:

- Duration of diabetes — the longer you have diabetes, the greater your risk of diabetic retinopathy
- Poor control of your blood sugar level
- High blood pressure
- High cholesterol
- Pregnancy
- Tobacco use

## COMPLICATIONS

Diabetic retinopathy involves the abnormal growth of blood vessels in the retina. Complications can lead to serious vision problems:

- **Vitreous hemorrhage.** The new blood vessels may bleed into the clear, jelly-like substance that fills the center of your eye. If the amount of bleeding is small, you might see only a few dark spots or floaters. In more-severe cases, blood can fill the vitreous cavity and completely block your vision. Vitreous hemorrhage by itself usually doesn't cause permanent vision loss. The blood often clears from the eye within a few weeks or months. Unless your retina is damaged, your vision may return to its previous clarity.
- **Retinal detachment.** The abnormal blood vessels associated with diabetic retinopathy stimulate the growth of scar tissue, which can pull the retina away from the back of the eye. This may cause

spots floating in your vision, flashes of light or severe vision loss.

**Glaucoma.** New blood vessels may grow in the front part of your eye and interfere with the normal flow of fluid out of the eye, causing pressure in the eye to build up (glaucoma). This pressure can damage the nerve that carries images from your eye to your brain (optic nerve).

**Blindness.** Eventually, diabetic retinopathy, glaucoma or both can lead to complete vision loss.

## TREATMENTS AND DRUGS

Treatment depends largely on the type of diabetic retinopathy you have. Your treatment will also be affected by how severe your retinopathy is, and how it has responded to previous treatments.

### Early diabetic retinopathy:

If you have nonproliferative diabetic retinopathy, you may not need treatment right away. However, your eye doctor will closely monitor your eyes to determine if you need treatment.

It may also be helpful to work with your diabetes doctor (endocrinologist) to find out if there are any additional steps you can take to improve your diabetes management. The good news is that when diabetic retinopathy is in the mild or moderate stage, good blood sugar control can usually slow the progression of diabetic retinopathy.

### Advanced diabetic retinopathy

If you have proliferative diabetic retinopathy, you'll need prompt surgical treatment. Sometimes surgery is also recommended for severe non-proliferative diabetic retinopathy. Depending on the specific problems with your retina, options may include:

**Focal laser treatment.** This laser treatment, also known as photocoagulation, can stop or slow the

leakage of blood and fluid in the eye. It's done in your doctor's office or eye clinic. During the procedure, leaks from abnormal blood vessels are treated with laser burns. Focal laser treatment is usually done in a single session. Your vision will be blurry for about a day after the procedure. Sometimes you will be aware of small spots in your visual field that are related to the laser treatment. These usually disappear within weeks. If you had blurred vision from swelling of the central macula before surgery, however, you may not recover completely normal vision. But, in some cases, vision does improve.

- **Scatter laser treatment.** This laser treatment, also known as panretinal photocoagulation, can shrink the abnormal blood vessels. It's also done in your doctor's office or eye clinic. During the procedure, the areas of the retina away from the macula are treated with scattered laser burns. The burns cause the abnormal new blood vessels to shrink and scar. Scatter laser treatment is usually done in two or more sessions. Your vision will be blurry for about a day after the procedure. Some loss of peripheral vision or night vision after the procedure is possible.
- **Vitrectomy.** This procedure can be used to remove blood from the middle of the eye (vitreous) as well as any scar tissue that's tugging on the retina. It's done in a surgery center or hospital using local or general anesthesia. During the procedure, the doctor makes a tiny incision in your eye. Scar tissue and blood in the eye are removed with delicate instruments and replaced with a salt solution, which helps maintain your eye's normal shape. Sometimes a gas bubble must be placed in the cavity of the eye to help reattach the retina. If a gas bubble was placed in your eye, you may need to remain in a facedown position until the gas bubble dissipates — often several days. You'll need to wear an eye patch and use medicated eyedrops for a few days or weeks. Vitrectomy may be followed or accompanied by laser treatment.

Surgery often slows or stops the progression of diabetic retinopathy, but it's not a cure. Because diabetes is a lifelong condition, future retinal

damage and vision loss are possible. Even after treatment for diabetic retinopathy, you'll need regular eye exams. At some point, additional treatment may be recommended.

Researchers are studying new treatments for diabetic retinopathy, including medications that may help prevent abnormal blood vessels from forming in the eye. Some of these medications are injected directly into the eye to treat existing swelling or abnormal blood vessels. These treatments appear promising, but they haven't been studied in long-term trials yet.

## CONCLUSION

Diabetic retinopathy is the most common diabetic eye disease and a leading cause of blindness in American adults. It is caused by changes in the blood vessels of the retina. In some people with diabetic retinopathy, blood vessels may swell and leak fluid. In other people, abnormal new blood vessels grow on the surface of the retina. The retina is the light-sensitive tissue at the back of the eye. A healthy retina is necessary for good vision. you have diabetic retinopathy, at first you may not notice changes to your vision. But over time, diabetic retinopathy can get worse and cause vision loss. Diabetic retinopathy usually affects both eyes. There is no cure for diabetic retinopathy. But laser treatment (photocoagulation) is usually very effective at preventing vision loss if it is done before the retina has been severely damaged. Surgical removal of the vitreous gel (vitrectomy) may also help improve vision if the retina has not been severely damaged. Sometimes injections of anti-VEGF (vascular endothelial growth factor) medicine help to shrink new blood vessels in proliferative diabetic retinopathy. Because symptoms may not develop until the disease becomes severe, early detection through regular screening is important. The earlier retinopathy is detected, the easier it is to treat and the more likely vision will be preserved. You may not need treatment for diabetic retinopathy unless it has affected the center (macula) of the retina or, in

rare cases, if your side (peripheral) vision has been severely damaged. But you do need to have your vision checked regularly.

## REFERENCE:

- 1) American Diabetes Association. Standards of medical care in diabetes--2011. *Diabetes Care*. 2011 Jan;34 Suppl 1:S11-61.
- 2) O'Doherty M, Dooley I, Hickey-Dwyer M. Interventions for diabetic macular oedema: a systematic review of the literature. *Br J Ophthalmol*. 2008;92:1581-1590.
- 3) Diabetic Retinopathy Clinical Research Network (DRCR.net), Beck RW, Edwards AR, Aiello LP, Bressler NM, Ferris F, Glassman AR, et al. Three-year follow-up of a randomized trial comparing focal/grid photocoagulation and intravitreal triamcinolone for diabetic macular edema. *Arch Ophthalmol*. 2009;127:245-251.
- 4) Ahuja MM. Epidemiology studies on diabetes mellitus in India. In: Ahuja MM, editor. *Epidemiology of diabetes in developing countries*, Interprint. New Delhi: 1979. p. 29-38.
- 5) Ramachandran A, Snehalatha C, Kapur A, Vijay V, Mohan V, Das AK, et al. Diabetes Epidemiology Study Group In India (DESI): High prevalence of diabetes and impaired glucose tolerance in India: National Urban Diabetes Survey. *Diabetologia* 2001;44:1094-101.
- 6) Mohan V, Deepa M, Deepa R, Shanthirani CS, Farooq S, Ganesan A, et al. Secular trends in the prevalence of diabetes and impaired glucose tolerance in urban South India-the Chennai Urban Rural Epidemiology Study (CURES-17). *Diabetologia* 2006;49:1175-8.
- 7) Mohan V, Mathur P, Deepa R, Deepa M, Shukla DK, Menon GR, et al. Urban rural differences in prevalence of self-reported diabetes in India: The WHO-ICMR Indian NCD risk factor surveillance. *Diab Res Clin Pract* 2008;80:159-68.
- 8) Chow CK, Raju PK, Raju R, Reddy KS, Cardona M, Celermajer DS, et al. The prevalence and management of diabetes in rural India. *Diabetes Care* 2006;29:1717-8.
- 9) Pradeepa R, Mohan V. The Changing Scenario of the Diabetes Epidemic: Implications for India. *Indian J Med Res* 2002;116:121-32.
- 10) Mohan V, Shanthirani CS, Deepa M, Deepa R, Unnikrishnan RI, Datta M. Mortality rates due to diabetes in a selected urban South Indian population: The Chennai Urban Population Study (CUPS). *J Assoc Physicians India* 2006;54:113-7.
- 11) Rema M, Premkumar S, Anitha B, Deepa R, Pradeepa R, Mohan V. Prevalence of diabetic retinopathy in Urban India: The Chennai Urban Rural Epidemiology Study (CURES) Eye Study - 1. *Invest Ophthal Vis Sci* 2005;46:2328-33.
- 12) Dandona L, Dandona R, Naduvilath TJ, McCarty CA, Rao GN. Population based assessment of diabetic retinopathy in an urban population in southern India. *Br J Ophthal* 1999;83:937-40.
- 13) Narendran V, John RK, Raghuram A, Ravindran RD, Nirmalan PK, Thulasiraj RD. Diabetic retinopathy among self reported diabetics in southern India: A population based assessment. *Br J Ophthalmol* 2002;86:1014-8.
- 14) Suresh S, Deepa R, Pradeepa R, Rema M, Mohan V. Large scale diabetes awareness and prevention in South India. *Diabetes Voice* 2005;50:11-4.
- 15) Rani PK, Raman R, Chandrakantan A, Pal SS, Perumal GM, Sharma T. Risk factors for diabetic retinopathy in self-reported rural population with diabetes. *J Postgrad Med* 2009;55:92-6.
- 16) Nirmalan PK, Katz J, Robin AL, Tielsch JM, Namperumalsamy P, Kim R, et al. Prevalence of vitreoretinal disorders in a rural population of southern India: The Aravind Comprehensive Eye Study. *Arch Ophthalmol* 2004;122:581-6.
- 17) Rani PK, Raman R, Sharma V, Mahuli SV, Tarigopala A, Sudhir RR, et al. Analysis of a comprehensive diabetic retinopathy screening model for rural and urban diabetics in developing countries. *Br J Ophthalmol* 2007;91:1425-9.