



ISSN: 2277- 7695

TPI 2015; 4(1): 05-10

© 2015 TPI

www.thepharmajournal.com

Received: 08-02-2015

Accepted: 02-03-2015

Bulbuk Oleksandr

Department of Prosthetic Dentistry

Ivano-Frankivsk National

Medical University, Ivano-

Frankivsk, Ukraine.

Production of immediate removable denture

Bulbuk Oleksandr

Abstract

Prosthetic dentistry defines three types: immediate, early and remote prosthesis. Immediate prosthetic is fixed directly after surgery on the operating table or dental chair. This article speaks of issues related to immediate denture for patients whose prosthesis was just fixed immediately after surgery on the operating table or dental chair.

Authors demonstrate the relevance of researched problems of immediate dentures manufacture with reproduction of removed teeth, and offers its own method of manufacturing a prosthesis directly after tooth was removed. In the article it is tried to assess the effectiveness of the proposed technique in comparison with other known methods.

Keywords: Immediate denture, prosthesis, "silicone key" plastics, patient

1. Introduction

Prosthetic dentistry defines three types: immediate, early and remote prosthesis. Immediate prosthetic is fixed directly after surgery on the operating table or dental chair.

Immediate prosthesis helps to avoid displacement of appearance, provides faster restoration of chewing function and speech, saves collar height, warning disruption of muscle and joint. Basis of immediate denture accelerates the formation of prosthetic hole adapted for future prosthesis, and serves as a dressing for the wound to protect it from exposure to various kinds of irritants, also provides faster healing. Some authors recommend to use immediate dentures as medical bandages, applying on the inner surface of the basis varied medicinal means.

There are quite a lot indications for immediate prosthesis. At the same time, immediate prosthesis should be acknowledged as a necessity by follow medical circumstances: removal of the "last" tooth; removal of the teeth along with the last couple of antagonists (loss of the fixed collar height); removal of the teeth, due to paradontosis, that is threatening functional overload and reduced collar height; removal of the side teeth with formation of bilateral or large defects with deep bite or disease of temporomandibular joint; removal of the front teeth; removal of the teeth with significant abnormal mobility in periodontal disease; collar resection of part or all of the jaw.

Among all the methods that are used in recent years, most popular are those, where it is possible to recreate exact location, size and shape of teeth that were removed. It is especially important for those patients, who due to their occupation have constant contact with other people (artists, professors, public figures etc.). Preservation of normal look of artificial teeth have positive impact on mental health of the patient and provides rapid adaptation to denture. As an example of such solution can be "Seeling technique", that helps to recreate the prosthesis crowns of removed tooth. The logic is next. After removing prints and casting plaster models, they are fixed in articulator, plaster teeth that were planned to be removed are carefully cut away to clinical neck, avoiding damage. Make clasps and wax base, cut down plaster teeth will be fixed into wax bases in their previous position, focusing on antagonists. Model will be gypsum into cell in reverse way and plaster teeth will be removed after etching wax. The resulted form for them will be filled in the appropriate plastic according to natural color of teeth.

Evaluation of this method, made by H.L.Savvidi (1980), showed that in case of the close arrangement of teeth, it is difficult to cut without damaging the plaster model. To overcome these problems the technology in immediat-prosthesis H.L. Savvidi proposed to change the way of casting gypsum plaster model and in its cell. In proposed by him way, plaster model made by alginate reflection poured in two stages. At first, only teeth planned to remove, are filled with plaster prints. After hardening plaster last smeared Vaseline and cast the rest of the model.

Following proposed procedure V.N.Rallo and N.A.Puchko (1983), the tooth that has to be

Correspondence:

Bulbuk Oleksandr

Department of Prosthetic

Dentistry, Ivano-Frankivsk

National Medical University

Ivano-Frankivsk, Ukraine.

removed in footprints are not filled with plaster but with molten wax to the level of their necks. While the introduction of metal pins with orthodontic wire diameter of 1 -1.5 mm long and 4-5 mm in such a way that they are above the level of wax 2-3 mm and were parallel to each other. Then mark, lower in cold water and cast plaster model.

2. Objective

To learn the possibility of manufacturing the prostheses playback removed teeth, and develop own advanced technique of immediate prosthesis.

3. Materials and Methods

In order to research phantom models, we tested each of the above techniques of immediate prosthesis and evaluated their manufacturing availability. We also developed and tested advanced techniques of immediate prosthesis using "silicone key". This method was applied to ten different patients. We conducted a clinical observation data of patients within 1 to 5 months.

4. Results of Research and Further Discussion

As a result of all the testing procedures in the clinic descriptions of these authors, it was found that it is hard and long to hold, we often faced technical difficulties and it was also very time consuming to use such techniques of immediate prosthesis.

We proposed to use "silicone key" for removed tooth restoration, made on a plaster model of the jaw.

5. Stages of Manufacture of Advanced Removable Intermediate Prosthesis

i. Creating a complete, working, anatomical print of the jaw, which is planned to manufacture immediate prosthesis: For this is used alginate imprinted materials, which is submitted to the imprinted perforated spoon.

ii. Getting the plaster model: The model must be cast immediately after flushing a print, since shortly after the polymerization of alginate imprinted mass may have substantial shrinkage.

iii. Mocking up boundaries of future immediate denture base: The size of the base depends on the number of teeth that are going to be preserved, the degree of atrophy of the alveolar bone or parts of severity arch palate, the degree of susceptibility of the mucosa, the presence of palatal torus and others. As fewer teeth are going to be preserved, as larger the basis is, and, conversely, as more teeth, as smaller basis. Good conditions for fixation of the prosthesis (high alveolar outgrowth or part, expressed arch palate) allow to reduce the basis of the prosthesis. With the increasing number of clasps basis may also be reduced. In an intermediate prosthetic defects of various localization amount of base is modified each

time depending on the number of teeth that remained the severity of alveolar bone or parts of palatal vault and other conditions.

iv. Creating fixing elements: There are many types of fixing clasps. One of the most popular is method of one-shouldered wire clasps, wire loop-shaped clasps, both-shoulder wire clasps, extended clasps, dental-alveolar and gingival clasps. The length and diameter of the cross section also affect the elasticity of the clasps. Long shouldered is elastic than short one. From clasps wire we create flooring containing reversible or clasps. In places they are located, clasps are linked to plaster model with melted wax.

v. Creating an oral prosthesis base according to defined scratches: Oral part of the base can be made from hot polymerization plastic, and a self-curing plastics. Let's look to each of the methods:

A. From hot polymerization plastic (pink shade):

According to the boundary of the wax base plate we create model for the wax replica of the oral plate. After completing the modeling of wax reproductions of the prosthesis spend in the cell we replace wax to plastic. After completion of the polymerization of the plastic base and cool cell we begin to withdrawal it from the cell and eliminate inequalities excess plastic from the surface of the prosthesis produce using different tools: rasp, scrapers, and scribing, abrasive materials. The edges of the plate have to be rounded, preserving their thickness and boundaries.

B. From self-curing plastic

By creating an oral plate from self-curing plastics (pink shade) firstly model has to be isolated using varnish. Plastic paste has to be prepared in porcelain or glass vessel, putting in a certain number of monomers and adding it to the saturation of the polymer. Mixing powder and liquid with glass or bone spatula, we should cover the jar with lid to prevent evaporation of monomer and kept the plastic to its full maturity. After we take the necessary amount of plastic paste is placed upon the model and model the oral plate according to its borders. After polymerization, we eliminate inequalities excess plastic from the surface of the prosthesis through a variety of tools: rasp, scrapers, scribing, abrasive materials. The edges of the plate have to be rounded, preserving their thickness and boundaries. (Fig. 2).

vi. Fitting oral plates in the mouth: This clinical stage makes it possible to eliminate the sometimes quite complicated process of fitting the finished prosthesis immediately after surgery, at this time the patient is least prepared for this. In the mouth we try to fit oral plate carefully, check fixing elements. If the plate is made of hot polymerization plastic, they receive alginate mark with her to get a working model.

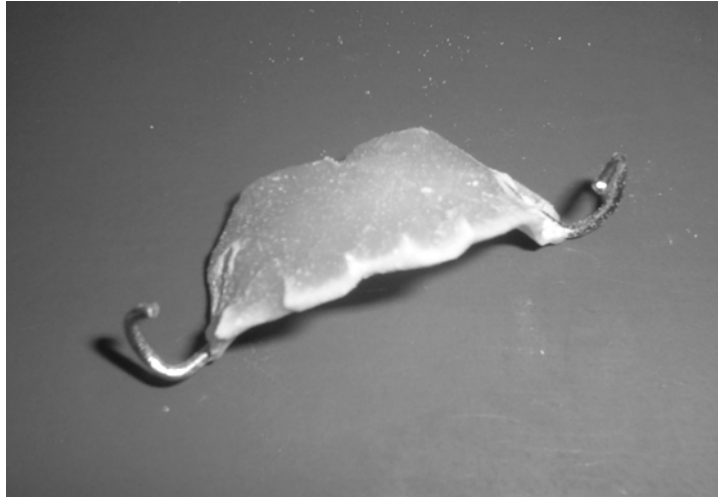

Fig 1: Finished oral plate

vii. Making of "silicone key": On the basis of oral teeth in the area of teeth to be removed, creating a retention points

(Fig. 2) for better connectivity of Oral plate with artificial teeth.

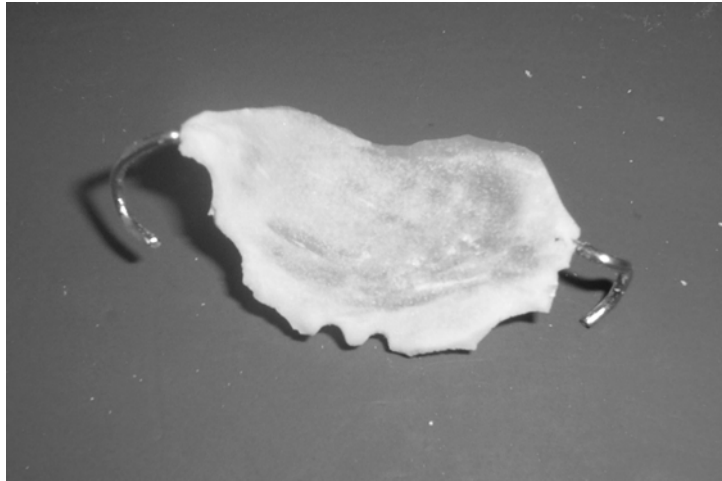


Fig 2: Retention points

Put oral part of the basis on the model. Take a standard imprint spoon, knead the basic paste of silicone imprint materials and

take the print from the plaster model with oral part of the base (making "silicone key") (Fig. 3).

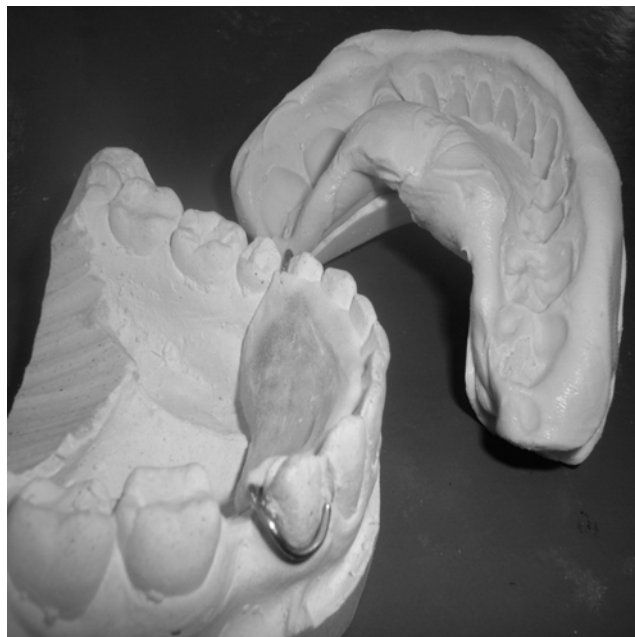


Fig 3: Finished "silicone key"

viii. Phantom removal of teeth

Teeth, that were planned to remove, are cut on the model to level of its necks. After, from the top of cell appendage or part of it the layer of gypsum has to be removed (not more than 2 mm) and it customized to the shape of oval. At the areas, close to the necks of remained teeth, for the side of defect, on the distance 3-4- mm of it, - gypsum should not be removed for to prevent excessive compression of ash in the Place of the future prosthesis. It is also not recommend to remove too much of gypsum from the side of tongue and

palate, where dense, small pliable mucosa is located, in which Slowly passes retraction after surgery.

A layer of plaster is removed, may be increased if removal of teeth is performed on periodontal disease with significant atrophy of the cells (more than 2/3 of its length). In preparing the alveolar bone in the area or part of the lateral teeth removed her from the top layer of plaster is not more than 1 mm and give it a trapezoidal shape. (Fig. 4)

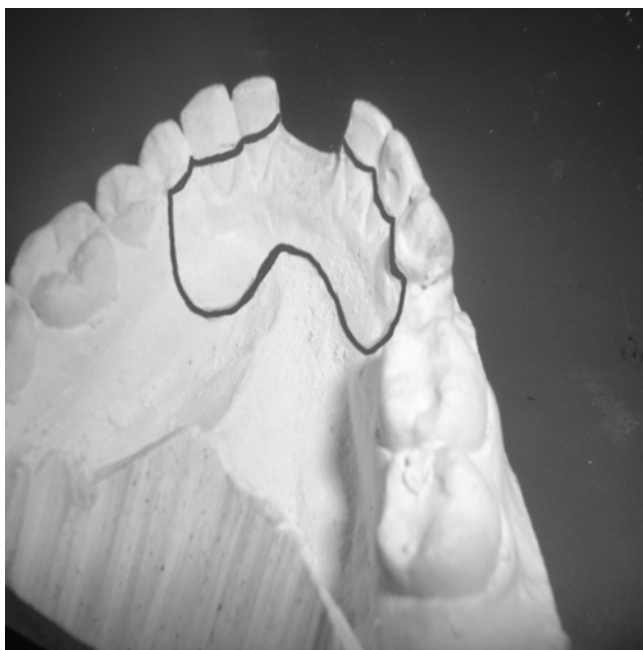


Fig 4: The phantom removal of teeth on the model and the formation of alveolar bone

ix. Production of artificial plastic teeth: According to the color of natural teeth, we select and knead self-curing plastic (white shade). Using varnish isolate model and plaster teeth. In

pasty stage making a mark on the plastic at the places where the teeth are removed, put 'silicone key 'on the plaster model and press (Fig. 5).



Fig 5: Production of artificial plastic teeth

After 20 minutes, remove the "Silicone key" of the model. After polymerization, plastic carry eliminate inequalities excess plastic from the surface of the prosthesis using variety

of tools: rasp, scrapers, scribing tools, abrasive materials (Fig. 6).

x. Production of vestibular basis: the absence of vestibular prosthesis in this area, as noted by many authors can be a serious drawback - the sharp edges of artificial teeth can

interfere with the healing of the wound. Creating even a small piece of gum in the manufacture of dentures eliminates this drawback.

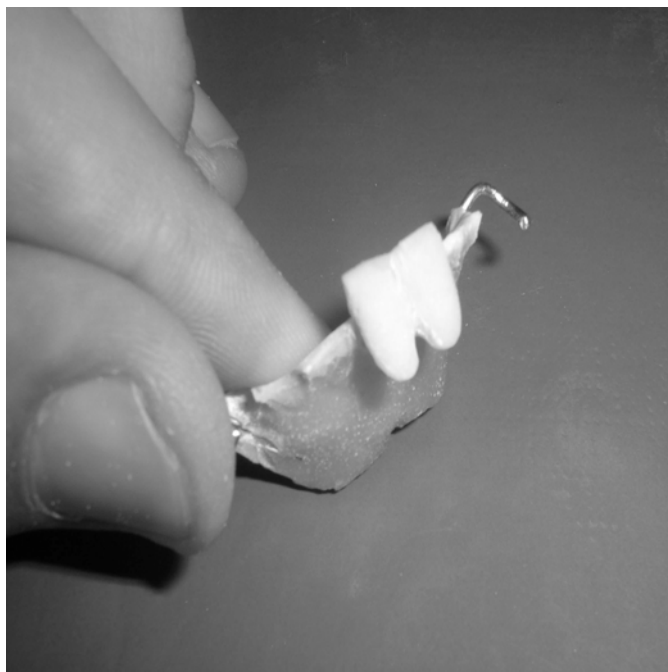


Fig 6: The immediate denture after making artificial teeth.

Vestibular basis of the immediate denture is made of self-curing plastics for bases (pink shade). This chemical bond connects the material with plastic from which artificial teeth are made of.

xi. Grinding and polishing immediate denture: Sanding and polishing immediate denture hold by the conventional method (Fig. 7).

xii. Imposition and direct fixation of removable denture: Denture imposed immediately after tooth extraction.

There is a patent applicataion on this technique of immediate denture under № u 2008 00963 at Ukrpatent named "Method of making immediate denture."

According to this method, we have done ten immediate dentures. We conducted a clinical follow-up data of patients for 1, 3 and 5 months after prosthesis. Marked decrease number of occlusal correction and aesthetical satisfaction of patients.

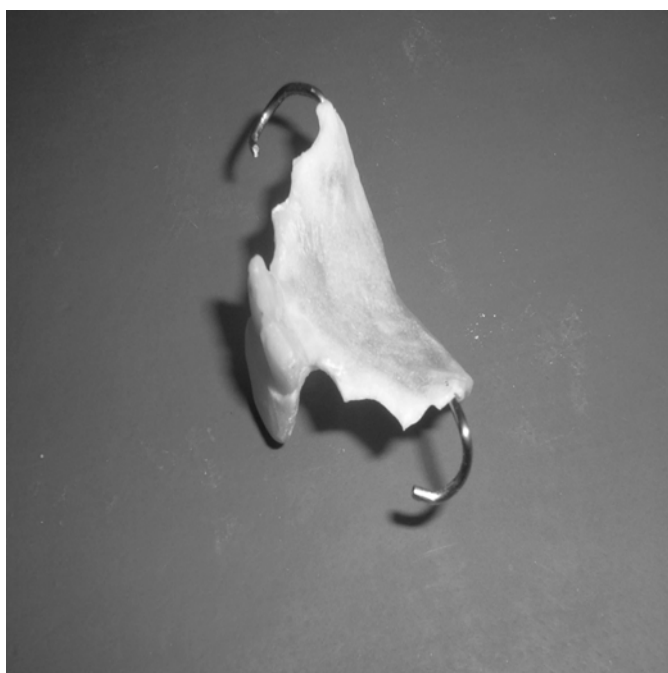

Fig 7: Completed removable immediate denture.

6. Conclusions

Proposed above method allows to have better restoration of location, size and shape of removed tooth. Technically improved methodology of immediate prosthesis this is more accurate, more precise in way to recreate size and shape of natural tooth, and also is less time consuming. Preservation of natural look of the artificial teeth has a positive impact of the patient and provides better healing and adaptation to its denture. Not least the fact, that as faster goes occlusal adaptation, as less number of correction are needed.

There is high potential in further implementation and clinical research of the method of improved immediate prosthesis.

7. References

1. Hiruma M, Kamoi K, Honda S. Healing process of experimental trauma from occlusion in rats // Nippon Dent Univ. Ann. Publ 1988; 22:83.
2. Kleber BM. Zur Häufigkeit und Pathogenese der lokalen periodontalen Recessionen // Stomatol. DDR 1990; 40:270-72.
3. Lindhe J. Klinische Parodontologie. Stuttgart; N.Y.G. Thime, 1986, 188-201.
4. Motsch A. Epidemiologic funktioneller Störungen // Dtsch. Zahnarztl. Z. 1985; 40(1):147-155.
5. Newman M. Genetic, environmental, and behavioral influences on periodontal infections. Special Issue Compendium. Periodontal aspects of systemic health. 2000; 19(1):25-31.
6. Novak MJ, Novak KF. Early onset periodontitis // Curr Opin Periodontol. 1996; 3:45-58.
7. Schädibaner E. Kritische Beurteilung der Afformmethodik mit Alginat // Osterr. Z. Stomatol. 1981; 78(9):33
8. Zuhrt R, Kleber M. Periodontologie. Leipzig: J.A. Bart, 1988, 144-157.
9. Жулев ЕН. Клиника, диагностика и ортопедическое лечение заболеваний пародонта. Нижний Новгород: Изд-во НГМА, 2003.