

## THE PHARMA INNOVATION - JOURNAL

### Evaluation of hepatoprotective activity of *Ziziphus nummularia* fruits on carbon tetrachloride induced hepatotoxicity in rats

G.Deepika Sri Prashanthi\*<sup>1</sup>, K.Upendar<sup>2</sup>, N.Siva Subramanian<sup>3</sup>, Pradeep H.A<sup>4</sup>, P.Renuka Tejasvi<sup>5</sup>, K.Seshachary Anusha<sup>6</sup>

1. Department of Pharmacology, Teegala Krishna Reddy College of Pharmacy, Medbowli, Meerpet, Saroornagar, Hyderabad, Andhra Pradesh, India- 500097. [Email: [gundrathi.deepika@gmail.com](mailto:gundrathi.deepika@gmail.com), Tel: +91-9703972738]
2. Assistant Professor, Department of pharmacology, Teegala Krishna Reddy College of Pharmacy, Medbowli, Meerpet, Saroornagar, Hyderabad, Andhra Pradesh, India. [Email: [upendarkandaraboina@gmail.com](mailto:upendarkandaraboina@gmail.com), Tel: +91-8885421051]
3. Principal, Senior Professor, Department of Chemistry, Teegala Krishna Reddy College of Pharmacy, Medbowli, Meerpet, Saroornagar, Hyderabad, Andhra Pradesh, India. [Email: [thambisiva@yahoo.com](mailto:thambisiva@yahoo.com)]
4. Department of Pharmacology, NISHKA Labs, Uppal, Hyderabad, A.P, India
5. Department of Pharmacology, Teegala Krishna Reddy College of Pharmacy, Medbowli, Meerpet, Saroornagar, Hyderabad, Andhra Pradesh, India. [Email: [teju.pusa@gmail.com](mailto:teju.pusa@gmail.com)]
6. Department of Pharmacology, Teegala Krishna Reddy College of Pharmacy, Medbowli, Meerpet, Saroornagar, Hyderabad, Andhra Pradesh, India. [Email: [karamchetianusha@gmail.com](mailto:karamchetianusha@gmail.com)]

During past several years, there has been growing interest among the usage of various medicinal plants from traditional system of ailments. The objective of this study was to evaluate the hepatoprotective activity from methanol extract derived from the *Ziziphus nummularia* Fruits. Oral administration of the extract (100 and 200 mg/kg body weight) lead to a significant reduction in ALAT, ASAT and ALP levels in CCl<sub>4</sub> induced hepatotoxicity in rats. Phytochemical screening also revealed that the extract contains Alkaloids, Phenolic compounds, Flavonoides and Tannins. The presence of poly phenols and flavonoids support its antioxidant potential. The drug, thus, is rich source of various antioxidant chemicals producing favorable action in protecting against various free radicals and show hepatoprotective activity.

**Keyword:** *Ziziphus nummularia*, Hepatoprotective Activity, Carbon tetrachloride, Liv-52

#### 1. Introduction

Liver is one of the largest organ in human body and the chief site for intense metabolism and excretion. The major functions of the liver are carbohydrate, protein and fat metabolism, detoxification, secretion of bile and storage of vitamin environmental toxins and abused by poor drug habits and in. Thus, to maintain a healthy

liver is a crucial factor for overall health and wellbeing. But it is continuously and variedly exposed to alcohol and prescribed and over-the-counter drug which can eventually lead to various liver ailments like hepatitis, cirrhosis and alcoholic liver disease. Thus liver diseases are some of the fatal disease in the world today. They pose a serious challenge to international

public health. Modern medicines have little to offer for alleviation of hepatic diseases and it is chiefly the plant based preparations which are employed for their treatment of liver disorders. But there are not much drug available for the treatment of liver disorders. Therefore, many folk remedies from plant origin are tested for its potential antioxidant and hepatoprotective liver damage in experimental animal model. Carbon tetrachloride (CCl<sub>4</sub>) induced hepatotoxicity model is widely used for the study of hepatoprotective effects of drugs and plant extracts. *Ziziphus nummularia* is a bushy, much branched shrub, with zigzag branches. Spines are in unequal pairs, bigger straight about 1 cm long, smaller one are recurved. Leaves are tiny, 1-2 cm by 0.5-2 cm, circular or ovate-circular to elliptic, dark green and densely velvety, with margins entire or toothed. Leaf stalks are 2-3 mm long. Flowers are very tiny, 3-4 mm in diameter, creamish in color. Sepals are velvety, about 1.5 mm, ovate lanceolate. Petals are wedge-shaped longer than stamens about 1.25 mm long. Stamen are about 1 mm long. Fruit is round, 0.5-1 cm across, reddish brown-black when ripe, 2 celled, 2 seeded. Fruits are edible, although not very popular due to small size. Flowering: March-June. The plant is widely used in Chinese System of Medicine. Very less pharmacological reports are available on this plant. Earlier studies on *Z. nummularia* in experimental animals have shown pharmacological activities such as antioxidant, Anti cancer, Anthelmintic and antimicrobial activity.

## 2. Materials and Methods

### 2.1 Plant Materials and Preparation of Extracts:

Fruits are washed under running tap water, air dried and then grinded coarsely and stored in air tight poly bags. Coarsely powdered fruits were packed in a soxhlet apparatus and extracted using 70% methanol as solvent. After extraction solvent was filtered and concentrated under reduced temperature and pressure.

### 2.2 Animals:

Swiss albino rats weighing between 80 and 90gm were used in this evaluation. These rats aged between 2 and 2.5 months were procured from nishka labs. They were housed in well ventilated stainless-steel cages at room temperature (24±2 °C) in hygienic condition under natural light and dark schedule and were fed on standard laboratory diet. Food and water were given *ad libitum*.

### 2.3 Experimental Design for Hepatoprotective Activity

30 male albino Wistar rats, weighing about 180-220 g will be divided into 5 groups of six animals each. Group I serve as solvent control, receive 1% CMC, orally 2ml/kg. Group II serve as toxicant control and receive CCl<sub>4</sub>, orally 2 ml/kg. Group III serve as positive control and receive Liv-52, 2ml/kg. Group IV and V receive the fruit extract suspended in 1% CMC at two different dose levels. The animals will be treated for 7 days and on the 7th day after one hour of dosing, the toxicant CCl<sub>4</sub> (50 µl/kg i.p.) will be administered to all the groups except Group I. After 24 hours the animals will be anaesthetized and blood collected by sino-orbital puncture for the assessment of the activity. The blood will be centrifuged at 2,000 rpm for 10 minutes. The serum separated and will be used for various biochemical estimations like ASAT (Aspartate Aminotransferase), ALAT (Alanine Aminotransferase) and ALP (Alkaline Phosphates) using enzymatic kits procured from E-Merck using auto analyzer. The animals will be sacrificed later and the liver perfused, excised and stored in 10 % formalin saline for histopathological studies.

### 3. Results:

Single administration of CCl<sub>4</sub> (50µl/kg; i.p) to vehicle control rats showed significant increase in Alanine Transaminase (ALAT) (222.8±10.14;  $P<0.001$ ), Aspartate amino transferase (ASAT) (193.7±12.27;  $P<0.001$ ) and Alkaline phosphatase(ALP) (328.5 ± 25.36; $P<0.01$ ) levels when compared to normal control rats (54±2.7, 88.17±5.47 and 293.2±10.41 respectively). Extract of *Ziziphus nummularia* at 200 mg/kg

showed significant reduction in ALAT (82.33±9.32;  $P<0.001$ ), ASAT (112±9.85;  $P<0.001$ ) and ALP (274.2 ± 15.54;  $P< 0.01$ ) levels when compared to CCl<sub>4</sub> administered rats. Extract of *Ziziphus nummularia* 100mg/kg also showed significant reduction in ALAT (133.5 ± 9.21; $P<0.001$ ), ASAT (175.3±9.54;  $P<0.001$ ) and ALP (278.7±19.23;  $P<0.01$ ) levels when compared toxicant control. Liv-52 showed significant reduction in ALAT (143.5±10.12;  $P<0.001$ ), ASAT (139.5±10.31;  $P<0.05$ ) and ALP (311.8±20.63;  $P<0.05$ ) levels when compared to CCl<sub>4</sub> administered rats. The results are given in table 1.

In the results obtained by histopathological studies showed that the liver of Carbon

tetrachloride treated rats showed damaged liver cells and ballooning change of the hepatocytes. The livers of the rat treated with extract 200 mg/kg and 100 mg/kg body weight showed a normal lobular pattern with minimal pooling of blood in the sinusoidal spaces. The livers if the rat treated with extract 300 mg/kg and 100 mg/kg b.w showed a normal lobular pattern with minimal pooling of blood in the sinusoidal spaces. The liver of the rat treated with Liv 52 showed mild feathery change, few ballooning degeneration of hepatocytes with normal hepatocytes. The histopathological slides are shown in the figure 1, 2, 3, 4 and 5.

**Table 1: Effect of *Ziziphus nummularia* on plasma biochemical parameters in CCl<sub>4</sub> toxicated rats.**

Treatment (n=6)	Dose	ASAT (U/l)	ALAT (U/l)	ALP(U/l)
Normal	-	88.17 ± 5.47	54 ± 2.7	293.2 ± 10.41
CCl <sub>4</sub>	50µl/kg	193.7 ± 12.27 <sup>a a a</sup>	222.8 ± 10.14 <sup>a a a</sup>	328.5± 25.36 <sup>a a</sup>
Liv52	2ml/kg	139.5± 10.31 <sup>b</sup>	143.5 ± 10.12 <sup>bbb</sup>	301.8 ±20.63 <sup>b</sup>
EZN	100mg/kg	175.3 ± 9.54 <sup>bbb</sup>	133.5± 9.21 <sup>bbb</sup>	278.7 ± 19.23 <sup>bb</sup>
EZN	200mg/kg	112 ± 9.85 <sup>bbb</sup>	82.33± 9.32 <sup>bbb</sup>	274.2± 15.54 <sup>b b</sup>

Values are expressed as mean ± S.E.M of n=6)

n=number of animals

a  $P < 0.05$ , a a  $P < 0.01$ , a a a  $P < 0.001$  Vs Normal

b  $P < 0.05$ , b b  $P < 0.01$ , b b b  $P < 0.001$  Vs Carbon tetrachloride

### 3.1 Histopathological results:

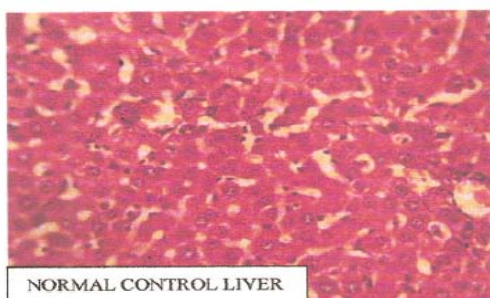


Plate No. 11

**Figure 1 Histopathology Of Normal Control Liver**

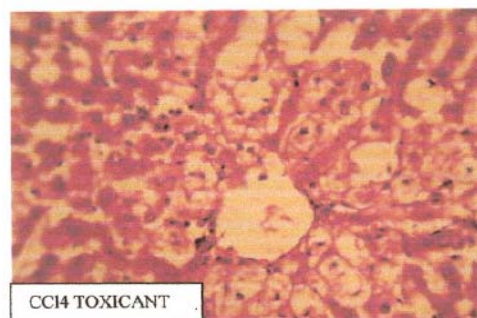


Plate No. 12

**Figure 2 Histopathology of CCl<sub>4</sub> toxicated liver**

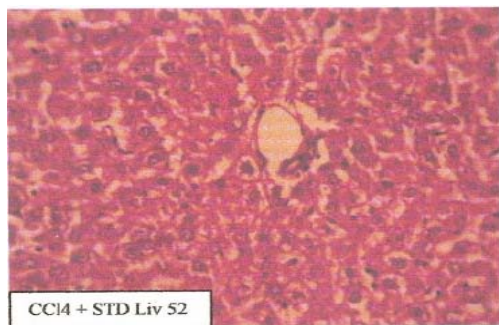


Plate No. 13

**Figure 3: Histopathology of Standard Liv-52 Treated Liver**

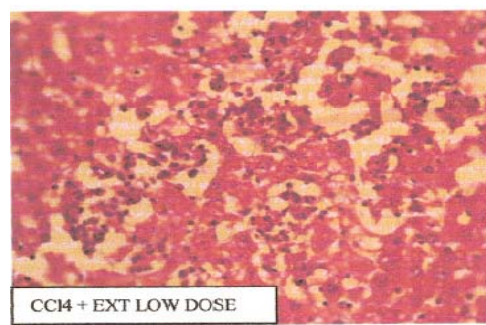


Plate No. 14

**Figure 4: Histopathology of low dose of Extract**

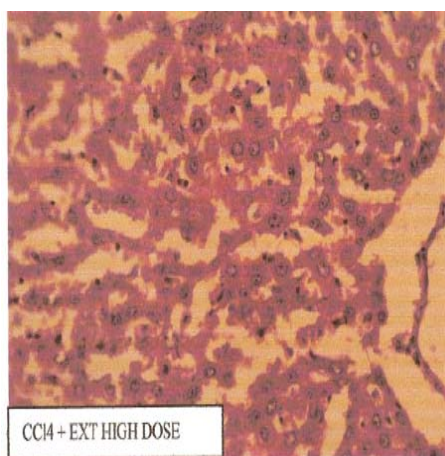


Plate No. 15

**Figure 5: Histopathology Of high dose of Extract**

#### 4. Discussion:

The qualitative phytochemical screening of methanolic extract of *Ziziphus nummularia* fruit showed the presence of alkaloids, flavonoids, tannins, phenols etc. The oral acute toxicity studies has shown that the extract of *Ziziphus nummularia* fruit is safe upto a dose of 2000 mg/kg. 1/10<sup>th</sup> and 1/20<sup>th</sup> of this dose i.e 100 mg/kg and 200 mg/kg are administered orally. Carbon tetrachloride at a dose of 50 $\mu$ l/kg showed significant elevation of all the enzyme levels suggesting potential hepatic damage. The biotransformation of CCl<sub>4</sub> occurs in the endoplasmic reticulum and is mediated by CYP450. The reactive metabolite CCl<sub>3</sub> formed reacts with molecular oxygen to yield a highly reactive trichloro methyl peroxy radical (CCl<sub>3</sub>), which is ultimate initiator of lipid peroxidation.

Biochemical parameters like Alkaline phosphatase (ALP), Alanine transaminase (ALT), Aspartate Amino Transferase (ASAT) are taken under consideration for evaluating the hepatoprotective activity. In CCl<sub>4</sub> induced hepatotoxicity Extract of *Ziziphus nummularia* at 100 mg/kg and 200 mg/kg showed significant reduction in ALAT, ASAT and ALP levels. The histopathological studies also revealed the normal lobular pattern and minimal pooling of blood in sinusoidal spaces of the liver treated with the methanolic extract of *Ziziphus nummularia* fruit. Thus it could be suggested that Extract of *Ziziphus nummularia* has hepatoprotective activity in this model which was supported by the histopathological results. The reactive species mediated hepatotoxicity can be effectively managed upon administration of agents



possessing antioxidant, free radical scavenger activity. The plant has been evaluated scientifically for its antioxidant activity. The presence of poly phenols and flavonoids support its antioxidant potential. The drug, thus, is rich source of various antioxidant chemicals producing favorable action in protecting against various free radicals and show hepatoprotective activity. "Extract of *Ziziphus nummularia* being a potent antioxidant, free radical scavenger might have contributed favorably towards the observed hepatoprotection".

### 5. Conclusion:

Liver diseases and disorders are quite common in India due to various factors like environment, pollution, smoking, drinking and most importantly contaminated water. The traditional treatment, on the other hand is quite successful in treating common ailments of liver. Taking this as lead, a number of herbal formulations particularly polyherbal, have come into market and sold successfully. The hepatoprotective effect of methanol extract of *Ziziphus nummularia fruit* was confirmed by the following Biochemical parameters and Histopathological studies.

In case of toxicant treated groups there will be rise in serum marker enzymes such as ASAT, ALT, and ALP. The same is observed in liver diseases in clinical practice and hence are having diagnostic importance in the assessment of liver function. In the present study, treatment with *Ziziphus nummularia* - extract significantly reduced the toxicant elevated levels of above mentioned serum marker enzymes. Hence, at this point it is concluded that the hydro alcoholic extract of *Ziziphus nummularia fruit* possess hepatoprotective activity. In toxicant treated animals there will be severe histopathological disturbances in the cytoarchitecture of the liver. The same is observed in case of humans who are suffering from major liver disorders. In the present study, animals treated with *Ziziphus nummularia* extract exhibited minimal hepatic derangements, minimal pooling of blood in

sinusoidal spaces with normal lobular patterns and intact cytoarchitecture of the liver was maintained, indicating hepatoprotection. Based on biochemical parameters and histopathological studies, it is concluded that the hydro alcoholic extract of *Ziziphus nummularia fruit* possess hepatoprotective activity and thus supports the traditional application of the same under the light of modern science. Crude extract from fruits of *Ziziphus nummularia* exhibited good hepatoprotective activity at low concentration. The experiment undertaken proves that hydro alcoholic extract of *Ziziphus nummularia* has hepatoprotective activity at lower doses and compares well with that of Liv-52 a known hepatoprotective drug.

### 6. Acknowledgement

The Authors would like to acknowledge the management and staff of Teegala Krishna Reddy college of Pharmacy, Meerpet, Hyderabad and Nishika laboratories, Uppal for their immense support during the research work.

### 7. References:

1. Ahsa R. Hepatoprotective Activity of Methanol Extract of Some Medicinal Plants Against Carbon Tetrachloride Induced Hepatotoxicity in Albino Rats, Global Journal of Pharmacology 2009; 116-122.
2. Singh AK, Raghubanshi AS, Singh JS. Medical ethnobotany of the tribes of Sonaghati of Sonbhadra district, Uttar Pradesh, India. Jour of Ethnopharmacology 2002; 18(1): 31-41.
3. Chanda S, Dave R and Kaneria M. *In vitro* antioxidant property of some Indian medicinal Plants. Research Jour of Medicinal Plant 2011; 5(2): 169-179.
4. Kumar A, Sharma S, Kaushik. Anti tumour activity of Lapachol isolated from *Ziziphus nummularia* as adjuvant for radiation therapy. (www.itmrc.org/publication)